

Early infantile form of galactosialidosis in a female baby with a prenatal diagnosis of fetal ascites - First case in Brazil

Cláudia Maria Carvalho dos Santos¹, Patrícia Santana Correia¹, Antônio Abílio Santa Rosa¹, Elide Vanazzi¹, Janice Carneiro Coelho³, Maira Graeff Burin³, Roberto Giugliani³, Anthony H. Fensom⁴, Cesário Paulo Honório de Oliveira², Maria Lúcia Costa de Oliveira² and Juan Clinton Llerena Jr.¹

¹ Centro de Genética Médica, Instituto Fernandes Figueira, Fundação Oswaldo Cruz, Rio de Janeiro, RJ, Brasil;

² Departamento de Bioquímica, Instituto de Química, Universidade Federal do Rio de Janeiro, Cidade Universitária, Ilha do Fundão, Centro de Tecnologia, Bloco A, 21941-900 Rio de Janeiro, RJ, Brasil. Send correspondence to M.L.C.O. Fax: +55-21-290-4746. E-mail: maucha@iq.ufrj.br

³ Serviço de Genética Médica, Hospital das Clínicas de Porto Alegre, Universidade Federal do Rio Grande do Sul, Porto Alegre, Rio Grande do Sul, RS, Brasil.

⁴ Paediatric Research Unit, Guy's Hospital, London, UK.

ABSTRACT

We present the first case of an early infantile form of galactosialidosis among Brazilians. This very rare and severe lysosomal storage disease has only a dozen patients clearly diagnosed worldwide. Clinical, pathological and biochemical features were consistent with previously published findings. We detected the disorder in a 7-month-old female baby with prenatal diagnosis of ascites. Evolution of the storage disease was monitored through routine thin-layer chromatography (TLC) for urinary oligosaccharides as part of a screening program for inborn errors of metabolism (IEM) in high-risk children, carried out in Rio de Janeiro.

INTRODUCTION

Galactosialidosis (McKusick 25654) is a lysosomal storage disease (LSD) associated with a combined deficiency of α -N-acetyl-neuraminidase (E.C. 3.2.1.18) and β -galactosidase (E.C. 3.2.0.1.23), secondary to a genetic defect of a "protective protein". This 32-kDa lysosomal protein seems to be necessary for neuraminidase activity and protects β -galactosidase from excessive proteolytic degradation; both enzymes are closely associated in a complex (D'Azzo *et al.*, 1982; Galjaard *et al.*, 1987). The disorder is transmitted as an autosomal recessive trait. The gene encoding the protective protein has been localized on chromosome 20q13.1. (McKusick, 1994).

Three phenotypes have been recognized, based on age of onset and clinical course (early infantile, late infantile and juvenile-adult types). The majority of reported patients belong to the juvenile-adult group and are mainly of Japanese origin.

The early infantile form has been clearly diagnosed in only 12 patients. Recent studies identified three different mutation points in the "protective protein" gene of three patients: leu208pro, gly411ser and val104met. All mutations prevented protein phosphorylation (Zhou *et al.*, 1996).

Clinical and pathological manifestations had an early onset (0-90 days of life), and no infant survived more than 20 months (average age of death: 8 months). Clinical findings include neonatal fetal hydrops and edema, coarse facies, inguinal hernias, visceromegaly, psychomotor delay and skeletal changes. Telangiectasias seemed to be very characteristic, since they have been rarely reported in the two other forms of the disease. Ocular abnormalities, such as corneal clouding or macular cherry-red spots, and kidney involvement (proteinuria) were reported in 50% of the patients. Parental consanguinity was frequently present (D'Azzo *et al.*, 1995).

Pathological studies of different tissues have been reported only for a few patients, especially in the juvenile-adult form, but membrane-bound vacuoles were observed in a variety of cell types, like hepatocytes and Kupffer cells in the liver, glomerular and tubular epithelial cells in the kidney, spinal cord neurons, lymphocytes, and cultured skin fibroblasts (Suzuki *et al.*, 1977; Yamano *et al.*, 1985).

Diagnosis is based on clinical signs together with the observation of an abnormal sialyloligosacchariduria; however, it should be confirmed by the demonstration of reduced α -N-acetyl-neuraminidase and β -galactosidase activities in white blood cells or preferably in cultured skin fibroblasts.

In this study we present a typical case of early infantile galactosialidosis in a female infant (T.R.F.). Clinical and pathological findings indicated a lysosomal storage disorder. Diagnosis was suggested by thin-layer chromatography for urinary oligosaccharides and confirmed by enzyme activity determinations. To the best of our knowledge, this is the first reported case of early infantile form identified among Brazilians.

CASE REPORT

T.R.F., a female infant, was the first child of a consanguineous couple (first cousins) of Caucasian origin, who had a prenatal ultrasound diagnosis of fetal ascites (third trimester). At birth, she presented fetal hydrops, with no significant dysmorphic feature (weight: 2670 g, Apgar scores: 4/8, placental weight: 900 g). Examination of fetal placental tissue and peripheral blood lymphocytes suggested a storage disease, owing to the presence of cytoplasmatic vacuoles. The newborn developed severe psychomotor delay, showed failure to thrive and had recurrent respiratory infections.

The last physical evaluation, at 5 months of age, revealed that she had developed coarse facies, hepatomegaly, macrocephaly and skeletal changes (X-ray studies demonstrated demineralization of long bones). Her skin was pale, showing numerous telangiectasias. She was malnourished, anemic and maintained thrombocytopenia. Ocular abnormalities, such as corneal opacities or macular cherry-red spots, could not be investigated because of a chronic conjunctival infection. At the age of 7 months, she died as a consequence of pneumonia and sepsis. Necropsy revealed extensive hepatosplenomegaly, cardio- and nephromegaly, generalized cavity effusion with visceral adherence, intense visceral paleness and cerebral atrophy, owing to the loss of white matter. Conventional light microscopy indicated diffuse cytoplasmatic microvacuolization in almost all organs; positive staining was obtained by Sudan red, Sudan black and PAS. Electron microscopy showed "empty" cytoplasmatic vacuoles in hepatocytes.

MATERIAL AND METHODS

Occasional urine, plasma, leukocytes and skin fibroblasts were collected for biochemical investigations.

Qualitative screening tests for inborn errors of metabolism (IEM) were performed on a urine sample, according to Buist (1968), Perry *et al.* (1966) and Wannmacher *et al.* (1967), with some adaptations.

Circular paper chromatography for separation of urinary and plasma amino acids was performed as described by Oliveira (1991).

Thin-layer chromatography (TLC) for urinary oligosaccharides was done on silica-gel plates (Merck), according to Humbel and Collart (1975) and modified by Santos (1995). Urine samples from our patient and controls (G_{M1} and G_{M2} gangliosidosis, α -mannosidosis, aspartylglycosaminuria, Pompe disease and age-matched normal individuals) were applied in volumes corresponding to 10 μ g of creatinine. Urinary creatinine was determined using the Jaffé alkaline-picrate reaction. Reference standards (raffinose and lactose) were used at a concentration of 1 μ g/ml; applied volumes were 10 μ l. The plate was sprayed with freshly prepared solutions of orcinol in H_2SO_4 or resorcinol in HCl to visualize neutral or sialyloligosaccharides, respectively.

Total urinary hexose content was measured using the phenol- H_2SO_4 method (Dubois *et al.*, 1956); urinary sialic acid (SA) content was determined according to Skoza and Mohos (1976).

β -galactosidase activity was measured in leukocytes and cultured skin fibroblasts (Suzuki, 1977). α -N-acetyl-neuraminidase was determined according to O'Brien and Warner (1980) in cultured skin fibroblasts.

LABORATORY RESULTS

Urinary screening tests for IEM revealed only proteinuria. Amino acid chromatograms of plasma and urine were normal.

A large excess of neutral sugars was found in patient's urine sample. Total hexose content was increased about 8 times above normal average value and urinary total and bound SA levels were also extremely elevated, as a consequence of the large amounts of sialyloligosaccharides excreted ([Table I](#)).

Patient	Sialic acid ^a			Hexose ^b
	Free	Bound	Total	Total
T.R.F.	296.05	2236.83	2532.88	39.89
Controls	29.16-268.48	9.72-87.44	38.88-349.92	(5.04 \pm 2.48)
				N = 73
^a Expressed in μ mol of N-acetyl neuraminic acid (sialic acid) (mmol creatinine).				
^b Expressed in μ mol of mannose (mg creatinine).				

An abnormal urinary oligosaccharide profile was revealed by TLC ([Figure 1](#)); the two observed heavy bands had R_f values of 0.25 and 0.07, calculated in relation to raffinose. These two bands showed a blue staining when sprayed with resorcinol solution, confirming the presence of sialic acid residues ([Figure 2](#)).

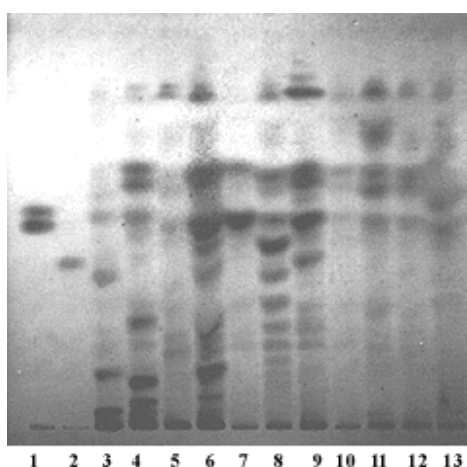


Figure 1 - TLC for urinary oligosaccharides.

Lines: **1**, Lactose (upper) and raffinose; **2**, sialic acid; **3**, patient's (T.R.F.) sample; **4**, G_{M1} gangliosidosis; **5**, G_{M2} gangliosidosis (Sandhoff disease); **6**, aspartylglycosaminuria; **7**, mucopolipidosis II; **8**, α -mannosidosis; **9**, glycogen storage disease type II (Pompe disease); **10 to 13**, normal controls.

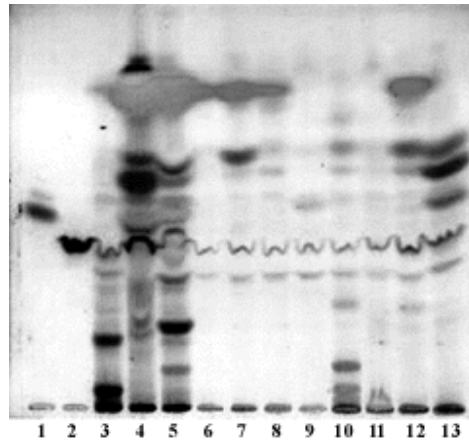


Figure 2 - TLC for urinary sialyloligosaccharides.

Lines: **1**, Lactose and raffinose; **2**, sialic acid; **3**, patient's (T.R.F.) sample; **4**, mucopolipidosis II; **10**, G_{M1} gangliosidosis (normal for sialyloligosaccharides). Other samples were normal for the presence of sialyloligosaccharides.

Enzyme activity determinations confirmed the combined deficiency of β -galactosidase and α -N-acetyl-neuraminidase ([Table II](#)).

Patient	β -galactosidase*		α -N-acetyl neuraminidase*
	Leukocytes	Fibroblasts	Fibroblasts
T.R.F.	6.9	58	2.5
Controls	78-280	304-1600	24-184

*Expressed in nmol/h per mg protein.

DISCUSSION

Initially, the clinical and pathological findings suggested the possibility of a storage disease, like G_{M1} gangliosidosis (or other forms of sphingolipidosis), sialidosis or galactosialidosis.

The laboratory results, especially the excessive urinary amounts of bound sialic acid and the characteristic oligosaccharide TLC profile (which is identical for sialidosis and galactosialidosis), pointed to one of these two dysfunctions.

Complementary demonstration of combined β -galactosidase and α -neuraminidase deficiency in fibroblasts confirmed a typical case of early infantile type of galactosialidosis. To the best of our knowledge, this is the first reported case in Brazil.

This study demonstrates the efficiency of the TLC method performed for detection of lysosomal storage diseases with oligosaccharide excretion, as well as its importance in our investigation program for IEM.

ACKNOWLEDGMENTS

Financial support by FAPERJ-FIOCRUZ, Brazil, is gratefully acknowledged.

RESUMO

Apresentamos o primeiro caso de galactosialidose do tipo infantil precoce identificado entre a população brasileira, uma grave e rara doença de depósito lisossomal, com apenas 12 casos claramente descritos mundialmente. Estudos clínicos, patológicos e bioquímicos realizados foram consistentes com os dados já publicados na literatura científica. Detectamos a doença em uma menina de 7 meses de idade, com diagnóstico de ascite no período pré-natal e evolução compatível com doença de depósito, através da cromatografia em camada fina para oligossacarídeos, que é parte integrante do programa de triagem para erros inatos do metabolismo (EIM) em crianças de alto risco, realizado no Estado do Rio de Janeiro.

REFERENCES

Buist, N.M.R. (1968). Set of simple side-room urine tests for detection of inborn errors of metabolism. *Brit. Med. J.* 2: 745-749. [[Links](#)]

D'Azzo, A., Hoogeveen, A., Reuser, A.J.J., Robinson, D. and Galjaard, H. (1982). Molecular defect in combined β -galactosidase and neuraminidase deficiency in man. *Proc. Natl. Acad. Sci. USA* 79: 4535-4539. [[Links](#)]

D'Azzo, A., Andria, G., Strisciuglio, P. and Galjaard, H. (1995). Galactosialidosis. In: *The Metabolic Basis of Inherited Disease* (Scriver, R.C., Beaudet, L.R., Sly, W.S. and Valle D., eds). 7th edn. McGraw-Hill, Inc., New York, pp. 2825-2838.

[[Links](#)]

Dubois, M., Gilles, A.K., Hamilton, J.K., Rebers, P.A. and Smith, F. (1956). A colorimetric method for determination of reducing sugars and related substances. *Anal. Chem.* 28: 351-353. [[Links](#)]

Galjaard, H., Willemsen, R., Hogeveen, A.T., Mancini, G.M.S., Palmieri, S., Verheijen, F.W. and D'Azzo, A. (1987). Molecular heterogeneity in human β -galactosidase and neuraminidase deficiency. *Enzyme* 38: 132-143. [[Links](#)]

Humbel, R. and Collart, M. (1975). Oligosaccharides in urine of patients with glycoprotein storage diseases: I. Rapid detection by thin-layer chromatography. *Clin. Chim. Acta* 60: 143-145. [[Links](#)]

McKusick, V.A. (1994). *Mendelian Inheritance in Man. Catalogs of Human Genes and Genetic Disorders*. 11th edn. Johns Hopkins University Press, Baltimore. [[Links](#)]

O'Brien, J.S. and Warner, T.G. (1980). Sialidosis: delineation of subtypes by neuraminidase assay. *Clin. Genet.* 17: 35-38. [[Links](#)]

Oliveira, C.P.H. (1991). Caracterização de aminoacidemias e aminoacidúrias por método cromatográfico. Doctoral thesis, Universidade Federal do Rio de Janeiro, RJ, Brasil. [[Links](#)]

Perry, T.L., Hansen, S. and MacDougall, L. (1966). Urinary screening tests in prevention of mental deficiency. *Can. Med. Assoc. J.* 95: 89-95. [[Links](#)]

Santos, C.M.R.C. (1995). Caracterização de doenças lisossômicas de depósito com acúmulo e excreção de oligossacarídeos. Master's thesis, Universidade Federal do Rio de Janeiro, RJ, Brasil. [[Links](#)]

Skoza, L. and Mohos, S. (1976). Stable thiobarbituric acid chromophore with dimethyl sulphoxide. Application to sialic acid assay in analytical de-O-acetylation. *Biochem. J.* 159: 457-462. [[Links](#)]

Suzuki, Y. (1977). Globoid cell leukodystrophy (Krabbe disease and gangliosidosis). In: *Practical Enzymology of the Sphingolipidoses* (Glew, R.H. and Peters, S.P., eds.). Alan R. Liss, New York. [[Links](#)]

Suzuki, Y., Nakamura, N., Shimada, Y., Yotsumoto, H., Endo, H. and Nagashima, K. (1977). Macular cherry-red spots and β -galactosidase deficiency in an adult patient. An autopsy case with progressive cerebellar ataxia, myoclonus, thrombocytopeny, and accumulation of polysaccharide in liver. *Arch Neurol.* 34: 157-161. [[Links](#)]

Wannmacher, C.M.D., Wajner, M., Buchhalter, M.S., Dutra Filho, C.S., Pellini, V.B., Pedroso, D.L., Branco, F.S., Goldani, M.Z. and Bolner, A.R. (1987). Detection of inborn errors of metabolism in unselected patients from pediatric intensive

care units in Porto Alegre, Brazil: evaluation of screening techniques. *Braz. J. Med. Biol. Res.* 20: 11-12. [[Links](#)]

Yamano, T., Dezawa, T., Koike, M., Okada, S., Shimada, M., Sugino, H. and Yabuuchi, H. (1985). Ultrastructural study on a severe infantile sialidosis (β -galactosidase- α -neuraminidase deficiency). *Neuropediatrics* 16: 109-112. [[Links](#)]

Zhou, X.Y., van der Spoel, A., Rottier, R., Hale, G., Willemsen, R., Berry, G.T., Strisciuglio, P., Andria, G. and D'Azzo, A. (1996). Molecular and biochemical analysis of protective protein/cathepsin A mutations: correlation with clinical severity in galactosialidosis. *Hum. Mol. Genet.* 5: 1977-1987. [[Links](#)]