

CASE REPORTS

Coccidioidomycosis: an unusual cause of acute respiratory distress syndrome *

KELSON NOBRE VERAS¹, BRUNO C. DE SOUZA FIGUEIRÊDO², LILINE MARIA SOARES MARTINS³,
JAYRO T. PAIVA VASCONCELOS⁴, BODO WANKE⁵

A male farmer, 20 years old, from the countryside of the State of Piauí, developed acute respiratory infection. Despite adequate antimicrobial therapy, his conditions worsened, requiring mechanical ventilation. His X-rays showed diffuse pulmonary infiltrates. His PaO₂/FiO₂ ratio was 58. Direct microscopy and culture of tracheal aspirates showed the presence of *Coccidioides immitis*. Autochthonous cases of coccidioidomycosis have only recently been described in Brazil, most of them from the State of Piauí. *C. immitis* has been isolated from humans, dogs and armadillos (*Dasypus novemcinctus*), and also from soil samples of armadillo's burrows. Failure to respond to antimicrobial therapy and a patient's origin from recognized endemic areas should alert to the possibility of acute pulmonary coccidioidomycosis. (*J Pneumol* 2003;29(1):45-8)

Key words – *Coccidioides immitis*.
Coccidioidomycosis. Respiratory distress syndrome.

Abbreviations used in this work:

AARB – Alcohol-acid resistant bacilli
HIV – Human immunodeficiency virus
PaO₂/FiO₂ – Ratio of partial arterial oxygen pressure and the inhaled fraction of oxygen
PEEP – Positive end expiratory pressure
ARDS – Acute respiratory distress syndrome
ICU – Intensive Care Unit

* Work performed at the Intensive Care Service of the São Marcos Hospital, Teresina, Piauí.

1. MD, Infectologist. MSc in Tropical Medicine, Physician of the Intensive Care Service of the São Marcos Hospital, Teresina, Piauí.
2. MD, Pneumologist. Physician of the Intensive Care Service of the São Marcos Hospital. Professor at “Faculdade Estadual de Medicina”, Teresina, Piauí.
3. Professor at “Faculdade Estadual de Medicina”. Microbiologist at the Nathan Portela Institute for Tropical Diseases, Teresina, Piauí.
4. Coordinator of the Intensive Care Service of the São Marcos Hospital, Teresina, Piauí.
5. Full Researcher (Pesquisador Titular) of the Evandro Chagas Institute for Clinical Research, Fundação Oswaldo Cruz-Fiocruz (Oswaldo Cruz Foundation), Rio de Janeiro, RJ.

Mailing address: Dr. Kelson Nobre Veras, Rua Teófilo dos Santos, 1.382, bloco 8, apto. 304 – 64056-450 – Teresina, PI, Brazil. Phone.: 55 (86) 981-8526, 55 (86) 232-0014; e-mail: kveras@uol.com.br

Received for publication on 07/29/02. Approved, after revision, on 12/02/02.

INTRODUCTION

Acute respiratory distress syndrome (ARDS) is a respiratory process of acute onset, showing on X-rays as bilateral pulmonary infiltrates and severe respiratory failure, characterized by a partial arterial oxygen pressure/ inhaled oxygen fraction ($\text{PaO}_2/\text{FiO}_2$) ratio below or equal to 200⁽¹⁻³⁾.

Disorders associated with ARDS include direct lesions of the pulmonary parenchyma and lesions indirectly affecting the lung⁽⁴⁾. Among the most frequent causes are sepsis, severe pneumonia, peritonitis, and multiple trauma⁽⁵⁾. *Coccidioidomycosis* is an unusual cause of acute respiratory distress syndrome^(6,7), and no Brazilian case has been described so far. However, this systemic mycosis has been increasingly diagnosed in Brazil^(8,17), requiring a broader diffusion of information about this disease and its possible clinical presentations.

CASE REPORT

A male patient, 20 years old, farmer, living in the municipality of Bertolândia, countryside of the State of Piauí, was admitted to a local hospital, presenting a clinical picture of acute respiratory infection that had been developing for about seven days. During hospitalization, he received a combination of oxacillin and amycacine for six days, but his condition worsened. He was then referred to a hospital in Teresina (capital of the State of Piauí), where the oxacillin dose was increased to 12g/day, with amycacine being kept at 500mg every 12 hours.

On the third day after hospital admission, the patient's condition worsened. Needing mechanical ventilation, he was transferred to the ICU with a clinical picture of severe respiratory failure. A chest X-ray revealed lungs with bilateral diffuse condensations, and this picture worsened rapidly (Figures 1 and 2), the $\text{PaO}_2/\text{FiO}_2$ ratio being initially 71, further on dropping to 58 ($\text{FiO}_2 = 1.0$). HIV-1 and 2 testing (ELISA method) was negative in two samples, as was the test for antigen p24.

Upon admission to the ICU, the patient was placed under mechanical ventilation with pressure control. The antibiotics were replaced by vancomycin and cyprophloxacin. The next morning, after evaluation by the Infectology Service, amphotericin B was added. However, the patient died about 48 hours after his admission to the ICU.

Bacteriologic examination of his tracheal aspirate presented less than 10 epithelial cells and more than 25 leukocytes per field, with rare gram-positive cocci. The search for AARB in the tracheal aspirate was negative; however, direct search for fungi revealed spherical elements with a thick wall, several of them filled with endospores, characterizing mature *Coccidioides immitis* spherules. The tracheal aspirate culture was negative for bacteria, but the fungus cultures produced suspicious filamentous colonies which, after intraperitoneal inoculation in mice, revealed spherules which are characteristic for *C. immitis*, confirming this dimorphic fungus as being responsible for the etiology of the patient's clinical picture (Figure 3).

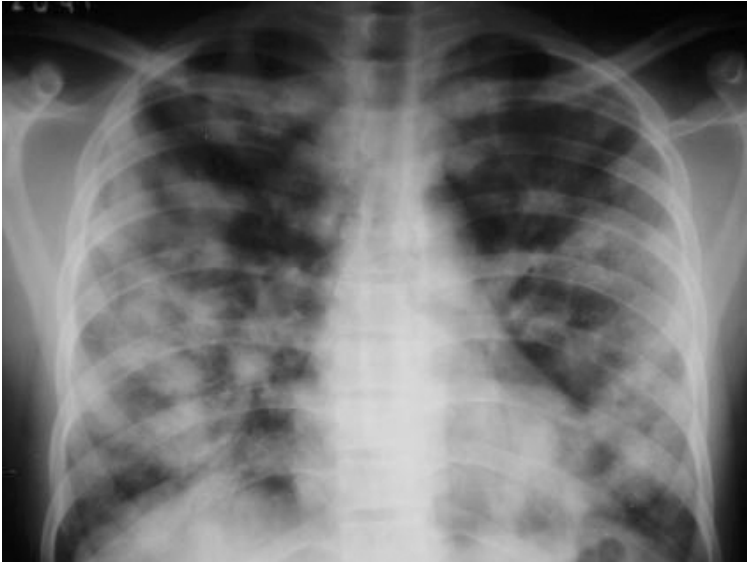

Figure 1 – Chest X-rays showing diffuse bilateral confluent pulmonary nodules

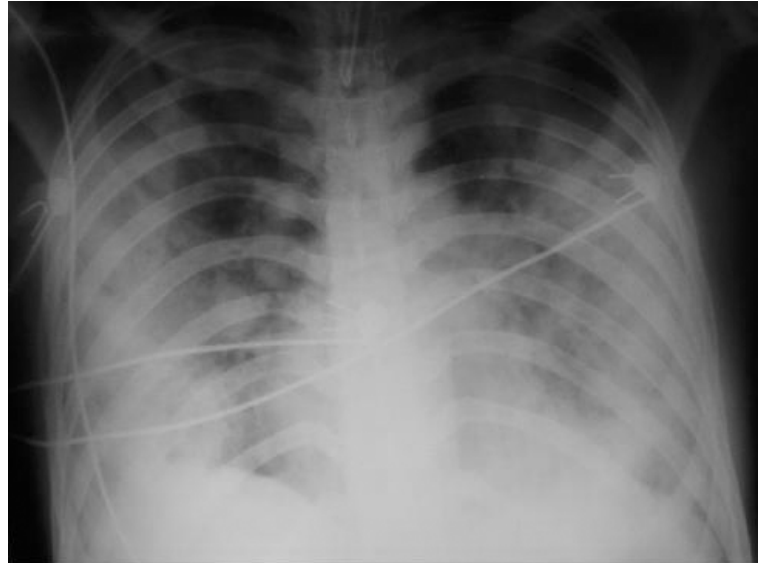


Figure 2 – Progression of the pulmonary infiltrates during the patient's stay in the intensive therapy unit

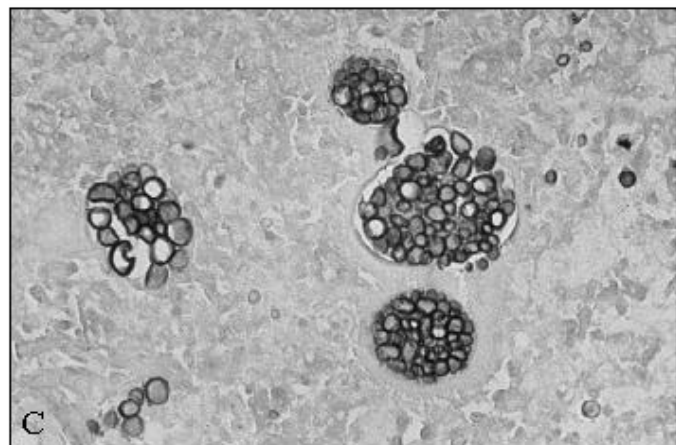
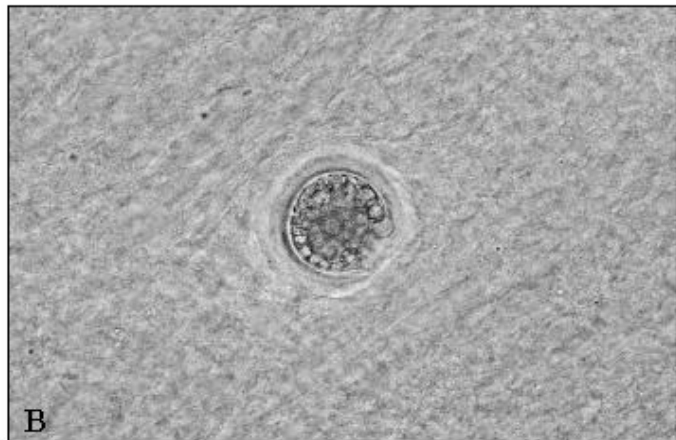
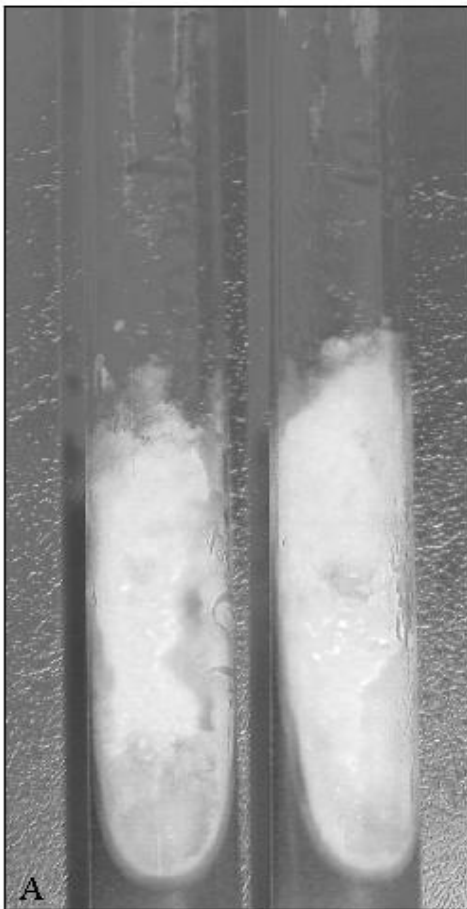

Figure 3 – (A): *Coccidioides immitis* – Filamentous colonies isolated from patient's sputum; (B): immature and mature spherules in liver tissue from mice inoculated with

the isolated filamentous fungus: direct examination in 10% KOH; (C): histologic section with Gomori-Grocott silver impregnation. (x 400)

DISCUSSION

C. immitis is a dimorphic fungus found in nature as a saprophytic filament (mould) that produces propagules (arthroconidia) which spread easily in the air and are highly infectious to susceptible humans and many animals who inhale them, usually mixed with dust from the soil. As they reach the pulmonary alveoli, they are phagocytosed and take, inside the alveolar macrophages, the characteristic parasite shape of spherical elements which, when they are mature and filled with endospores, constitute the spherules⁽¹⁸⁾. In the human organism, before the immune response is established, dissemination to any organ or tissue can occur, establishing secondary mycosis foci.

It is estimated that, in endemic areas, approximately 60% of the infected individuals have asymptomatic or oligosymptomatic infections, followed by spontaneous regression. After this spontaneous cure, the fungus can remain viable and latent at residual foci, which may, after long latency periods, eventually become reactivated and cause clinical manifestation.

When it is symptomatic, this mycosis usually manifests as an acute feverish respiratory disease, the symptoms starting, on the average, 7 to 28 days after exposure to the fungus, being characterized mainly by fever, malaise, cough, and chest pain of the pleuritic type. The golden standard for diagnosis is the demonstration of the characteristic spherules in clinical specimens, achieved by direct microscopic examination of preparations with a 10% KOH solution, although, in some cases, specimen cultures are needed for identification. The diagnosis can also be made by immunological tests, the most commonly used being double immunodiffusion in agar gel, or by DNA hybridization⁽¹⁸⁾.

Classically, coccidioidomycosis is known as an endemic systemic mycosis of semi-arid areas of the American continent, affecting the Southeast of the United States, North Mexico, and semi-arid land strips of Central and South America⁽¹⁹⁾. The first autochthonous cases in Brazil were reported in 1978 and 1979^(8,9), the first case being from the State of Bahia and the second one from Piauí, where he had lived his whole life. About 15 years later, the first micro-outbreak of this mycosis in Brazil was also reported in the State of Piauí⁽²⁰⁾. Since then, the number of published cases has increased considerably⁽¹¹⁻¹⁶⁾, the association between this infection and the digging of armadillo (*Dasypus novemcinctus*) burrows was widely described^(12,20), the fungus has already been isolated from tissues of this animal⁽¹⁷⁾, of dogs, and from soil samples collected in armadillo burrows⁽¹⁶⁾. Currently, this systemic mycosis is considered endemic in the Northeast Brazilian States of Bahia, Ceará, Piauí, and Maranhão⁽¹⁶⁾. In Piauí only, 24 cases were already diagnosed, almost always related to the hunting and unearthing of armadillos.

The present report describes a patient from a municipality where another case has already been published⁽¹⁵⁾. His relatives reported that he was currently busy digging the soil to build a wooden fence, besides taking often part in armadillo hunts, a proven risk activity for coccidioidomycosis in Brazil.

Upon admission to the ICU, the patient met the most recent classification criteria for acute respiratory distress syndrome⁽³⁾. Gattinoni *et al.*⁽⁵⁾ remarked that, when the triggering disease is a direct pulmonary lesion, such as pneumonia, the prevailing pathology is one of pulmonary consolidation, whereas extrapulmonary causes determine predominantly interstitial edema and alveolar collapse. These authors consider that, in the first case, the pulmonary volume

recruitment by a positive end expiratory pressure (PEEP) of up to 15cmH₂O is only marginal, whereas, in the acute respiratory distress syndrome caused by extrapulmonary disease, PEEP recruitment is marked.

The association of coccidioidomycosis with ARDS is unusual and was previously recorded only in the United States^(6,7). To our knowledge, there is no Brazilian publication on this association.

Arsura *et al.*⁽⁶⁾ reported that coccidioidomycosis was only considered in five out of eight immunocompetent patients with coccidioidomycotic septic shock, and that, in spite of amphotericin B therapy, they all died, similarly to the case reported here. Arsura and Kilgore⁽⁷⁾ point out that the miliary pattern on the chest X-rays indicates a lymphatic or hematogenic dissemination of *C. immitis*, thus signaling the severity of the mycosis.

In conclusion, pulmonary coccidioidomycosis remains little known in the medical world, even in endemic regions. The case reported here shows how late its diagnosis is usually considered. A broader diffusion of information about the spreading of coccidioidomycosis in Brazil and the severe medical repercussions it can bring about would draw the doctors' attention to this etiology, allowing them to make a correct diagnosis and provide effective treatment.

REFERENCES

1. Ashbaugh DG, Bigelow DB, Petty TL, Levine BE. Acute respiratory distress in adults. *Lancet* 1967;2:319-23.
2. Petty TL, Ashbaugh DG. The adult respiratory distress syndrome: clinical features, factors influencing prognosis and principles of management. *Chest* 1971;60:233-9.
3. Bernard GR, Artigas A, Brigham KL, Falke K, Hudson L, Lamy M, et al. The American-European Consensus Conference on ARDS: definitions, mechanisms, relevant outcomes, and clinical trial coordination. *Am J Respir Crit Care Med* 1994;149:818-24.
4. Ware LB, Matthay MA. The acute respiratory distress syndrome. *N Engl J Med* 2000;342:1334-49.
5. Gattinoni L, Pelosi P, Suter PM, Pedoto A, Vercesi P, Lissoni A. Acute respiratory distress syndrome caused by pulmonary and extrapulmonary disease: different syndromes? *Am J Respir Crit Care Med* 1998; 158:3-11.
6. Arsura EL, Bellinghausen PL, Kilgore WB, Abraham JJ, Johnson RH. Septic shock in coccidioidomycosis. *Crit Care Med* 1998;26:62-5.
7. Arsura EL, Kilgore, WB. Miliary coccidioidomycosis in the immunocompetent. *Chest* 2000;117:404-9.
8. Gomes OM, Serrano RRP, Prade HOV, Moraes NLTB, Varella ALB, Fiorelli AI, et al. Coccidioidomicose pulmonar: primeiro caso nacional. *Rev Assoc Med Bras* 1978;24:167-8.
9. Vianna H, Passos HV, Sant'ana AV. Coccidioidomicose: relato do primeiro caso ocorrido em nativo do Brasil. *Rev Inst Med Trop São Paulo* 1979;21:51-5.
10. Diogenes MJN, Jamacuru WF, Silva MAB, Carvalho FF. Inquérito epidemiológico com esferulina em Jaguaribara-CE, Brasil, 1993. *An Bras Dermatol* 1995;70:525-9.
11. Kuhl IA, Kuhl G, Londero A, Diogenes MJN, Ferreira MF. Coccidioidomicose laríngea: relato de caso. *Rev Bras Otorrinolaringol* 1996; 62:48-52.
12. Silva LCL, Nunes LMA, Sidrim JJC, Gonçalves AJR. Coccidioidomicose pulmonar aguda: primeiro surto epidérmico descrito no Ceará – segundo no Brasil. *J Bras Med* 1997;72:49-66.
13. Martins MA, Araujo EMPA, Kuwakino MH, Heins-Vaccari, EM, Del Negro GMB, Voza Junior JA, et al. Coccidioidomycosis in Brazil: a case report. *Rev Inst Med Trop São Paulo* 1997;39:299-304.
14. Sidrim JJC, Silva LCI, Nunes JMA, Rocha MFG, Paixão GC. Le nord-est Brésilien, région d'endémie de coccidioidomycose? *J Mycol Med* 1997;7:37-9.
15. Moraes MRP, Martins RLM, Leal IIR, Rocha IS, Medeiros Júnior PM. Coccidioidomicose: novo caso brasileiro. *Rev Soc Bras Med Trop* 1998; 31:559-62.
16. Wanke B, Lazera MS, Monteiro PCF, Lima FC, Leal MJS, Ferreira Filho PL, Kaufman L, et al. Investigation of an outbreak of endemic coccidioidomycosis in Brazil's Northeastern State of Piauí with a review of the occurrence and distribution of *Coccidioides immitis* in three other Brazilian states. *Mycopathologia* 1999;148:57-67.
17. Eulalio KD, Macedo RL, Cavalcanti MAS, Martins LMS, Lazera MS, Wanke B. *Coccidioides immitis* isolated from armadillos (*Dasypus novemcinctus*) in the state of Piauí, northeast Brazil. *Mycopathologia* 2001;149:57-61.

18. Pappagianis D. Coccidioidomycosis. *Semin Dermatol* 1993;12:301-9.
19. Kwon-Chung KJ, Bennett JW. Coccidioidomycosis. In: Kwon-Chung KJ, Bennett JW, editors. *Medical mycology*. Philadelphia: Lea & Febiger, 1992;356-96.
20. Wanke B. Coccidioidomicose. *Rev Soc Bras Med Trop* 1994;27(Supl IV):375-8.