

M E M Ó R I A S
D O
I N S T I T U T O O S W A L D O C R U Z

Tomo 71

Fascículos 1/2

1973

THE LIFE HISTORY OF *HEPATOZOON LEPTODACTYLI*
(LESAGE, 1908) PESSOA, 1970 — A PARASITE OF
THE COMMON LABORATORY ANIMAL — THE
FROG OF THE GENUS *LEPTODACTYLUS*¹

SYLVIO CELSO GONÇALVES DA COSTA **, SAMUEL B. PESSOA ***,
NEIZE DE MOURA PEREIRA ** e TANIA COLOMBO **

Instituto Oswaldo Cruz, Rio de Janeiro, Guanabara
(With 29 Figures)

SUMMARY: The main object of the present paper is to furnish a brief account to the knowledge of Protozoa parasitic in common Brazilian frog of the genus *Leptodactylus* for general students in Zoology and for investigators that use this frog as a laboratory animal. *Hepatozoon leptodactyli* (*Haemogregarina leptodactyli*) was found in two species of frogs — *Leptodactylus ocellatus* and *L. pentadactylus* — in which develop schizogony whereas sporogony occurs in the leech *Haementeria lutzi* as was obtained in experimental conditions. Intracellular forms have been found in peripheral circulation, chiefly in erythrocytes, but we have found them in leukocytes too. Tissue stages were found in frog, liver, lungs, spleen, gut, brain and heart. The occurrence of hemogregarine in the Central Nervous System was recorded by Costa & al, (13) and Ball (2). Some cytochemical methods were employed in attempt to differentiate gametocytes from trophozoites in the peripheral blood and to characterize the cystic membrane as well. The sporogonic cycle was developed in only one specie of leech. A brief description of the parasite is given.

L *EPTODACTYLUS* is a very common genus of frog from Neotropical fauna. A great number of researches in the field of Neurophysiology was undertaken by Almeida and his group — 1919/53 — and by Pacheco (22) in the field of Bacteriology and several papers in the field of Biochemistry as well. We think that Protozoon parasites must be considered in further stu-

dies using these frogs as a Laboratory animal, since these protozooses have a high destructive power in hard infections. The most important destructive action is caused by a blood Sporozoa of the genus *Lankesterella* on Central Nervous System, occurring chiefly in neurons, as was shown by Costa (14), while *Hepatozoon* destructi-

1 Received for publication 3 november 1972.

The present work was supported by Instituto Oswaldo Cruz and by a research grant from Conselho Nacional de Pesquisas.

** Departamento de Zoologia, Instituto Oswaldo Cruz, C.P. 926 - Brasil.

*** Instituto Butantã, S. Paulo - C. P.

ve action is found chiefly in liver and spleen.

The present study was also undertaken in order to contribute to zoologists since *Leptodactylus* has been largely employed in Zoology classes and protozoa of cold blood animals was recommended for classroom work by Jakowska (19). We agree with this point of view.

On the other hand only a few number of members of the family *Haemogregarinidae* have their life cycle well known, and they bring great difficulties to the establishment of taxonomic criteria.

MATERIAL AND METHODS

Blood smears were made from living or freshly killed frogs. Histological sections of internal organs were prepared only in case if blood protozoon were found in the peripheral circulation and organs such as liver, lungs, gut, spleen, kidney and brain were fixed in formalin 10% or Carnoy, sectioned between 8-10 micra and ordinarily staining with Delafield's hematoxylin and eosin, impressions as well. The sections of tissues parasited were stained also by other methods such as Feulgen, Methyl-Green Pyronin, and PAS, for best characterization of the cysts. These cytochemistry methods were also employed in blood slides in an effort to obtain additional information to differentiate trophozoites from young gametocytes.

Attempts of cultivation have been made by the use of the following media: SNB9 of Diamond (18), Boné & Parent (3) and Boné & Steinert (4).

Fluorescence microscopy was employed in blood and culture forms using acridine orange method.

The infected hosts are frogs belonging to the genus *Leptodactylus*: *L. pentadactylus* and *L. ocellatus*. The results of examination of other amphibia have been negative. These amphibia have been collected from 1964 up to, 1972 in different states of Brazil, as can be seen in Table I.

The leeches *Haementeria lutzi* have been captured in the same place where we had obtained several *L. pentadactylus* parasited by *Hepatozoon*, at Goiás State, near to the Jockey Club.

Measurements have been made under the Olympus Filar micrometer eyepiece.

RESULTS

Table I lists the localities and kinds of brazilian amphibia negative and positive for *Haemogregarinidae* in blood. Seventeen out of ninety *Leptodactylus* had hemogregarines in the peripheral circulation, sometimes in hard infection.

Since the sexual cycle of this parasite in leeches has lately been obtained by one of us (see preliminar note in Pessoa (24)) a revised diagnosis is presented here.

Table I

COLLECTION SITES NEGATIVE AND POSITIVE FOR
HAEMOGREGARINA IN BLOOD AMPHIBIA

AMPHIBIA	INFECTED HOSTS LOCALITIES	NEGATIVE HOSTS LOCALITIES
<i>Atelopus moreirae</i> Mir. Ribeiro, 1920	————	ITATIAIA (Estado do Rio de Janeiro)
<i>Bufo crucifer</i> Wied	————	TERESÓPOLIS (Estado do Rio de Janeiro) RIO DE JANEIRO (Guanabara)
<i>Bufo marinus</i> (L. 1758)	————	FRIBURGO, SACRA FAMÍLIA and PIABETÁ (Estado do Rio de Janeiro); UTINGA (Pará) and RIO DE JANEIRO (Guanabara)
<i>Hyla faber</i> Wied (1821)	————	TERESÓPOLIS (Estado do Rio de Janeiro)
<i>Hyla langsdorffi</i> Dum S. Bibr, 1824	————	RIO DE JANEIRO (Guanabara)
<i>Hyla albomarginata</i> Spix, 1824	————	RIO DE JANEIRO (Guanabara)
<i>Leptodactylus ocellatus</i>	RIO BONITO, SÃO JOÃO DE MERITI, NITERÓI, CANTAGALO and CAXIAS (Estado do Rio de Janeiro); GUANABARA and FLORIANÓPOLIS (Santa Catarina)	TERESÓPOLIS, ALCÂNTARA and GUANDU (Estado do Rio de Janeiro) RIO DE JANEIRO (Guanabara)
<i>Leptodactylus pentadactylus</i>	SANTOS (São Paulo) SALVADOR (Bahia) and GOIÂNIA (Goiás)	————

Hepatozoon leptodactyli

- Leucocytozoon ranarum* Carini, 1907:374
Haemogregarina leptodactyli Lesage,
 1908:995
Haemogregarina leptodactyli Carini,
 1908:59
Haemogregarina heteronucleata Carini,
 1909:469
Haemogregarina sp. Carini,
 1911:543
Haemogregarina leptodactyli Pinto,
 1925:241
Haemogregarina leptodactyli Wenyon,
 1926:1397
Haemogregarina leptodactyli Cunha
 & Muniz, 1927:443
Haemogregarina leptodactyli Cunha
 & Muniz, 1927:307
Haemogregarina leptodactyli Cunha &
 Muniz, 1927:1351
Haemogregarina ranarum Carini, 1945:110
Haemogregarina leptodactyli Costa, Silva
 & Martinez Bernao-
 la, 1970:55
Haemogregarina leptodactyli Costa, Pereira
 & Martinez Bernao-
 la, 1970:47
Hepatozoon leptodactyli (Lesage, 1908)
 Pessoa, 1970:35
Hepatozoon leptodactyli Costa, & Pereira,
 1971:407

VERTEBRATE CYCLE

Blood forms: Both erythrocytic and extracellular hemogregarines were found in peripheral circulation.

Erythrocytic forms: The inicial stage in erithrocyte is a crescent or roundish form. The mature erythrocytic forms ranged in size from $21\mu^*$ by $8,3\mu^*$ to $5,1\mu^*$ by $2,3\mu^*$. Distinct capsules were visible in those forms presenting one curved pole (fig. 4) or in those cases that erythrocytic nucleus was displaced to one pole of the blood cell

(fig. 10). We found sometimes a capsule free from the parasite in the host cell (fig. 9). The nucleus was median or subterminal and generally consists of fine granules and threads, but compact oval or almost rounded nucleus, occur too, and was $4,6\mu^* \times 3\mu^*$ in average. Red staining cytoplasmic inclusions were generally found with May-Grünenwald Giemsa stain, in small number, but in PAS stained method we found a great number of them or a positive difuse reaction in some pole of the parasite. These granules are PAS positive in smear treated by amilase and so they have no paraglycogen nature. *H. leptodactyli* parasites leucocytes (figs. 12 to 15) as well as erythrocytes in hard infections. In hard infection we frequently found two or three parasites either in erythrocytes (figs. 1, 5, 7, 8 and 16) or leucocytes.

Extracellular forms: Extracellular forms are fine and elongated with heavily stained nuclei (fig. 25). These forms measure approximately the same size of the intracellular ones, averaging $17,8\mu^* \times 12,8\mu^*$. The cytoplasm of intracellular forms stains slight blue while extracellular forms present more heavily stained cytoplasm by May-Grünenwald Giemsa.

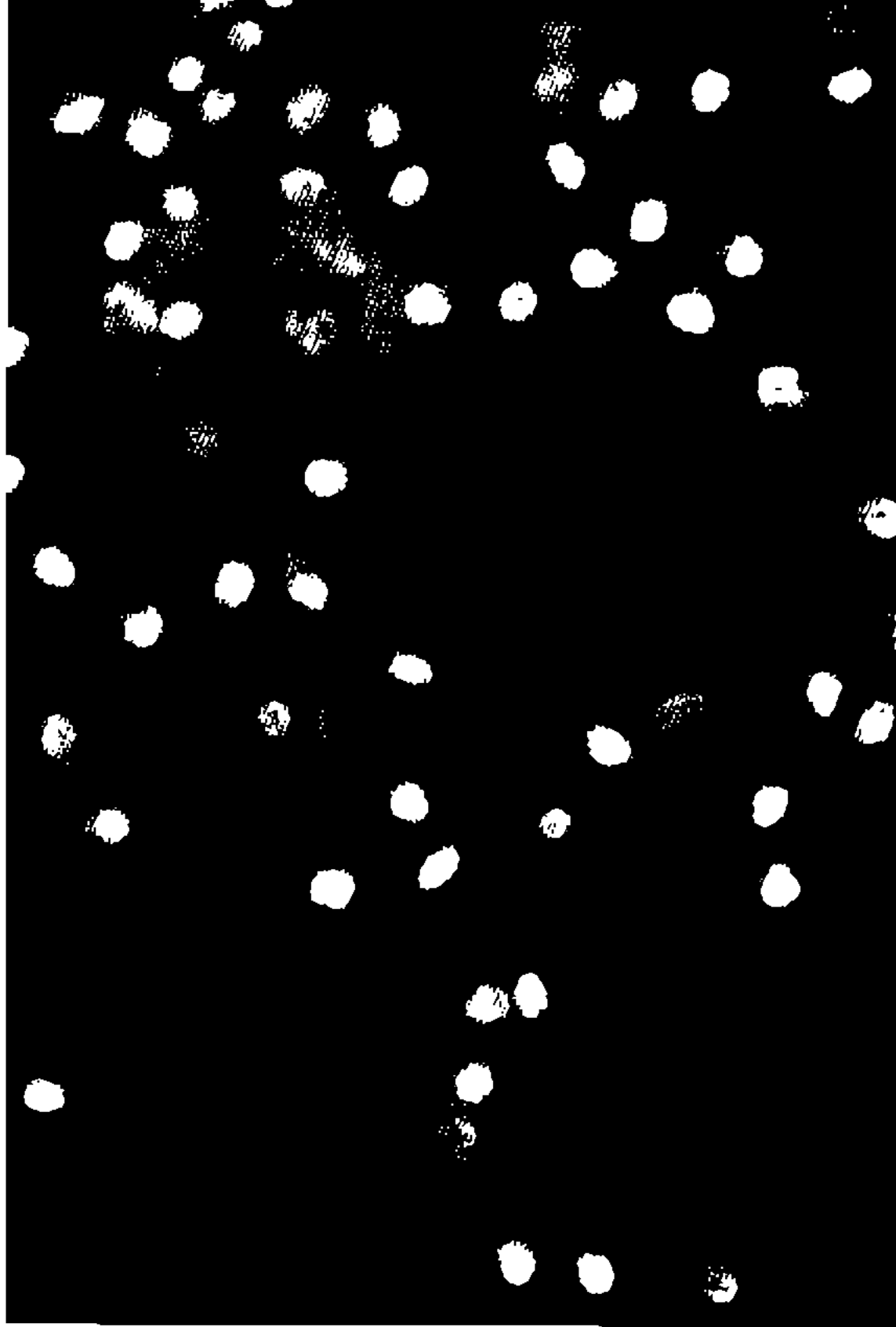
Effects upon host cells: We had observed only a little hypertrophy of infected erythrocyte (fig. 6). Sometimes the erythrocytic nucleus was displaced (figs. 1, 10 and 11). In cases of multiple infection the infected cells may be very enlarged (figs. 5 and 16). In

μ^* = micra.

Figs. 1a

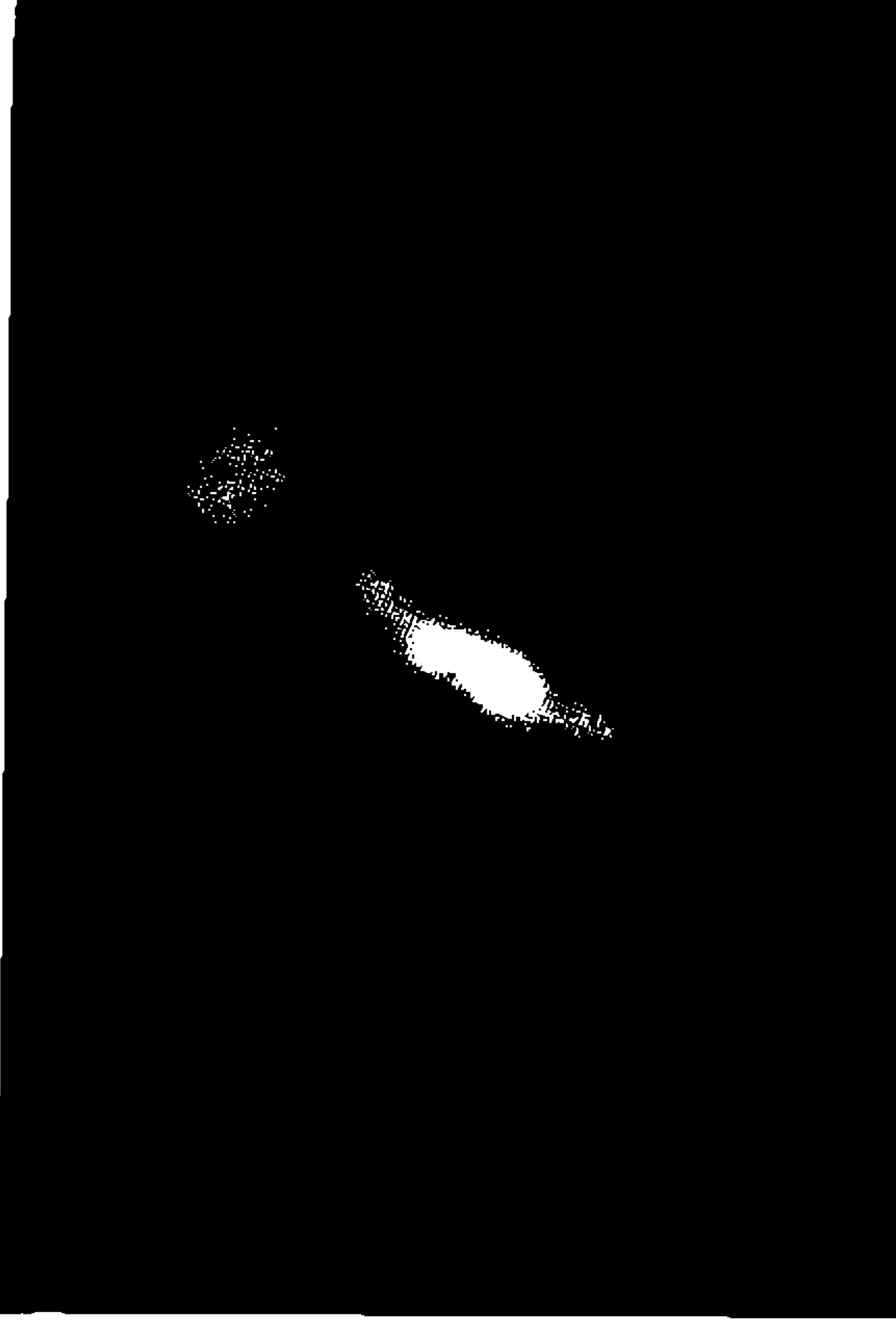
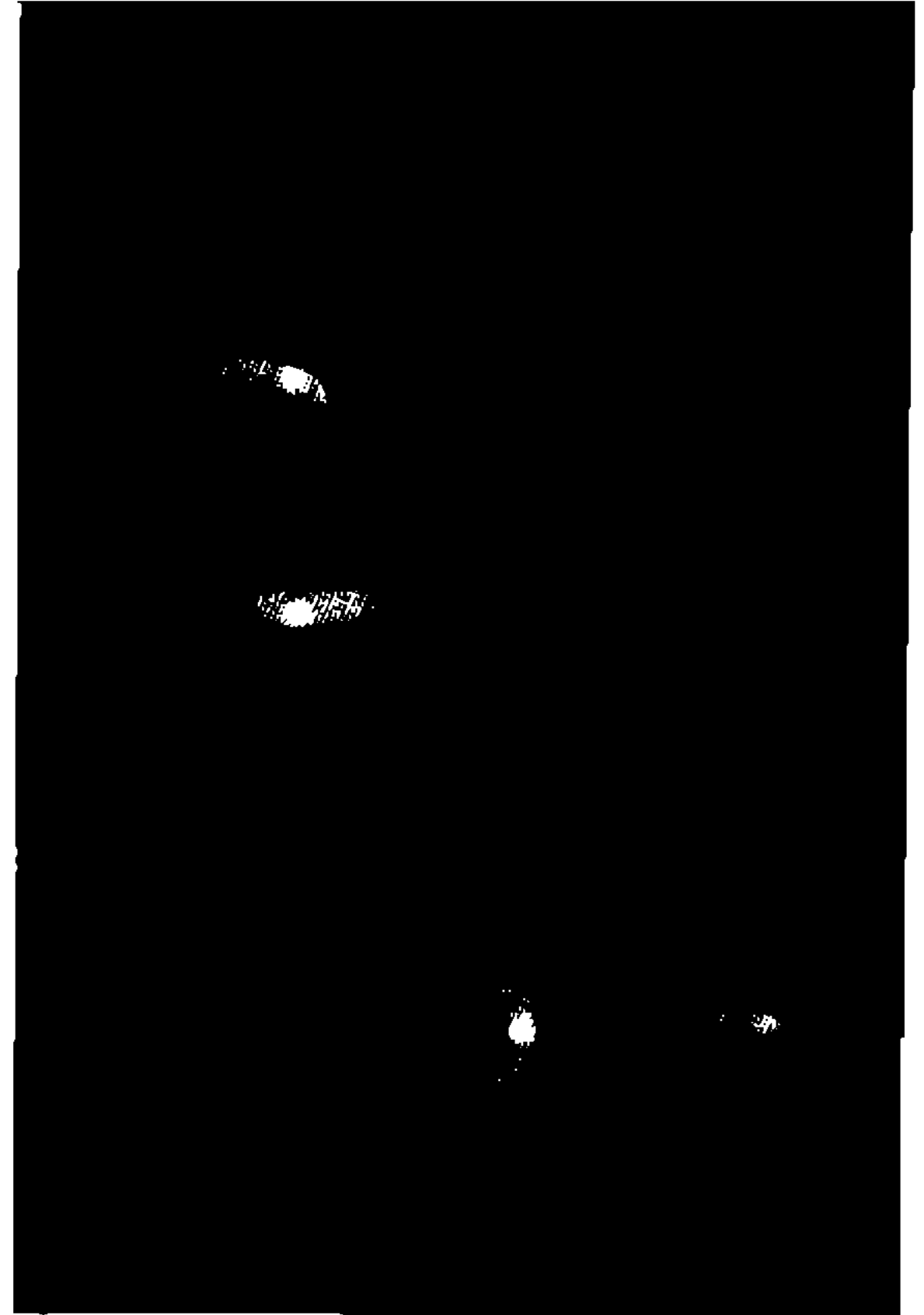
Fig. 1b



Figs. 1a and 1b: Fluorescence microscopy by acridine orange stained method. Fig. 1a: Blood forms maintained in culture media. (obj. 100 x and obj. 40 x). Fig. 1b: Blood smears showing gametocytes (obj. 40 x).




Fig. 1c: Methyl-green pyronin stained impressions of *Hepatozoon leptodactyli* in the liver of *Leptodactylus ocellatus*.

Figs. 1c

many parasitised erythrocytes the nucleus is hypertrophied. All of this is probably due to the mechanical effect of the large hemogregarines.

Tissue forms: Schizogony occurs mainly in liver and spleen (figs. 17 to 24). In heavy infections, schizogony was found also in lung, small intestine, heart and brain. We had not examined bone marrow and kidney. Schizonts were found in capillary (fig. 26) and in the glial cells of brain (fig. 27). Two kinds of schizonts were produced and this was well described by Cunha & Muniz (15 a 17). Mature microschantos average 13 by 16 with up to 16 to 32 micromerozoites which average is 2,5 by 3 μ *. Macroschantos average by 14 by 14,7 and gives rise to 2 to 8 macromerozoites with average is 18 μ * by 8 μ *. Cyst membrane is PAS positive and the schizonts present a large mass PAS positive that in the final stage of the cysts, when the merozoites were arranged in the periphery, form the "residual bodies" described by Cunha & Muniz, (15 a 17). The knowledge of these schizonts was complemented by sectioned tissues stained by Methyl-Green Pyronin and Feulgen (Fig. 1c).

Maintenance of blood forms in culture: Blood forms were maintained "in vitro" during 10 days, in Boné-Parent, Boné-Steinert and SNB9 media. Emergence of the parasites, gametocytes occur in great number and presents a cytoplasm with diffuse RNA as we can see by the fluorescence of the

acridine orange stained method (fig. 1a-b). Motility is well seen in this condition. The culture forms presented particular movement, fixing part of the body and moving circularly the opposite one (which is similar to the "trombicule" of the *Toxoplasma*).

Probable vector (experimental): *Haementeria lutzi* — These leeches were captured in the same place in which several *L. pentadactylus* parasited by *H. leptodactyli* were found. In experimental conditions the frog hemogregarines developed the sporozoite stage in the gut of the leech after 1 month of the transmission by sucking the infected *L. pentadactylus*. After dissection of leech in one of them we found a great number of cysts in the digestive tractus. These were sporocysts of roundish form measuring 26 to 32 micra (fig. 28 and 29). Sporozoites were in a sporocyst in a number of 18 to 38 and these measured 17 to 18 micra by 3 to 4 micra, with a nucleus measuring 4 micra on the average. Only one oocyst was developed. As *Haementeria lutzi* is frequently found attached in *Leptodactylus pentadactylus* we think that this is one of the natural vectors.

Type host: *Leptodactylus ocellatus*.

Type locality: Argentine (Buenos Aires).

DISCUSSION

Although a great number of species of hemogregarines have been described from amphibian hosts the studies in this field is based in the majority of instances on the blood

forms and sometimes on the forms in the internal organs, but life histories including invertebrate host is a lack.

For these reasons some taxonomic criteria proposed to separate *Haemogregarine* from *Hepatozoon* or *Karyolysus* are not satisfactory and this subject was well discussed by Mohammed and Mansour⁽²¹⁾ and Ball⁽¹⁾.

The "*Haemogregarine leptodactyli*" was described by Lesage⁽²⁰⁾ and the generic designation was just discussed by Cunha & Muniz^(15 to 17) in a good description presented by these authors when they wrote the title of the paper: "Sobre o ciclo endógeno da *Haemogregarine leptodactyli*, Lesage, 1908 (Karyolysus?)".

According to Ball scheme of classification, only now, with the experimental transmission of the parasite we have the solution of the problem, and this specie belongs to the genus *Hepatozoon*.

The second point to be questioned is the host specificity in vertebrate and vectors. The occurrence in the blood of *L. ocellatus* of small hemogregarine and either broad or curved capsulated forms as well as the same forms in *L. pentadactylus* is a support for the view that the same hemogregarine parasite the both species of frog. Tissue forms are identical in both hosts too.

We had tried to separate trophozoites from gametocytes using some cytochemistry stain methods but neither the cytoplasm nor the nucleus presented any reliable criteria for separating them.

We have designated by blood forms the parasites occurring in the peripheral blood and a good discussion of this problem was presented by Ball⁽¹⁾.

Occurrence of hemogregarines in white cell is another point that we do not think is of taxonomic importance since we could observe parasitism in white cell when hard infections was obtained with others blood hematozoon like *Lankesterella* Costa & col.⁽¹⁴⁾ and *Toddia* Pereira & col.⁽²³⁾.

Occurrence of hemogregarine schizogony in Central Nervous System and some confusion of these cysts with *Toxoplasma gondii* by some authors was discussed by us in a previous paper Costa & col.⁽¹³⁾. We think that the occurrence of hemogregarines in brain is more common since perhaps is not frequent the examination of C.N.S. by several investigators in this field. Ball⁽²⁾ found *Hepatozoon fusifex* in the brain of *Boa constrictor* in a hard infection.

The stages in the sexual cycle of this parasite in leeches perhaps will give in further studies a definitive knowlegdment about specific status of hemogregarines in both species of *Leptodactylus*.

RESUMO

Os autores apresentam uma revisão da hemogregarina parasita de rãs do gênero *Leptodactylus*. A posição sistemática sob o ponto de vista genérico fica definida com os estudos do ciclo no vetor *Haementeria lutzi*, publicados em nota preliminar por um dos autores (Pessoa²⁴) quando utilizou rãs *L. pentadactylus* em trabalho experimental. Este trabalho experi-

mental continua sendo desenvolvido no Laboratório de Protozoologia do Instituto Oswaldo Cruz, utilizando a rã *L. ocellatus* e as sanguessugas *Haementeria vizuttoi* e *Haementeria gracilis*.

Algumas técnicas citoquímicas foram empregadas para melhor caracterização dos esquizontes e das granações do citoplasma das formas sanguíneas.

REFERENCES

- 1 — BALL, G. H., 1967, Some blood Sporozoans from East African Reptiles, *J. Protozool.*, 14(2):198-210.
- 2 — BALL, G. H., CHAO, J. & TELFORD Jr., S. R., 1969, *Hepatozoon fusifex* sp. n., A hemogregarine from *Boa constrictor* producing marked morphological changes in infected erythrocytes *J. Parasitol.*, 55(4): 800-813
- 3 — BONÉ, G. J. & PARENT, G., 1963, Stearic acid, an essential growth factor for *Trypanosoma cruzi*. *J. Gen. Microbiol.*, 31:261-266.
- 4 — BONÉ, G. J. & STEINERT, M., 1956, Isotopes incorporated in the nucleic acids of *Trypanosoma mega*, *Nature, London*, 178:308.
- 5 — CARINI, A., 1907, Um Leucocitoozoon de rana. *Rev. Med. São Paulo*, 10:374.
- 6 — CARINI, A., 1907, Un leucocitoozoon del *Leptodactylus ocellatus*. *Rev. Soc. Sci. S. Paulo*, 3:59.
- 7 — CARINI, A., 1908, Sobre a *Haemogregarina leptodactyli* do *Leptodactylus ocellatus*. *Rev. Soc. Sci. S. Paulo*, 3:59-60.
- 8 — CARINI, A., 1909, Sur une hémo-gregarine du *Leptodactylus pentadactylus*. *Bull. Soc. Path., Exot.*, 2:469-471.
- 9 — CARINI, A., 1911, Zur Frage der Doppelkernigkeit mancher Hämo-gregarinen. *Centralbl. f. Bakt. Abt. Originale. Bd. 61. Heft 1/2*, 542-544.
- 10 — CARINI, A., 1945, Lista dos parasitos novos ainda pouco estudados, descritos pelo Dr. A. Carini. *Arch. Biol.*, 29:108-113
- 11 — COSTA, S. C. G., SILVA, A. M. & MARTINEZ BERNAOLA, N., 1970, Hemoparasitos de anfíbios do Brasil: Estudo citoquímico de "*Haemogregarina leptodactyli*" Lesage, 1908. *Atas Soc. Biol. Rio de Janeiro*, 13(1/2):55-58.
- 12 — COSTA, S. C. G., PEREIRA, N. M. & MARTINEZ BERNAOLA, N., 1970, The problem of Toxoplasmosis in "Amphibia" (Part III). A protozoon in the central nervous system of *Leptodactylus ocellatus* (Protozoa, Sporozoa). *Atas Soc. Biol. Rio de Janeiro*, 14(3/4):45-48.
- 13 — COSTA, S. C. G., SILVA, A. M., MARTINEZ, N. & PEREIRA, N. M., 1970, The problem of Toxoplasmosis in Amphibia (Part II) (Protozoa, Sporozoa). *Rev. Bras. Biol.*, 30(3):367-370.
- 14 — COSTA, S. C. G. & PEREIRA, N. M., 1971, *Lankesterella alencari* n. sp. — A Toxoplasma-Like Organism in the Central Nervous System of *Amphibia* (Protozoa, Sporozoa). *Mem. Inst. Oswaldo Cruz*, 69(3): 397-411.
- 15 — CUNHA, A. M. & MUNIZ, J., 1927, Sobre o ciclo endógeno da *Haemogregarina leptodactyli* Lesage, 1908 (*Karyolysus*?). *Mem. Inst. Oswaldo Cruz*, 20:307-315.
- 16 — CUNHA, A. M. & MUNIZ, J., 1927, Sobre o ciclo endógeno da *Haemogregarina leptodactyli* Lesage, 1908 (*Karyolysus*?). *Ci. Med. Rio*, 5:443-449.
- 17 — CUNHA, A. M. & MUNIZ, J., 1927, Sur le cycle endogène d'*Haemogregarina leptodactyli* Lesage, 1908 (*Karyolysus*?). *C. R. Soc. Biol.*, 97:1351-1354.

- 18 — DIAMOND, O. L. S. & HERMAN, C. M., 1954, Incidence of Trypanosomes in the Canada goose as revealed by bone marrow culture. *J. Parasitol.*, 40:195-202.
- 19 — JAKOWSKA, S., 1964, Protozoan Parasites of Cold-blooded Vertebrates as Teaching Material. *J. Parasitol.* 5(3) Sec. 2:41.
- 20 — LESAGE, J., 1908, Sur une Hémo-grégarine de *Leptodactylus ocellatus* L. *C. R. Soc. Biol.*, 65(995-996).
- 21 — MOHAMMED, A. H. H. & MANSOUR, N., 1959, The hemogregarine complex (An analytical systematic review). *Bull. Fac. Sci. Cairo Univ.*, 35:39-51.
- 22 — PACHECO, G. P., COSTA, G. A., MOUSSATCHÉ, I. & MELLO, M. T., 1947, Alterações fisiológicas do sistema nervoso central de rã pelas toxinas de *Cl. perfringens*, *Cl. oedematiens* e *Cl. septicum*. *Mem. Inst. Oswaldo Cruz*, 45(3):609-617.
- 23 — PEREIRA, N. M., COSTA, S.C.G. & SOUSA, M. A., 1972, *Toddia* sp. corpúsculo paranuclear no sangue de *Leptodactylus* e *Bufo* do Brasil. I - Desenvolvimento e citoquímica. *Mem. Inst. Oswaldo Cruz*, 70 (this issue).
- 24 — PESSÔA, S. B., 1970, Formas evolutivas do *Hepatozoon leptodactyli* (Lesage 1908) na sanguessuga *Haementeria lutzi* Pinto, 1920. *Rev. Goiania Med.*, 16:35-39.
- 25 — PINTO, C., 1925, Protozoários observados no Brasil. *Mem. Inst. Oswaldo Cruz*, 18:211-302.
- 26 — WENYON, C. W., 1965, Protozoology vol. II Bailliére, Tindall & Cassel. Ltd. London: 1563 pp.

ESTAMPA I

Figs. 1 - 8: Photomicrographs of *Hepatozoon leptodactyli* (Lesage, 1908) Pessoa, 1970, in the blood of *Leptodactylus ocellatus*. May-Grünwald-Giemsa stain. $\times 1.000$.

Fig. 1: Two intraerythrocytic forms with different types of nucleus in the same cell in which the nucleus was displaced for one pole.

Fig. 2: In this case the hemogregarine nucleus is granular.

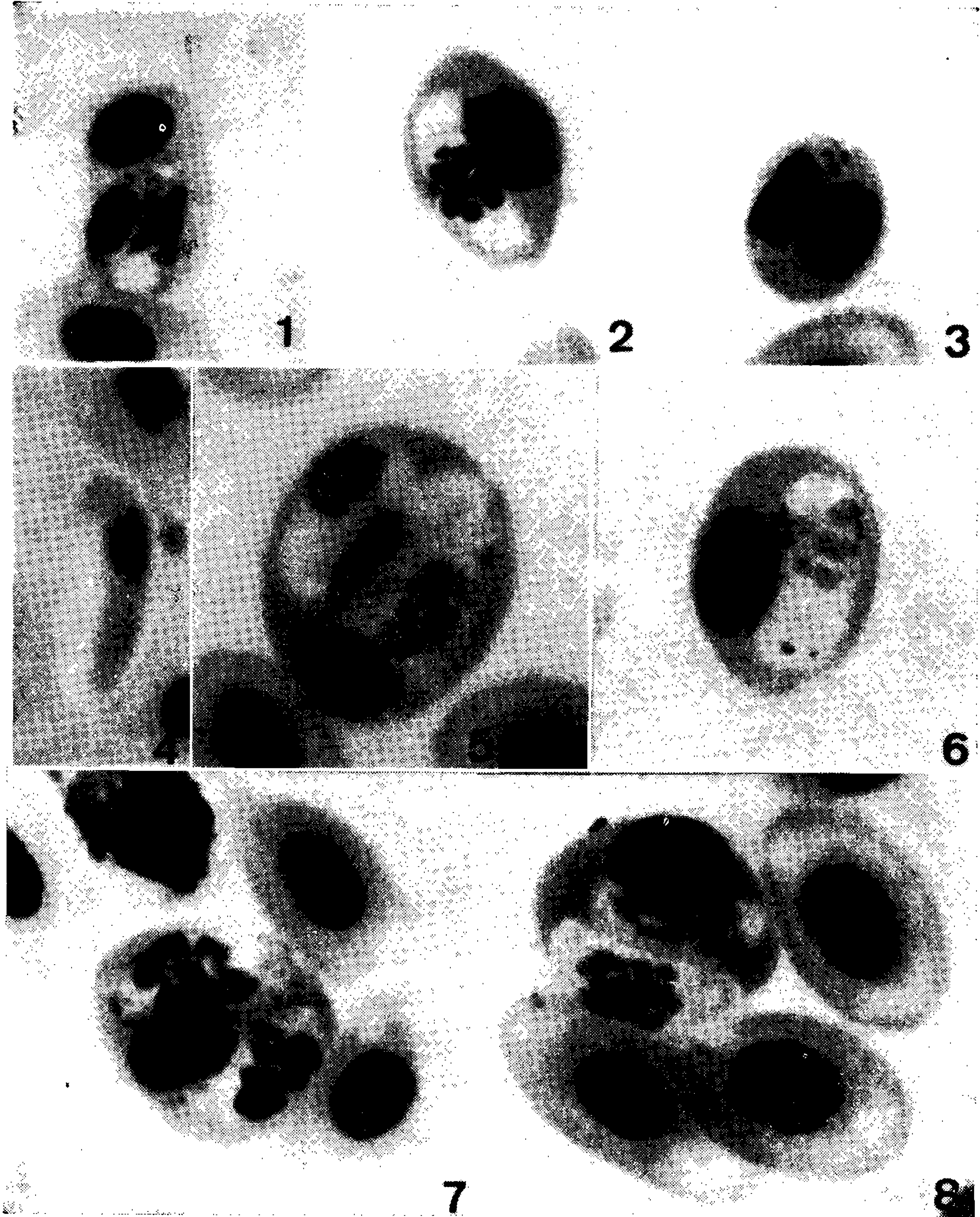
Fig. 3: Inclusions in the cytoplasm of the hemogregarine. The erythrocyte is small and the nucleus hypertrophied.

Fig. 4: A capsulated form free in the plasm.

Fig. 5: A very hypertrophied erythrocyte with three hemogregarines presenting different types of nucleus.

Fig. 6: A form showing the alteration of the erythrocyte nucleus in the contact zone with the hemogregarine.

Figs. 7 - 8: The erythrocytes are parasited by two hemogregarine.



Costa, Pessoa, Pereira & Colombo: *Hepatozoon leptodactyli*

ESTAMPA II

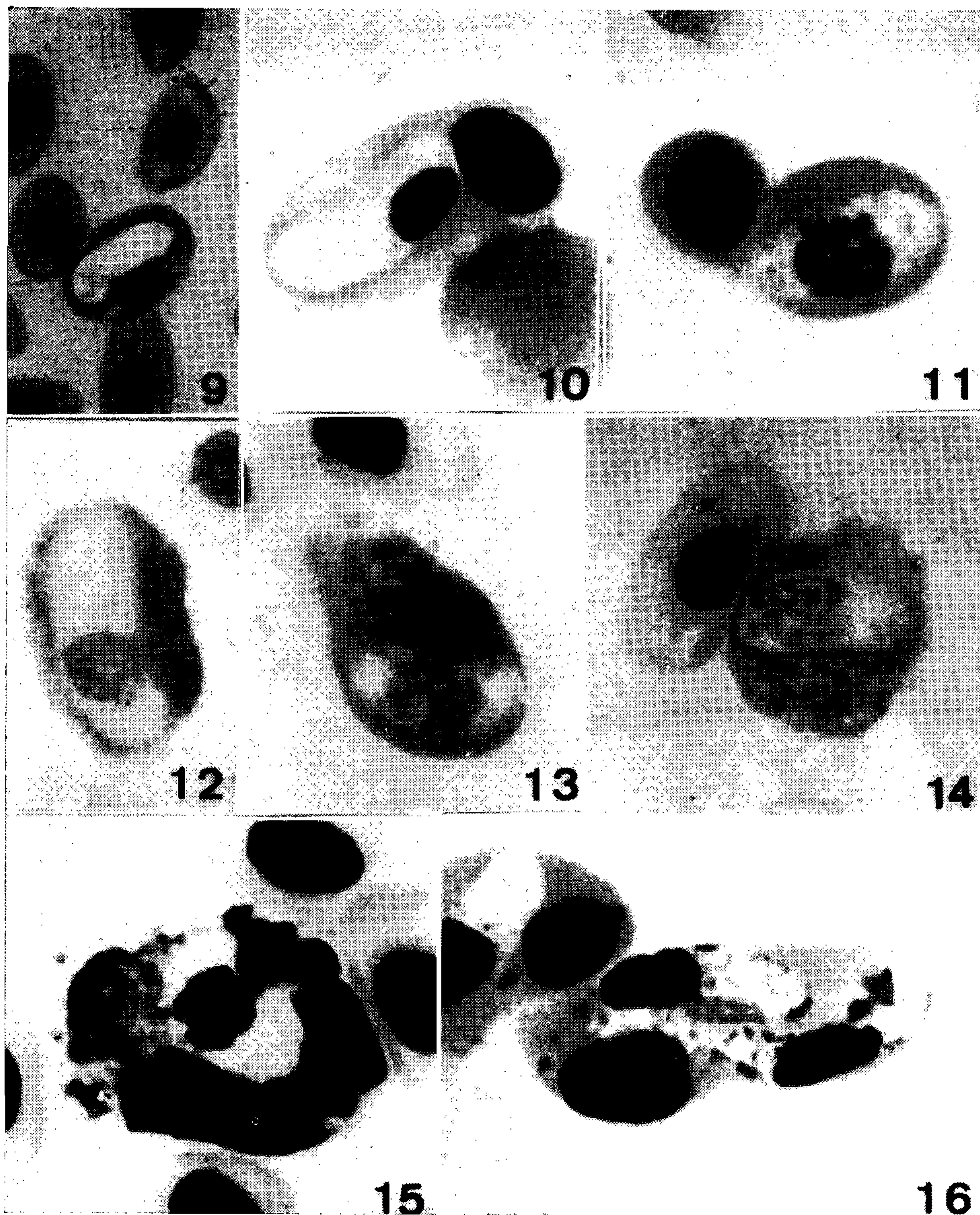
Figs. 9 - 16: Photomicrographs of *Hepatozoon leptodactyli* (Lesage, 1908) Pessoa, 1970, in the blood of *Leptodactylus ocellatus*. May-Grünwald-Giemsa stain.

Fig. 9: A capsule without the parasite. $\times 920$.

Figs. 10 - 11: Two cases in which the nucleus of the red cell is displaced and very hypertrophied. $\times 1.000$.

Figs. 12 - 15: White cells parasited by hemogregarines. $\times 1.000$.

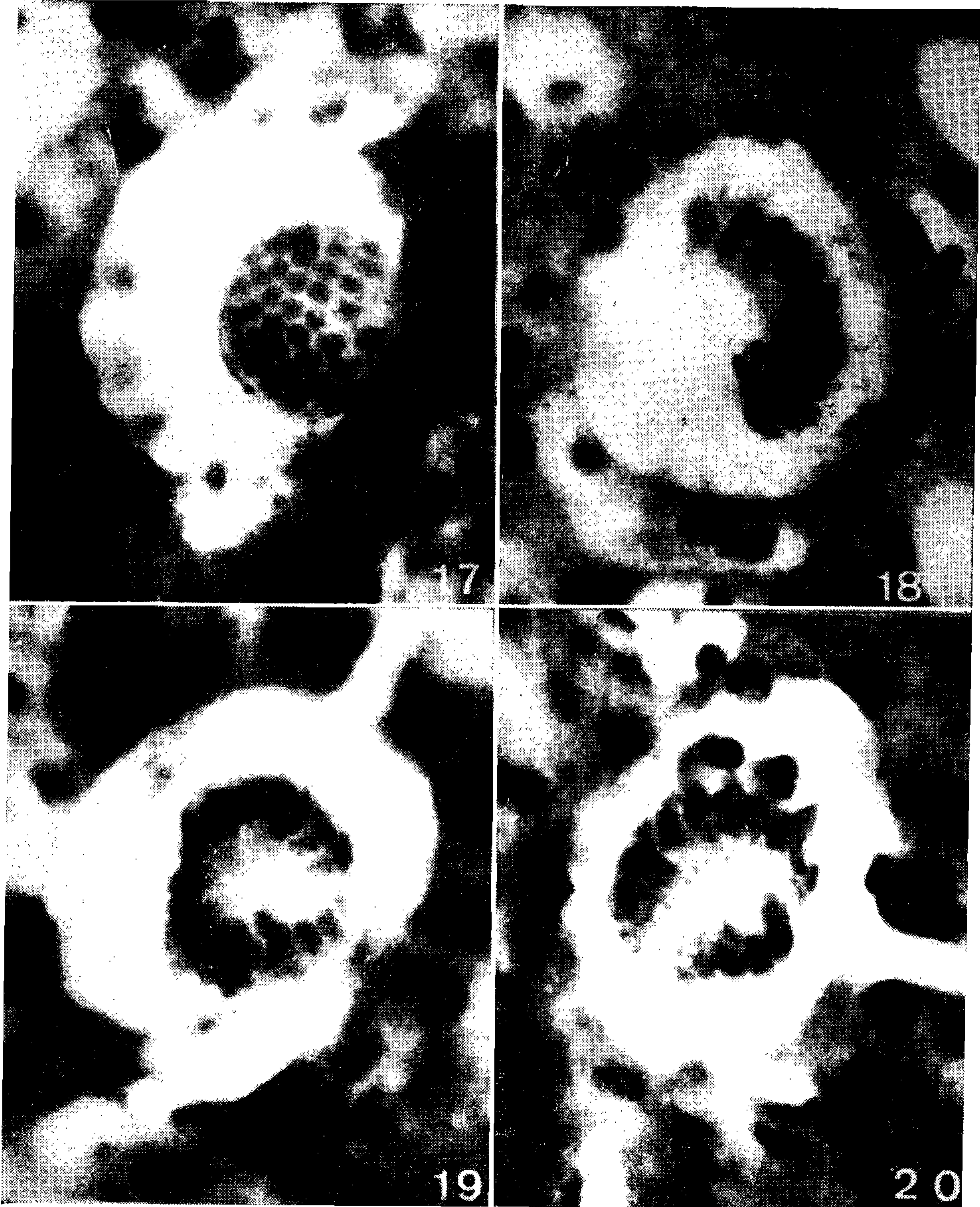
Fig. 16: Showing the destructive action of two hemogregarines. $\times 1.000$.



Costa, Pessoa, Pereira & Colombo: *Hepatozoon leptodactyli*

ESTAMPA III

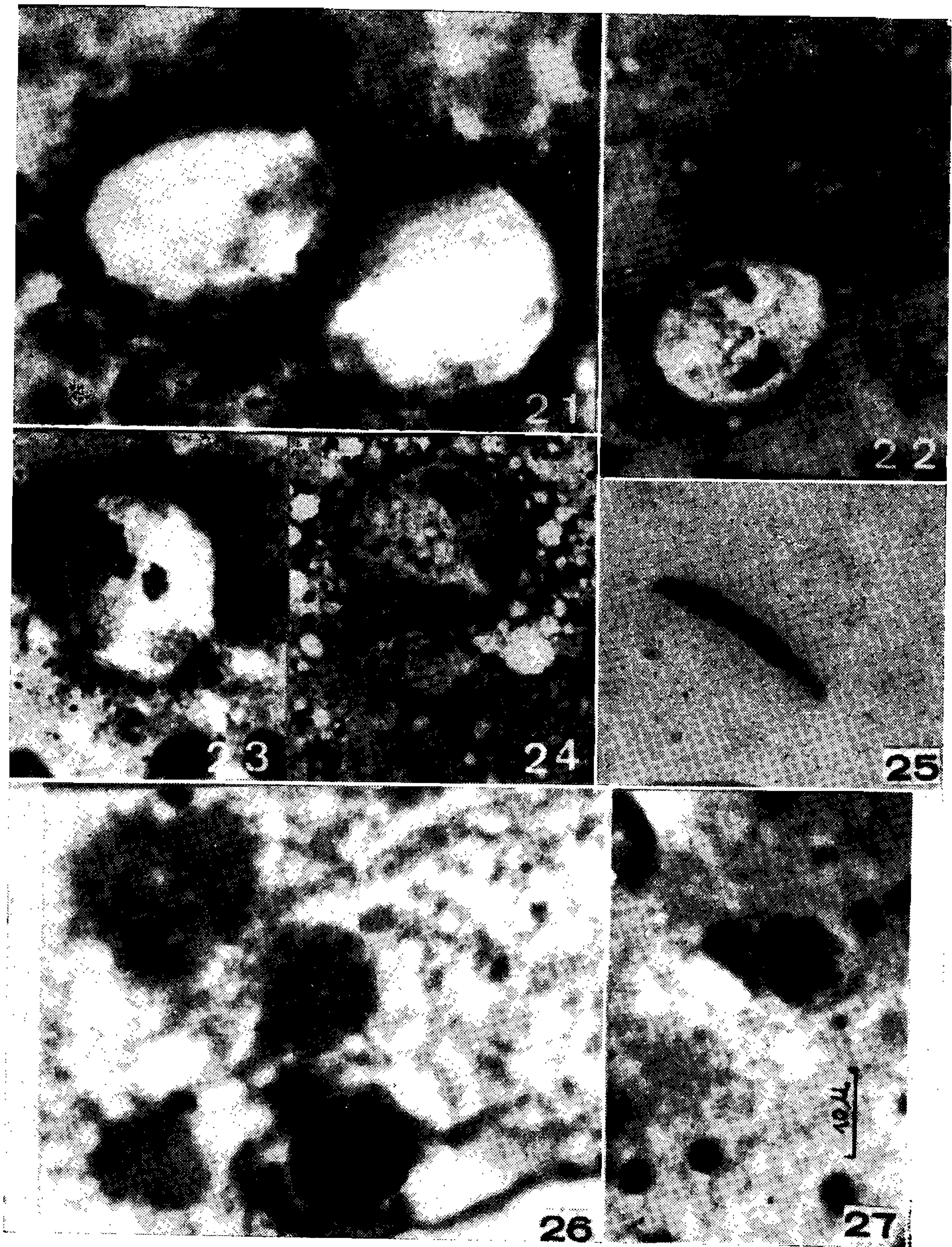
Figs. 17 - 20: Young and mature schizonts of *H. leptodactyli* from liver of *L. ocellatus*. Haematoxylin stain.



Costa, Pessoa, Pereira & Colombo: *Hepatozoon leptodactyli*

ESTAMPA IV

- Figs. 21 - 24: Schizonts of *H. leptodactyli* from liver of *L. pentadactylus* showing the second type of Schizogony described by Cunha & Muniz (1927) for the hemogregarine of *L. ocellatus*.
- Fig. 25: Extracellular stage of *H. leptodactyli* from blood of *L. pentadactylus*.
- Figs. 26 - 27: Schizonts of *H. leptodactyli* from Central Nervous System of *L. ocellatus*. PAS stained method. Fig. 26. Schizont in brain capillary.



Costa, Pessoa, Pereira & Colombo: *Hepatozoon leptodactyli*

ESTAMPA V

Figs. 28 - 29: Sporocystes and Sporozoites of *H. leptodactyli* of experimentally infected *Haementeria lutzi*.

