

DENGUE VIRUS INFECTION OF THE CENTRAL NERVOUS SYSTEM (CNS): A CASE REPORT FROM BRAZIL

RMR Nogueira^{1*}, AMB Filippis¹, JMO Coelho², PC Sequeira¹, HG Schatzmayr¹, FG Paiva³, AMO Ramos⁴ and MP Miagostovich¹

¹Departamento de Virologia/IOC/FIOCRUZ; ²Centro de Pesquisas Hospital Evandro Chagas-CPqHEC, FIOCRUZ. Av Brasil, 4365, Rio de Janeiro/RJ, CEP 21045-900; ³Laboratório Central (LACEN), Natal/Rio Grande do Norte; ⁴Setor de Verificação de Óbitos, RN

Abstract. Dengue infection that is accompanied by unusual complications has been described in Brazil. We report on the presence of dengue virus in the central nervous system (CNS) of a patient who died in 1998 in Rio Grande do Norte, northeast Brazil. DEN-2 viruses were isolated from the brain liver, and lymphnode tissue of a 67-year-old man whose signs and symptoms were those of dengue infection and a secondary immune response. A postmortem revealed nose bleeds a liver that was brownish with yellow areas, and pulmonary and cerebrae congestion. Immunoperoxidase staining showed a dengue antigen-specific positive reaction in the gray matter cells of the cerebrall cortex; a granular citoplasmatic reaction was seen in the neurons. Dengue infection should always be considered as a cause encephalitis in tropical countries, especially in those where the disease is endemic.

INTRODUCTION

Dengue fever is caused by one of four closely related dengue virus serotypes (types 1 to 4). In most cases infection with any of the serotypes results in a mild self-limiting febrile illness. However, in some dengue infections hemorrhagic manifestations and signs of circulatory failure occur, leading to sudden and often fatal hypovolemic shock - the dengue hemorrhagic fever/dengue shock syndrome (DHF/DSS) (WHO, 1986).

Neurological disorders, cardiac abnormalities and hepatitis have been reported as unusual complications of both classic dengue infection and the hemorrhagic forms; in recent years growing numbers of dengue cases have been associated with these complications (Nimmannitya *et al*, 1987; George *et al*, 1989; Patey *et al*, 1993; Thisyakorn and Thisyakorn, 1994; Lum *et al*, 1996; Row *et al*, 1996).

The neurological manifestations have been shown to be secondary to vasculitis, with resultant fluid extravasion, cerebral edema, hypoperfusion, hyponatremia and hepatic and/

or renal failure. The lack of direct evidence of dengue virus invasion of and replication in the brain justifies using the term *encephalopathy*, rather than encephalitis, to describe the neuropathology associated with dengue infections (Nimmannitya *et al*, 1987). However, cases of true dengue encephalitis have recently been reported (Lum *et al*, 1996; Hommel *et al*, 1998; Ramos *et al*, 1998; Thisyakorn *et al*, 1999).

The introduction of DEN-1 and DEN-2 viruses in Brazil in 1986 and 1990 respectively resulted in high dengue virus activity, with approximately 2 million cases reported from 1986 to 2000. The co-circulation of DEN-1 and DEN-2 viruses in 25 of 27 Federative Units has changed the clinical profile of dengue infections in Brazil. Besides the increasing number of DHF/DSS, dengue infection with unusual manifestations have been observed (Souza *et al*, 1995; Vasconcelos *et al*, 1995; Cordeiro, 1997).

We report on the presence of dengue virus in the central nervous system (CNS) of a patient from the State of Rio Grande do Norte, in the northeast region of Brazil.

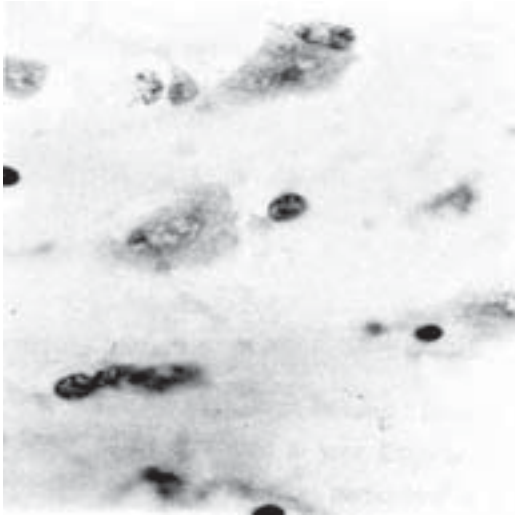


Fig 1—Immunoperoxidase stain showing a dengue antigen specific positive cytoplasmic reaction in cerebral cortical gray matter.

Case report

A 67-year-old man was examined as an outpatient on March 25th, 1998, and was found to have fever, exanthem, pruritus, vomiting, generalized pain, mainly in the abdominal and lumbar regions, and anorexia of 4 days' duration. A diagnosis of dengue was based on the clinical findings and epidemiological data.

The case was not considered severe enough to warrant admission to hospital; the patient was treated symptomatically and discharged. The patient died, 4 hours later, on his way back to the hospital, an autopsy was performed and general postmortem findings included evidence of nose bleeds, a brownish liver with yellow areas and lung congestion. The brain exhibited edema and congestion.

Samples of blood heart and other organ tissues were collected and sent to the Flavivirus Laboratory at the Oswaldo Cruz Institute (FIOCRUZ). Necropsy tissue was formalin-fixed and paraffin-embedded and subjected to histological and immunohistochemical studies.

Brain tissue sections were stained with hematoxylin eosin and showed edema and no infiltration of mononuclear cells. More data

concerning the microscopic findings were not available because the laboratory could analyse only limited amounts of tissue from each organ. The immunoperoxidase stain (VECTASTAIN ABC Kit, Vector Laboratories Inc, Burlingame, CA, USA) detected a dengue-antigen-specific positive reaction in cells of cerebral cortical gray matter; a granular and cytoplasmic reaction was observed in neurons (Fig 1).

DEN-2 virus was isolated from a 10% suspension of ground brain, liver and lymphnode tissues in Leibovitz medium, inoculated into *Aedes albopictus* (C6/36) cells adapted for 34.5°C and typed by using specific monoclonal antibodies (Gubler *et al*, 1984). No virus was isolated from blood or from heart, spleen, lung or thymus tissue. DEN-2 virus RNA was amplified from ground brain tissue according to the procedure described by Lanciotti *et al* (1992).

Nucleotides from the E/NS1 junction (240 nt) were amplified using RT-PCR according to the method of Rico-Hesse *et al* (1997). The sequencing reaction was performed by using the Taq DyeDeoxy Terminator Cycle Sequencing Kit (Applied Biosystem, Inc, USA); cycle sequencing parameters were those given in the manufacturer's protocol. Analysis of deduced amino acid sequence revealed 98% similarity with Jamaica 1998 DEN-2 strain (GenBank Accession, no M32950). The average similarity of the detected strain and other DEN-2 Brazilian strains was 98% for both nucleic acid and amino acid sequences (data not shown).

Serum immunoenzymatic assay (Mac-Elisa and G-Elisa) results revealed no IgM titers and IgG specific dengue antibody titer of 1/640, suggesting a secondary immune response (Kuno *et al*, 1987; Miagostovich *et al*, 1999).

DISCUSSION

In Brazil, dengue with involvement of CNS was first observed in 1987 during an epidemic in the state of Rio de Janeiro, when five fatal dengue cases were reported (Chimelli

et al, 1990); in a retrospective study, the use of the immunohistochemical procedure confirmed dengue infection in three of these cases, showing dengue virus antigen in the CNS. Extended immunohistochemical studies performed in one case demonstrated infiltration of CD68+ macrophages after the breakdown of the blood-brain barrier, showing that virus-infected macrophages could be one of the pathways by which virus enters the brain (Miagostovich *et al*, 1997).

Further cases of dengue infection presenting with neurological manifestations, *eg* drowsiness, restless, mental disorders, convulsions, dizziness, depression and paralysis and with neurological sequelae, *eg* signs of Parkinson's disease and tetraplegia, have been reported from in Ceará and Recife (Vasconcelos *et al*, 1995; Cordeiro *et al*, 1997); those states are located in the northeast region, associated with more than 80% of dengue infection in the country, especially after 1994. The case reported on here occurred in Natal, the State capital; 35 of the city's 36 districts were infested by *Aedes aegypti* (house index of about 10%) in 1997. In the same year, the city was responsible for 56.5% of the reported cases (15,057) in the State and reported another case with CNS involvement during an epidemic peak in 1997 (Cunha *et al*, 1999).

The autopsy findings for our patient showed cerebral edema described previously as the predominant autopsy finding in dengue encephalopathy (Hommel *et al*, 1998). The rapid progression to death in one case in which dengue virus was isolated from the brain has been described (Janssen *et al*, 1999). As with our patient, the subject studied by Janssen *et al* (1999) appeared to have had a relatively benign disease and dengue virus infection was confirmed only by necropsy specimen.

Determining the presence of dengue antigen in brain tissue, particularly in neurons, astrocytes, microglia and endothelial capillary cells, by immunohistochemistry using antibody specific for dengue has been described previously (Ramos *et al*, 1998).

Although a secondary dengue infection could be more aggressive, resulting in DHF/DSS, the presence of the virus in the brain at such an early stage is probably the best argument in favor of a true encephalitis (Hommel *et al*, 1998); in addition Lum *et al* (1996) provided strong evidence that DEN-2 and DEN-3 viruses can cause dengue encephalitis in both primary and secondary infections. An association between the Southeast Asian genotype of DEN-2 viruses (Jamaica genotype) and the increased pathogenicity of dengue infection in the Americas has been suggested (Rico-Hesse *et al*, 1997).

Unfortunately, it was not possible to obtain the past history of the patient in relation to individual risk factors such as chronic disease, although his chronic alcoholic dependency was known.

The isolation of dengue viruses from CSF and brain in many cases in which encephalitis appears early in the course of disease suggests the breakdown of the blood-brain barrier and the direct invasion of the brain by viruses that induce cerebral damage (Lum *et al*, 1996; Hommel *et al*, 1998; Ramos *et al*, 1999).

Although more data, including laboratory results for the patient, were not available, we would like to emphasise that dengue infection should be considered in cases of encephalitis in the tropics, especially in those countries in which the disease is endemic a caution echoed by Hommel *et al* (1998).

ACKNOWLEDGEMENTS

The authors are thankful to Eliane Saraiva Machado de Araújo, José da Costa farias Filho and José de Carvalho Filho for their technical support.

This work was supported by grants from the Conselho Nacional de Desenvolvimento Científico e Tecnológico (CNPq) and the Oswaldo Cruz Foundation. RMRN, HGS and MPM were supported by fellowships from CNPq. Grant no. 400164-98-1.

REFERENCES

- Chimelli L, Dumas Hahn M, Barreto Neto M, Grandelle Ramos, Dias M, Gray F. Dengue: neuropathological findings in 5 fatal cases from Brazil. *Clin Neuropathol* 1990; 9: 157-62.
- Cordeiro MT. Dengue in the State of Pernambuco, Brazil: 1995-1997. Virological, clinical and epidemiological aspects. *Virus Rev Res* 1997; 2: 112-3.
- Cunha RV, Miagostovich MP, Schatzmayr HG, *et al.* Dengue epidemic in the State of Rio Grande do Norte, Brazil. *Trans R Soc Trop Med Hyg* 1999; 93: 247-9.
- George R, Geethan R, Foo LS, *et al.* Unusual clinical manifestations of dengue virus infection. *WHO Dengue Newsl* 1989; 14:40-1.
- Gubler DJ, Kuno G, Sather E, Valez M, Olivre A. Mosquito cell cultures and specific monoclonal antibodies in surveillance for dengue viruses. *Am J Trop Med Hyg* 1984; 33:158-65.
- Hommel D, Talarmin A, Deubel V, *et al.* Dengue encephalitis in French Guiana. *Res Virol* 1998; 149: 235-8.
- Janssen HLA, Bienfait HP, Lansen CL, *et al.* Fatal cerebral oedema associated with primary dengue infection. *J Infect* 1998; 36: 344-6.
- Kuno G, Gomez I, Gubler DJ. Detecting artificial anti-dengue IgM immune complexes using an enzyme - linked immunosorbent assay. *Am J Trop Med Hyg* 1987; 36: 153-9.
- Lanciotti RS, Calisher CH, Gubler DJ, Chang G-J, Vorndam V. Rapid detection and typing of dengue viruses from clinical samples by using reverse transcriptase-polymerase chain reaction. *J Clin Microbiol* 1992; 30: 545-51.
- Lum LCS, Lam SK, Choy YS, George R, Harun F. Dengue encephalitis: a true entity? *Am J Trop Med Hyg* 1996; 54: 256-9.
- Miagostovich MP, Ramos RG, Nicol, AF, *et al.* Retrospective study on dengue fatal cases. *Clin Neuropathol* 1997; 16: 204-8.
- Miagostovich MP, Nogueira RMR, Araújo ESM, dos Santos FB, Schatzmayr HG, Vorndam V. Evaluation of an IgG enzyme-linked immunosorbent assay for dengue diagnosis. *J Clin Virol* 1999; 14: 183-9.
- Nimmannitya S, Thisyakorn U, Hemsrichart V. Dengue haemorrhagic fever with unusual manifestations. *Southeast Asian J Trop Med Public Health* 1987; 18: 398-406.
- Patey O, Ollivaud L, Breuil J, Lafaix C. Unusual neurological manifestations occurring during dengue fever infection. *Am J Trop Med Hyg* 1993; 48: 793-802.
- Ramos C, Sánchez G, Pando RH, *et al.* Dengue virus in the brain of a fatal case of hemorrhagic dengue fever. *J Neurol* 1998; 4: 465-8.
- Row D, Weistein P, Murray-Smith S. Dengue fever with encephalopathy in Australia. *Am J Trop Med Hyg* 1996; 54: 253-5.
- Rico-Hesse R, Harrison LM, Salas RA, *et al.* Origins of dengue type 2 viruses associated with increased pathogenicity in the America. *Virology* 1997; 230: 652-8.
- Souza RW, Cunha RV, Miagostovich MP, *et al.* An outbreak of dengue virus infection in the state of Ceará, Brazil. *Mem Inst Oswaldo Cruz* 1995; 90: 345-6.
- Thisyakorn U, Thisyakorn C. Dengue infection with unusual manifestations. *J Med Assoc Thai* 1994; 77: 410-3.
- Thisyakorn U, Thisyakorn C, Limpitikul W, Nisalak A. Dengue infection with central nervous system manifestations. *Southeast Asian J Trop Med Public Health* 1999; 30: 504-6.
- Vasconcelos PF, Menezes DB, Melo LP, *et al.* A large epidemic of dengue fever with dengue hemorrhagic cases in Cear State, Brazil, 1994. *Rev Inst Med Trop São Paulo* 1995; 37: 11-7.
- WHO. Dengue haemorrhagic fever: Diagnosis, treatment and control. Geneva: World Health Organization, 1986.