

## *Sporothrix schenckii* and Sporotrichosis

Mônica Bastos de Lima Barros<sup>1\*</sup> Rodrigo de Almeida Paes,<sup>2</sup> and Armando Oliveira Schubach<sup>2</sup>

National School of Public Health<sup>1</sup> and Evandro Chagas Clinical Research Institute,<sup>2</sup> Fiocruz, Rio de Janeiro, Brazil

<b>INTRODUCTION</b> .....	633
<b>HISTORY</b> .....	634
<b>TAXONOMIC STUDIES</b> .....	634
<b>SPOROTHRIX CELL BIOLOGY</b> .....	635
Morphology .....	635
Cell Wall .....	636
<b>S. SCHENCKII GENETIC MATERIAL</b> .....	636
<b>S. SCHENCKII PHYSIOLOGY</b> .....	636
<b>S. SCHENCKII ECOLOGY</b> .....	637
<b>PUTATIVE S. SCHENCKII VIRULENCE FACTORS</b> .....	637
Thermotolerance .....	638
Melanin .....	638
Adhesion .....	638
Ergosterol Peroxide .....	639
Proteins Related to Virulence .....	639
<b>IMMUNE RESPONSE IN SPOROTRICHOSIS</b> .....	639
Innate Response .....	639
Cellular Response .....	639
Humoral Response .....	640
<b>SPOROTRICHOSIS DIAGNOSIS</b> .....	640
Direct Examination .....	640
Histopathological Examination .....	641
Culture .....	641
Molecular Detection .....	641
Sporotrichin Skin Test .....	642
Antibody Detection .....	642
<b>EPIDEMIOLOGY</b> .....	643
Geographic Distribution .....	643
Distribution by Age and Gender .....	643
Transmission and Sources of Infection .....	643
Zoonotic Transmission .....	644
<b>PATHOGENESIS AND CLINICAL FORMS</b> .....	645
Human Disease .....	645
Cutaneous forms .....	645
Mucosal form .....	646
Extracutaneous form .....	646
Associated signs and symptoms .....	646
Differential diagnosis .....	646
Feline Disease .....	646
<b>TREATMENT</b> .....	647
Antifungal Susceptibility Tests .....	647
<b>PREVENTION</b> .....	649
<b>ACKNOWLEDGMENTS</b> .....	649
<b>REFERENCES</b> .....	649

### INTRODUCTION

Sporotrichosis, caused by the dimorphic fungus *Sporothrix schenckii*, is currently distributed throughout the world, especially in tropical and subtropical zones. Infection generally occurs by traumatic inoculation of soil, plants, and organic

matter contaminated with the fungus. Certain leisure and occupational activities, such as floriculture, agriculture, mining, and wood exploitation, are traditionally associated with the mycosis. Zoonotic transmission has been described in isolated cases or in small outbreaks. At present, veterinarians, technicians, caretakers, and owners of cats with sporotrichosis are regarded as a new risk category for the acquisition of the disease. The lesions are usually restricted to the skin, subcutaneous cellular tissue, and adjacent lymphatic vessels. Eventually, this fungus can disseminate to other organs, and alternatively, on rare occasions, inhalation of conidia may lead to a

\* Corresponding author. Mailing address: Fundação Oswaldo Cruz/Fiocruz, Av. Brasil, 4365, Manguinhos, Rio de Janeiro CEP 22045-900, Brazil. Phone: 55 21 2598 2518. Fax: 55 21 3415 2086. E-mail: mblbarros@fiocruz.br.

systemic disease. Several factors, such as inoculum load, immune status of the host, virulence of the inoculated strain, and depth of traumatic inoculation, influence the different clinical forms of sporotrichosis. The gold standard for sporotrichosis detection is culture; however, serological, histopathological, and molecular approaches have been recently adopted as auxiliary tools for the diagnosis of this mycotic infection.

## HISTORY

*Sporothrix schenckii* was isolated for the first time in 1896 by Benjamin Schenck, a medical student at the Johns Hopkins Hospital in Baltimore, MD, from a 36-year-old male patient presenting lesions on the right hand and arm. This isolate, from the patient abscess, was then studied by the mycologist Erwin Smith, who concluded that the fungus belonged to the genus *Sporotrichum* (217). Previously, Linck in 1809 and Lutz in 1889 referred to some possible sporotrichosis cases, but the isolation of the fungus by these authors for case definitions was not possible (126). The second undeniable sporotrichosis case was described in 1900 by Hektoen and Perkins, also in the United States (Chicago, IL). This was the case of a boy who suffered an injury with a hammer hitting his finger, with the lesion presenting spontaneous regression. These investigators gave the sporotrichosis agent its current denomination, *Sporothrix schenckii* (95). Later, this fungus was erroneously included in the genus *Sporotrichum*, which comprises basidiomycetous fungi which are neither dimorphic nor pathogenic for humans or other animals (216). This erroneous nomenclature remained until 1962, when Carmichael recognized differences in the conidiations of members of the genus *Sporotrichum* and isolates from sporotrichosis cases (37).

In 1903, Sabouraud suggested to Beurmann and Gougerot the use of potassium iodine for the treatment of sporotrichosis, which was a common disease in France during the beginning of the 20th century (126). This has hitherto been a satisfactory therapy for sporotrichosis, although no randomized, double-blind, placebo-controlled trials have ever been conducted (267).

The first reported case of natural animal infection was described in 1907 by Lutz and Splendore in rats from Brazil (141). The possibility of human infection by bites from these rats was considered (186). Also in Brazil, in 1908, Splendore reported the detection of asteroid bodies around *Sporothrix* yeast cells, which offer a very useful tool for sporotrichosis diagnosis in histological examinations (126, 196).

## TAXONOMIC STUDIES

*Sporothrix schenckii* belongs to the kingdom Fungi and is a eukaryotic organism that is without mobility and heterotrophic and presents chitin on its cell wall. For several years, this fungus was included in division *Eumycota*, subdivision *Deuteromycotina*, class *Hyphomycetes*, order *Moniliales*, and family *Moniliaceae* (128). After a substantial fungal taxonomy revision by Guarro and coworkers, this fungus was characterized in division *Ascomycota*, class *Pyrenomycetes*, order *Ophiostomatales*, and family *Ophiostomataceae* (84).

The sexual form of *S. schenckii* is as yet unknown. However, there is substantial molecular evidence that this fungus undergoes recombination in nature (163). Nevertheless, some studies imply that *S. schenckii* in an ascomycete, since it presents a simple septum, with Woronin bodies (237) and three chitin synthase genes (44).

Molecular analyses of the 18S region of the ribosomal DNA indicate that the sexual form of *S. schenckii* could be *Ophiostoma stenoceras* (22). On the other hand, morphological and physiological studies exhibit consistent differences between these two species. *O. stenoceras* is unable to produce dematiaceous conidia, as does *S. schenckii*. Also, *S. schenckii* does not produce perithecium on malt, rice, or potato media, as is observed for isolates of *O. stenoceras* (60, 181). Differences are also apparent when these species are inoculated in mice. *S. schenckii* can be found in several tissues from all infected mice after intravenous inoculation, and *O. stenoceras* is detected in certain organs from some infected animals (59). These observations lead to the conclusion that the *O. stenoceras* anamorph and *S. schenckii* are different species. Meanwhile, other molecular studies (56, 97), together with work by Berbee and Taylor (22), reinforce that the *S. schenckii* teleomorph is classified in the genus *Ophiostoma*. Berbee and Taylor highlight that *S. schenckii* belongs to the pyrenomycete lineage, lacking forcible ascospore discharge (22).

Recently, Marimon and coworkers (150), on the basis of phenotypic and genotypic analyses, suggested that *S. schenckii* should not be considered the only species that causes sporotrichosis, and based on macroscopic characteristics, sucrose and raffinose assimilation, ability to grow at 37°C, and the nuclear calmodulin gene sequence, they described four new species in the *Sporothrix* complex: (i) *S. globosa*, a fungus distributed worldwide (145, 180); (ii) *S. brasiliensis*, the species related to the zoonotic epidemic of sporotrichosis in Rio de Janeiro, Brazil (150, 179); (iii) *S. mexicana*, limited to Mexico (150); and (iv) *S. luriei*, formerly *S. schenckii* var. *luriei* (151), differing from *S. schenckii* mainly in the tissue form by the production of large, often septate budding cells unable to assimilate creatinine or creatine (53). On the other hand, other authors support its separation by rRNA internal transcribed spacer (ITS) sequence data (54). Another species, *S. cyane-scens* has been isolated from blood and skin samples from human patients, but pathogenicity studies conclude that, although this fungus can grow at 37°C, it is avirulent (233). Figure 1 presents a key to differentiate species within the *S. schenckii* complex (151).

Recently, de Meyer and collaborators (56) described three other environmental *Sporothrix* species, *S. stylites*, *S. humicola*, and *S. lignivora*. The first two species differ from *S. schenckii* by the inability to produce melanized conidia and the consequent nondarkening of colonies with age. *S. lignivora* has distinctive conidia that do not match in size and shape those of other *Sporothrix* or *Ophiostoma* species. It is interesting to note that isolates classified as *S. humicola* were previously referred to as environmental isolates of *S. schenckii*. In their study, the authors concluded that  $\beta$ -tubulin sequence analysis is strongly recommended for taxonomic studies of *Sporothrix* species isolated from the environment.

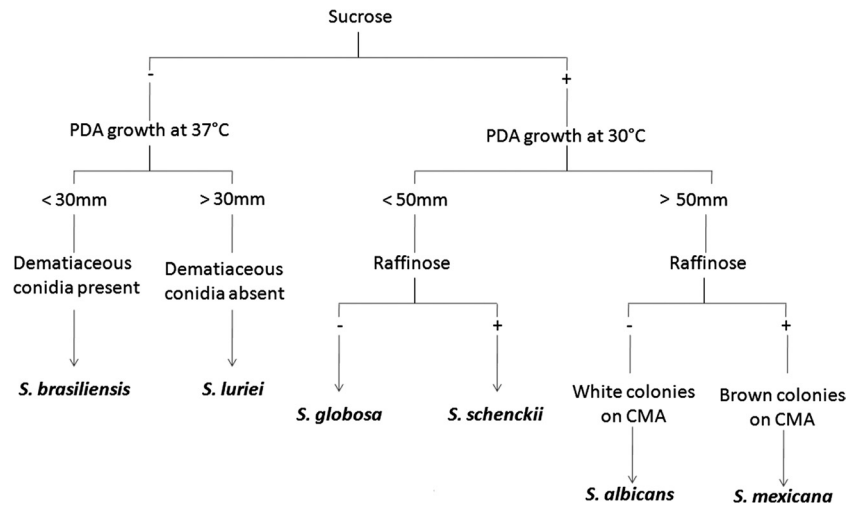


FIG. 1. Identification key for *Sporothrix* species of clinical interest, based on morphological and phenotypic tests described by Marimon and collaborators (152). PDA, potato dextrose agar; CMA, corn meal agar.

**SPOROTHRIX CELL BIOLOGY**

**Morphology**

*Sporothrix schenckii* is a dimorphic fungus. In its saprophytic stage or when cultured at 25°C, it assumes a filamentous form, composed of hyaline, septate hyphae 1 to 2 µm wide, with conidiogenous cells arising from undifferentiated hyphae forming conidia in groups on small, clustered denticles. These one-celled conidia are tear shaped to clavate (53) and do not yield chains (233). Often, hyaline or brown thick-walled conidia arise beside the hyphae. The dark cell walls of the conidia distinguish *S. schenckii* from other, nonpathogenic *Sporothrix* species (56, 242). Macroscopically, filamentous colonies in media such as malt extract agar or potato dextrose agar (Fig. 2) are often smooth and wrinkled, white to creamy at first and then turning brown to black after a few days (126, 170, 196). Some strains, however, have the ability to form dark colonies from the beginning of growth (5). The *S. schenckii* colonies never become cottony or floccose (126).

This fungus is evident in both human and animal tissues as budding yeasts. Yeastlike cells can be observed in various sizes and shapes. They may be round to oval, with 2- to 6-µm diameters, and usually have elongated, cigar-shaped buds on a narrow base. Macroscopically, yeast colonies (Fig. 2) are smooth, tan, or cream colored (130). Some molecular aspects implicated in proliferation and maintenance of this morphological form of *S. schenckii* involve calcium/calmodulin-dependent protein kinases (260) and a signaling pathway involving the interaction between a cytosolic phospholipase and protein G. Studies have proven that this pathway is necessary for the reentry of *S. schenckii* yeast cells into the budding cycle, suggesting its function in the control of dimorphism in this fungus and for the maintenance of the yeast form (259).

The transition from mold to yeast form in *S. schenckii* can be attained by culturing mycelia or conidia on rich culture media such as brain heart infusion agar at 35 to 37°C (170). Some strains, especially those related to the *S. globosa* species, may

require lower conversion temperatures, since they do not grow well at 37°C (150). Although rich media are required for the mycelium-to-yeast transition, *S. schenckii* yeast cells can be maintained at 37°C in other media, such as Sabouraud dextrose agar. This transition process also occurs after patients are infected with filamentous *S. schenckii*. Morphological transformation at the ultrastructural level occurs by direct formation of budlike structures at the tips and along the hyphae together with oidial cell formation after septation of the hyphae, without conspicuous alterations of the cytoplasmic content of parent mycelial cell. There is no direct budding of yeast from conidiospores (77).

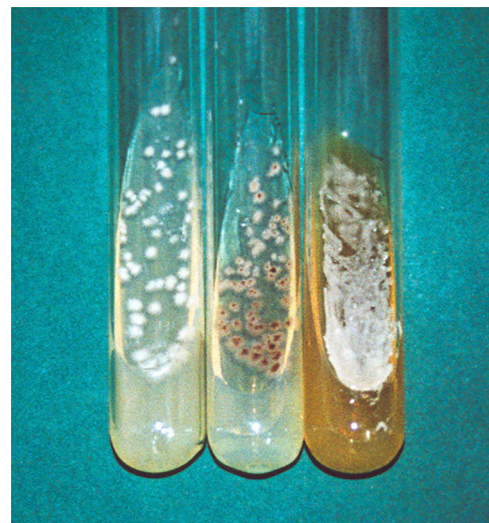

FIG. 2. Cultures of pus from lesions of *S. schenckii*-infected patients. Most strains become visible after 4 days of growth on Sabouraud dextrose agar, presenting no visible dark pigment at this stage (tube at left), whereas others are melanized since the beginning of growth (tube at center). When transferred to brain heart infusion agar and cultured at 37°C, strains undergo dimorphism, presenting creamy white to tan yeast colonies after 7 days of growth (tube at right).

The beginning of the yeast-to-mycelium transition in *S. schenckii* is a process regulated by calcium, which induces both RNA and protein synthesis on the yeast cell (199). A prerequisite for this transition process is a nuclear division; afterwards, a germ tube is originated from the parental yeast cell and a septum is formed at mother cell-germ tube formation (25). It is interesting to note that yeast cells can be maintained at 25°C if cultured in liquid media with glucose and with the pH around 7.2 (195, 260).

### Cell Wall

Like other fungi, *S. schenckii* has a cell wall surrounding the plasma membrane in both the mycelial and yeast forms. There are characteristic differences in cell wall thickness between conidia, yeast forms, and filaments, as well variations in plasma membrane invaginations among these three morphological forms of the fungus. It has been shown by freeze fracturing studies that in conidia invaginations are short and abundant and in yeast forms they are scarce and longer, while the plasma membrane of the *S. schenckii* hyphae is smooth, without invaginations (244).

The fungal cell wall is rigid as well as complex, and recently it has been shown that *S. schenckii* produces vesicles that are probably related to the transfer of periplasmic molecules and pigment-like structures from the plasma membrane to the extracellular space, since in contrast to the case for prokaryotic organisms, in eukaryotic cells there is vesicular traffic of molecules to the plasma membrane (3, 197).

The chemical structures of fungal cell wall polysaccharides and glycoproteins have been studied basically because of the knowledge of the antigenic structures of human pathogens (193). A peptide-rhamnomannan was isolated from the yeast *S. schenckii* cell wall, where there were the polysaccharides D-mannose (50%) and L-rhamnose (33%), small amounts of galactose (1%), and about 16% peptides (138). Comparative studies of mycelial and yeast *S. schenckii* cell walls showed little difference in the glycosidic components. The cell wall composition of the mycelial phase included large amounts of lipids and protein and a lower concentration of mannose (193). The cell wall composition in *S. schenckii* conidial cells can also be affected by the time of culture, with a decrease in the rhamnose molar ratio and an increase in the mannose molar ratio (67).

The yeast cell wall of *S. schenckii* also contain granules of melanin (250) and proteins involved in adherence (135, 206), which contribute to fungal virulence. Of particular interest is a glycoprotein of 70 kDa isolated from the cell wall of the *S. schenckii* yeast phase. The purified glycopeptide has a pI of 4.1, and about 5.7% of its molecular mass is composed of N-linked glycans, with no evidence for O-linked oligosaccharides in this molecule. This glycoprotein has a uniform distribution on the fungal cell surface and participates in adhesion to the dermal extracellular matrix (206).

### S. SCHENCKII GENETIC MATERIAL

Little is known about the *S. schenckii* genomic composition because this fungus is not amenable to genetic analysis based on meiotic segregation (256). Studies on the genomic DNA base composition rendered an average guanine and cytosine

content of about 54.7 mol%, with the DNA showing a low degree of hybridization with *O. stenoceras* DNA, supporting the supposition that this fungus does not represent the sexual state of *S. schenckii*. However, 75% hybridization was observed with *Ophiostoma minus* DNA (159). More recently, Tateishi and coworkers (249), karyotyping eight strains isolated from patients in Japan, concluded that *S. schenckii* possesses six to eight chromosomes of 460 to 6,200 kb, with a total genome size of approximately 28 Mbp. Another study with strains from a different geographical origin predicted a 45-Mbp genome size for *S. schenckii* (256). Perhaps these differences are related to either the different species recently described (150) or to underestimations in the methods adopted for genome size determination. Also, it has been reported that *S. schenckii* is a diploid organism, bearing around 50 fg DNA per cell, in both the filamentous and yeast phases. On the other hand, aneuploidy, a state in which most of the chromosomes are disomic, cannot be excluded (256). It is interesting to note that diploidy is essential for thermal dimorphism in *Cryptococcus neoformans*, and similarities in life cycle between this fungus and other dimorphic fungi, including *S. schenckii*, may occur (232).

Studies on identification, typing, and epidemiology of sporotrichosis are usually based on mitochondrial DNA (mtDNA) analysis of restriction length polymorphisms (RFLP) with the restriction enzyme HaeIII. Initially, 24 mtDNA types were cited (136), and more recently types 25 to 30 (168) and 31 to 32 (103) were introduced. These analyses have been adopted in several studies with *S. schenckii* strains from different geographical origins and also environmental isolates (13, 103, 104, 243, 266).

### S. SCHENCKII PHYSIOLOGY

Even though sporotrichosis is a disease distributed worldwide, there are only a few studies regarding the physiological characteristics of its agent. In general, the optimal temperature for *S. schenckii* growth is around 30 to 37°C, with growth of all strains being impeded at 40°C (79, 150). Although *S. schenckii* is able to grow at 35 to 37°C, some growth inhibition is observed compared to that at 28°C. Moreover, this inhibition appears to be geographically related (163).

Several carbohydrates can be assimilated by *S. schenckii*, such as glucose, fructose, mannose, and cellobiose (79, 200). However, there is some variability in assimilation of sucrose, arabinose, starch, raffinose, and ribitol (79, 150). Starch assimilation is also affected by fungal preservation under some storage methodologies, such as the Castellani method (160). The carbohydrate concentration available during *S. schenckii* growth modulates melanin synthesis by this fungus (Fig. 3), enhancing pigment formation in a glucose concentration-dependent manner (5). This fungus is not able to ferment any carbohydrate (53).

Some physiological differences between the two different *S. schenckii* morphologies may be observed. Mycelial-phase *S. schenckii* can grow well at pHs of around 3.0 to 11.5, but yeast cells can grow only within the pH range of 3.0 to 8.5. The yeast phase is also more osmotolerant (30%) than the mycelial phase (20%), as is true for halophila. The mycelial phase withstands growth in 7% NaCl, but the yeast-phase *S. schenckii* can grow well in 11% NaCl (79).

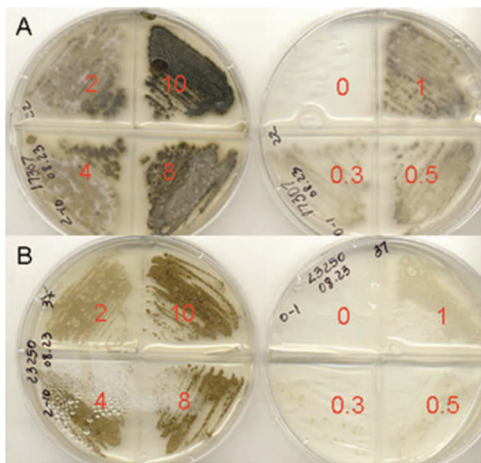


FIG. 3. Glucose concentration-dependent increase of melanin synthesis. The concentration of glucose (% wt/vol) in each culture is indicated by the numbers on the agar plates. *S. brasiliensis* strain 17307, grown at 22°C (A), and *S. schenckii* strain 23250, grown at 37°C (B), are representative isolates showing enhancement of melanization with increasing glucose amounts.

*S. schenckii* is able to split urea (79, 150, 233), perform reductive iron acquisition with secreted extracellular enzymes (270), and tolerate cycloheximide at 0.25% (150). Thiamine is required for fungal growth (60, 101).

### S. SCHENCKII ECOLOGY

*S. schenckii* often enters the host through traumatic implantation (126, 129, 170, 196). In nature, the fungus has been found to live as a saprophyte on living and decaying vegetation, animal excreta, and soil (118, 126, 156, 162). Organic material in soil is fundamental for mycelium development. The fungus thrives in soil plentiful in cellulose, with a pH range from 3.5 to 9.4 and a temperature of 31°C (177). The relative humidity cannot be below 92% (126).

It has been proposed that the armadillo *Dasypus septemcinctus* may be a reservoir of *S. schenckii*, since armadillo hunting was reported by several patients with sporotrichosis in Uruguay (143). In fact, this armadillo harbors *S. schenckii* in neither its intestine nor its epidermis, but the fungus can be found on the dry grass used by these animals for nesting (126). Here we find an apparent incongruity between the organisms needing high humidity for growth (126) yet being found on dry grass of armadillo nests. Probably these differences are geographically related, like growth inhibition at high temperatures (163). Moreover, we cannot discard the hypothesis that different species within the *S. schenckii* complex (150, 151) have different humidity requirements for growth.

There is another armadillo species, *Dasypus novemcinctus*, which is susceptible to systemic, fatal sporotrichosis (111, 264). Other animals related to *S. schenckii* transmission are parrots, rodents, cats, dogs, squirrels, horses, and birds (126, 212). Moreover, *S. schenckii* was also isolated from aquatic animals, primarily fish and dolphins (91, 164), as well as from insects that had been in direct contact with the fungus (126). Some authors have reported sporotrichosis cases due to mosquito bites (129).

It has been confirmed that *S. schenckii* is associated with plants. Sphagnum moss, rose thorns, and hay are especially recognized to harbor this pathogenic fungus (64, 71, 156). However, *S. schenckii* does not have the potential to be a plant pathogen, probably because extracts from several plants have antifungal activity against *S. schenckii* (81, 153, 154, 213). In fact, it has been described that when *S. schenckii* is inoculated in living or dead sphagnum moss, the fungal cell population proliferates in the moist dead plants but not in live moss (271), suggesting that plants have some mechanism to control *S. schenckii* overgrowth.

There has been some reports about *S. schenckii* isolation from food (1, 117). Nevertheless, this fungus does not appear to have the potential to cause food-borne infection (116).

There are some reports on the isolation of *S. schenckii* from environmental sources. Methods include direct isolation of the fungus by plating the supernatants of samples suspended in water or physiological saline solution with antibiotics in Mycosel agar medium or by inoculation of this suspension in susceptible mice, such as BALB/c, with further culture of spleens, livers, and lungs of the infected animals (60, 162). Direct isolation appears to be more effective to obtain *S. schenckii* from environmental samples. However, colonies obtained after mouse inoculation have been free of microbial contamination (162).

### PUTATIVE S. SCHENCKII VIRULENCE FACTORS

We can define a virulence factor as a feature of a microorganism that allows or enhances microbial growth in the host. To study and characterize these factors, is necessary compare the microbe-host interactions of an isolate that expresses the suspected factor and a mutant isolate that has lost the ability to express it, which can be attained by induced mutagenesis through molecular strategies. If differences in the infections caused by these different isolates are noted, it is imperative to make the mutant isolate recover the ability to express the studied factor and check whether or not the organism then regains the capacity to cause infection similar to that of the parental wild-type strain (100).

Discovery of the origin of microbial virulence has been the main goal of several studies. In general, the most accepted theory is that with microbial interactions with other organisms present in the natural habitat of the pathogen, the microorganisms acquire survival strategies tending to a higher virulence when they accidentally find an animal host. For instance, these microorganisms, in the mammalian host, usually have the ability to form biofilms and mechanisms to acquire iron and produce proteolytic enzymes that will lead to higher virulence (40).

Regarding this theory, Steenberg and coworkers (240) suggested that the origin of virulence in *S. schenckii* should be related to the intermicrobial interactions in its environment. The authors demonstrated that when ingested by *Acanthamoeba castellanii*, a soil amoeba, *S. schenckii* yeast cells are able to survive within the protozoan, kill it, and use it as nutrient. This behavior is not shared by pathogenic fungi that do not have the soil as habitat, such as *Candida albicans*, or by fungi that are not primarily pathogenic, such as *Saccharomyces cerevisiae*. On the other hand, other dimorphic fungal patho-




FIG. 4. Melanin ghosts of *S. schenckii* 18782 strain under several culture conditions. (A) Cultures on minimal medium at 25°C yield melanin ghosts only from dematiaceous conidia. (B) When L-DOPA is added to minimal medium, both hyphae and conidia are melanized. (C) Yeast *S. schenckii* cells can also produce melanin in culture medium free of phenolic compounds or when L-DOPA is added. Bars, 10  $\mu$ m.

gens, such as *Histoplasma capsulatum* and *Blastomyces dermatitidis* (240) as well as *Cryptococcus gattii*, a highly virulent yeast pathogen (148), have the same behavior as *S. schenckii* when in contact with *A. castellanii*.

Little is known about *S. schenckii* virulence factors due to the lack of studies in this field, in part because *S. schenckii* is not responsive to genetic analysis. However, some putative virulence factors have appeared from some investigations.

#### Thermotolerance

One of the putative *S. schenckii* virulence factors, which is also a virulence factor of other pathogenic fungi, is thermotolerance (40). In fact, isolates able to grow at 35°C but not at 37°C are incapable of causing lymphatic sporotrichosis and produce fixed cutaneous lesions instead. The fungi isolated from lymphatic, disseminated and extracutaneous lesions show tolerance and growth at 37°C (126). Results from a more recent study demonstrate that *S. schenckii* isolates from Colombia, where most patients are affected with fixed cutaneous sporotrichosis, exhibit high growth inhibition at 35 and 37°C, in contrast to isolates from Mexico and Guatemala, where lymphatic sporotrichosis prevails (163). In an *in vivo* mouse assay, it has been shown that if the mice have their feet warmed in cages with heat on the floor, progression of sporotrichosis is reduced compared to that in control infected mice maintained in regular cages. Isolates from pulmonary lesions, however, replicate regularly in both groups of mice (246).

#### Melanin

Both morphological stages of *S. schenckii* have the ability to synthesize melanin. This is an insoluble compound highly related to virulence in several fungi (106). Melanin production in *S. schenckii* dematiaceous conidia occurs through the 1,8-dihydroxynaphthalene (DHN) pentaketide pathway (202). Macroscopically, only the mycelial phase of the fungus is melanized. However, melanin production in yeast cells was demonstrated *in vitro* during infection (171). Recently, it has been demonstrated that *S. schenckii* can also produce melanin using phenolic compounds such as 3,4-dihydroxy-L-phenylalanine (L-DOPA) as a substrate both in filamentous and yeast forms (5). It is interesting to note that only conidia can be melanized by the DHN pathway, but if L-DOPA is present, hyphae can be melanized as well (Fig. 4).

Since *S. schenckii* is a soil-accommodated fungus that does

not require host parasitism to complete its life cycle, fungal melanization must be also important against unfavorable environmental conditions, since mycelium is the fungal form encountered in nature (171).

*In vitro* studies indicate that melanization in *S. schenckii* is controlled by several factors, such as temperature, pH, and nutrient conditions (5). Moreover, similar culture media from different suppliers can yield differences in melanization within a single *S. schenckii* strain (250). It has been shown that conidial melanization enhances *S. schenckii* resistance to macrophage phagocytosis, allowing the first steps of infection, since these structures usually are the fungal infective particles (202). Corroborating this hypothesis, it has been demonstrated by molecular typing of an *S. schenckii* strain isolated from a laboratory worker who had handled a pigmented strain and an albino strain of *S. schenckii* that the isolate from the patient had the same genotypic profile as the dematiaceous strain (48).

Melanization also has a role in the pathogenesis of cutaneous sporotrichosis, since pigmented isolates had a greater invasive ability than the albino mutant strain in an experimental rat model of sporotrichosis. The albino strain also was restricted to the core of the granuloma. In addition, the melanized strain promoted the formation of multifocal granulomas (145).

Some *S. schenckii* melanization *in vivo* has been previously described, such as a weak brown halo on the yeast *S. schenckii* cell wall when infected sporotrichosis tissues are stained with Fontana-Masson stain, a technique initially developed to demonstrate melanin in *C. neoformans* (127). This hypothesis has now been confirmed by detection of *Sporothrix* melanin ghosts in tissues from infected animals as well as by detection of antimelanin antibody in sera from patients with sporotrichosis (5, 171). Since melanization decreases the susceptibilities of *H. capsulatum* and *C. neoformans* to amphotericin B and caspofungin (261), melanin pigment in *S. schenckii* may hamper treatment in some sporotrichosis cases, especially in cases of extracutaneous disease or in patients infected with human immunodeficiency virus (HIV) (171). However, there have been no studies confirming this hypothesis.

#### Adhesion

Primary adhesion to endothelial and epithelial cells as well as on extracellular matrix components is essential to an effective invasion of host tissues by pathogens. Both conidia and yeast cells from *S. schenckii* are able to recognize three impor-

tant glycoproteins from the extracellular matrix: fibronectin, laminin, and type II collagen (134, 135). Some studies have demonstrated that the fungus has integrins or adhesin lectin-like molecules that recognize human fibronectin at several points on the molecule (135). The fibronectin adhesins are located on the surface of yeast cells, and their expression is related to fungal virulence (251). It is also known that these fibronectin receptors are different from laminin receptors (133). These receptors are present on both hyphae and fungal yeasts, although yeasts have a greater ability to bind to the extracellular matrix. The existence of these adhesins would favor adherence to host tissues and fungal dissemination throughout the body (133). Expression of these molecules in *S. schenckii* is probably related to virulence, since their preferential expression is in the parasitic rather than the saprophytic form of the fungus. Recently a 70-kDa glycoprotein from an *S. schenckii* isolate was described, and its participation in adhesion to the dermal extracellular matrix was demonstrated (206).

This fungal pathogen is also able to interact *in vitro* with human endothelial cells, which can internalize fungal yeast cells without injury or decreased viability. Moreover, the fungus can also cross the intercellular space. Both processes facilitate fungus bloodstream penetration and consequent hematogenous dissemination (69). Transendothelium migration occurs through a paracellular route involving extracellular matrix proteins, in a process mediated by transforming growth factor  $\beta$ 1 (TGF- $\beta$ 1) (70). Although the endothelial proteins responsible for this interaction have been characterized, fungal proteins needed for recognition of and adhesion to these cells are unknown, and their part in fungal virulence requires clarification.

#### Ergosterol Peroxide

Sgarbi and coworkers, analyzing lipids from *S. schenckii* through spectroscopic methods, have identified ergosterol peroxide from *S. schenckii* yeast cells. This compound can be converted to ergosterol when in contact with an enzyme extract from the fungus. The ergosterol peroxide, found in a pathogenic fungus for the first time in *S. schenckii*, is formed as a protective mechanism to evade reactive oxygen species during phagocytosis and may also represent a virulence factor. Apparently, however, survival of virulent *S. schenckii* yeast cells after phagocytosis of polymorphonuclear host cells relies on other detoxification strategies besides the one leading to ergosterol peroxide synthesis (32, 231).

#### Proteins Related to Virulence

Roles of diverse proteins in the virulence of different fungal pathogens have been described. For instance, the *Paracoccidioides brasiliensis* immunodominant antigen, a glycoprotein of 43 kDa, is the molecule responsible for laminin and fibronectin recognition and binding, which increase fungal virulence (158, 262). Calcium binding proteins are important in *H. capsulatum* virulence, enabling acquisition of this ion in environments with calcium limitations (265). A series of virulence-related proteins, such as different adhesins, have been described for *Aspergillus fumigatus*, including a 30-kDa hemolysin contain-

ing several proteases that favor pulmonary colonization and destruction of effective humoral molecules and a 350-kDa catalase needed for phagocytosis survival (131). However, the function of different *S. schenckii* proteins in virulence is still unclear. It is believed that acid phosphatases act on fungus-macrophage interactions, although no definite evidence to support this theory exists (100). Peptido-rhamnomannans of the fungal cell wall cause depression of immune response until the sixth week of infection and may act as a virulence factor (34). An antigenic preparation from the *S. schenckii* yeast phase shows proteolytic activity against different human IgG subclasses, suggesting that some secreted proteins may interfere with the immune response of the host (204). Due to the lack of information, characterization of *S. schenckii* proteins and determination of new virulence factors are imperative for a better understanding of sporotrichosis pathogenesis.

#### IMMUNE RESPONSE IN SPOROTRICHOSIS

The virulence of *S. schenckii* is one of the factors thought to play a role in the development of sporotrichosis (32), but there are discordant results concerning disease evolution in experimental sporotrichosis with *S. schenckii* clinical isolates from cutaneous and disseminated infection (29, 176), indicating that host immune responses also substantially participate in the progress of sporotrichosis (32).

The immunological mechanisms involved in prevention and control of *S. schenckii* infections are still not very well understood. However, they probably include both humoral and cellular responses (32, 33, 147), which appear to be triggered by distinct antigens. Surface cell antigens, especially some lipids, inhibit the phagocytosis process, while the humoral response is induced by secreted fungal proteins, the exoantigens, which are not involved in the cellular response (35). The innate immune response also plays a role in the pathogenesis of sporotrichosis (32).

#### Innate Response

A complement system can be activated by *S. schenckii*, especially the alternate pathway, although classic complement activation cannot be excluded. Complement activation may support fungal yeast cell phagocytosis by C3b component deposition on the fungal cell wall. The membrane attack complex also contribute to fungal cell lysis (230, 255).

Recent studies have emphasized the importance of Toll-like receptor 4 (TLR4) in sporotrichosis. TLR4, also designated CD284, is an important molecule involved in the activation of the innate immune system that, in sporotrichosis, is able to recognize molecules within a lipid extract from the yeast form of the fungus. This interaction leads to the induction of an oxidative burst against the fungus (32).

#### Cellular Response

Acquired immunity against the fungus requires the action of activated macrophages. They can be activated during sporotrichosis by CD4 T lymphocytes, which release gamma interferon (IFN- $\gamma$ ), a strong macrophage activator (247), and by other antigen-presenting cells, establishing a link between innate and

adaptive immune responses (32). Tumor necrosis factor alpha (TNF- $\alpha$ ), a cytokine that acts on activated macrophages to produce nitric oxide (35), an antioxidant product presenting a high cytotoxic effect against *S. schenckii* (66), is produced upon incipient and terminal infection, hopefully providing total resolution (147). Although nitric oxide is a fungicidal molecule, this compound may be implicated in immunosuppression *in vivo*, because high levels of TNF- $\alpha$  and NO released after yeast dissemination into the tissues lead to the induction of molecules suppressing T cell responses, such as interleukin10 (IL-10), FasL, and CTLA-4. This deleterious effect of NO occurs just upon initial infection, becoming crucial some time after fungal inoculation (68). In fact, TNF- $\alpha$  production drastically subsides at 4 to 6 weeks after experimental infection, inducing the fungus to reproduce and infect host tissues. The opposite situation occurs 2 months after infection, when the levels of IL-1 and TNF- $\alpha$  increase, favoring fungal elimination (36).

After the phagocytosis of *S. schenckii* conidia and yeast cells, monocytes and macrophages are also strongly induced to produce reactive oxygen species (202). These reactive species, especially superoxide anion and its oxidative reactive metabolites, which are also produced by neutrophils, are involved in fungistatic and fungicidal responses, and their absence is related to a higher lethality in mouse experimental infections (108). Therefore, the Th1 response is of great importance in sporotrichosis pathogenesis, acting as the key factor in controlling fungal infection and with its differential activation leading to varied clinical manifestations of the disease (258). Similar observations on the activation of Th1 cells have led to them being seen as being responsible for different clinical manifestations in other cutaneous infectious diseases, such as leishmaniasis (38).

### Humoral Response

The humoral immune response is driven by IL-4 produced by Th2 cells. In experimental sporotrichosis, IL-4 release is enhanced at 5 to 6 weeks after infection (147), suggesting the participation of the humoral immune response only in the advanced stages of sporotrichosis (32). Antibodies may have some effect on *S. schenckii* development, since a monoclonal antibody against a glycolipid antigen is able to hinder *S. schenckii* growth and differentiation *in vitro* (254). A monoclonal antibody against the 70-kDa adhesin is also protective in murine model of sporotrichosis (174). Nonetheless, little is known about antibodies elicited during the course of sporotrichosis. It has been described that mice infected with *S. schenckii* are able to produce specific IgG1 and IgG3 antibodies against a 70-kDa fungal protein during experimental infection, with these antibodies perhaps being related to fungal elimination in these organisms (173). During human sporotrichosis, our group has demonstrated the production of IgG, IgM, and IgA antibodies against mycelial-phase *S. schenckii* exoantigens. Nevertheless, since patients with different clinical forms of sporotrichosis produce similar amounts of these antibodies, we believe that the humoral immune response against proteins secreted by *S. schenckii* does not play a role in sporotrichosis pathogenesis (6).

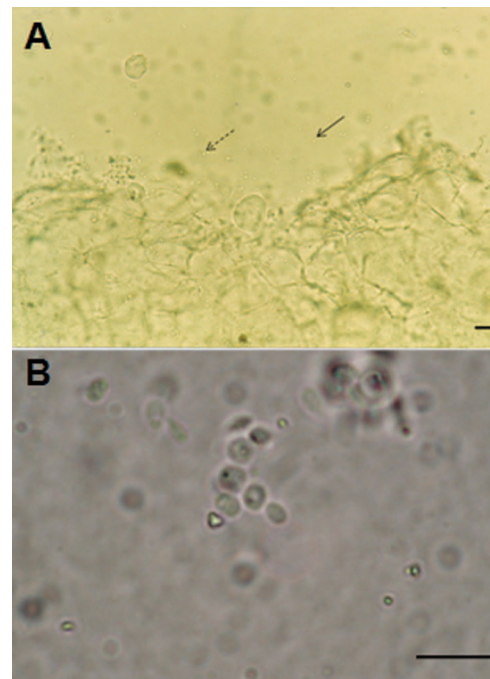


FIG. 5. Direct examination of clinical specimens for diagnosis of sporotrichosis. (A) KOH mount of a tissue fragment from a cat with sporotrichosis, showing cigar-shaped (arrow) and budding (dashed arrow) *S. schenckii* yeast cells. Note the high fungal burden in the specimen. (B) Direct examination (10% KOH) of the pus from a lesion of a human patient with sporotrichosis, showing nonspecific budding yeast cells. Bars, 10  $\mu$ m. (Courtesy of Rosani Santos Reis.)

### SPOROTRICHOSIS DIAGNOSIS

Sporotrichosis can be diagnosed through a correlation of clinical, epidemiological, and laboratory data. Laboratory analysis for the determination of sporotrichosis includes direct examination of specimens such as tissue biopsy specimens or pus from lesions. In case of disseminated infections, other specimens, such as sputum, urine, blood, and cerebrospinal and synovial fluids, can be analyzed, depending on the affected organs.

#### Direct Examination

Direct examination of specimens is usually conducted with 10% potassium hydroxide in order to observe parasitic budding yeast cells. These yeasts are small (2 to 6  $\mu$ m in diameter) and scarce and consequently are difficult to detect upon direct examination of specimens collected from humans. However, when the same test is performed with samples collected from infected cats, due to the high fungal burden in these animals, yeast cells can be easily found, even at a magnification of  $\times 400$  (Fig. 5). Fluorescent-antibody staining can help in the observation of yeast forms of *S. schenckii*; however, this is not a technique that is readily available in most laboratories (130), especially in underdeveloped countries. When the Gram stain is used on the clinical material, yeast cells appear positively stained, sometimes within giant cells or polymorphonuclear lymphocytes (129). For the detection of *S. schenckii*, some authors recommend Giemsa stain after 10 to 15 dilutions of



pus in physiological solution (12, 129). These staining procedures also lack sensitivity. Observation of yeast cells through direct examination, however, is not conclusive for sporotrichosis diagnosis. The characteristic "cigar-shaped" buds (2 by 3 to 3 by 10  $\mu\text{m}$ ) are not always witnessed. Moreover, yeast cells of *H. capsulatum* and *Candida glabrata* may be misidentified as *S. schenckii* (130).

Direct examination of pus obtained from lesions of patients with sporotrichosis, without potassium hydroxide, also permits the detection of asteroid bodies. These structures were confirmed in 43.75% of patients, and the sensitivity of the examination can be enhanced (up to 93.75%) if the initial pus is discarded and new samples are collected more deeply. This can help to initiate specific treatment before the results of the culture examinations are available (78).

### Histopathological Examination

Although *S. schenckii* may be seen in tissue with the routinely used hematoxylin and eosin (H&E) stain, other special stains such as Gomori methenamine silver (GMS) or periodic acid-Schiff (PAS) stain can be employed to enhance fungal detection (130, 170). Fontana-Masson staining is negative (54). Atypical *S. schenckii* cells can appear spherical and surrounded by a PAS-positive capsule, resembling *Cryptococcus* cells (126). Once again, parasitic cells of *S. schenckii* are difficult to visualize due to the paucity of yeasts in lesions from humans (170) or other animals such as dogs (57).

Tissue reaction must be also evaluated in histopathological examinations from patients with sporotrichosis. *S. schenckii* usually causes a mixed suppurative and granulomatous inflammatory reaction in the dermis and subcutaneous tissue, frequently accompanied by microabscess and fibrosis. Cutaneous infections may also exhibit hyperkeratosis, parakeratosis, and pseudoepitheliomatous hyperplasia (130). Foreign bodies of vegetal origin related to the traumatic inoculation of the agent may also be encountered (182).

Besides intact polymorphonuclear cells, granulomas in sporotrichosis usually contain cellular debris, caseous material, giant and epithelioid cell lymphocytes, plasmocytes, and fibroblasts as well as *S. schenckii* yeast cells within phagocytic cells or in the extracellular medium (129). Miranda and collaborators (167) reported that in dogs with sporotrichosis, lesions present well-formed granulomata, with marked neutrophil infiltration. The peripheral infiltrate often is devoid of lymphocytes and macrophages. Taken together, this information enables the differentiation of sporotrichosis and leishmaniasis in these animals.

Some histopathological alterations, such as presence or predominance of epithelioid granulomas, presence of foreign body granulomas, predominance of lymphocytes, presence or predominance of caseous necrosis, and predominance of fibrinoid necrosis and fibrosis, are related to the lack of observation of the fungus in tissue sections from human patients. When the fungus is not in evidence, suppurative granulomas, neutrophils, and liquefaction necrosis are uncommon (187).

Splendore in 1908 described a radiate eosinophilic substance in human tissues from patients with sporotrichosis, and Hoepli in 1932 reported an eosinophilic material around schistosome larvae (126). The Splendore-Hoepli reaction is indica-

tive of a localized immunological host response to antigens of diverse infectious organisms, including fungi, bacteria, and other parasites. It appears as radiating homogenous, refractile, eosinophilic clublike material surrounding a central eosinophilic focus (130). There are several reports concerning asteroid bodies, the Splendore-Hoepli reaction in sporotrichosis, in histopathological tissue sections from sporotrichosis patients, ranging in positivity from 20 to 66% (78). Other authors, however, report an absence of this structure in analyzed samples (187). Yeast cells remain viable inside the asteroid bodies, which present IgG and IgM from the host on the spikes of the radiated crowns, suggesting that asteroid bodies are resistance structures which use immune molecules of the host to advantage the yeasts (203).

### Culture

Definitive sporotrichosis diagnosis is based on the isolation and identification of the etiological agent in culture (126). Isolation of *S. schenckii* is easily obtained after spreading of the clinical specimens on Sabouraud agar with chloramphenicol and on media with cycloheximide, such as mycobiotic agar. After 5 to 7 days of incubation at 25°C, filamentous hyaline colonies start to grow, and after some time, they may develop a dark color, usually in the centers of the colonies (170). To identify an isolate as *S. schenckii*, one must demonstrate that it undergoes dimorphism by subculturing the fungus on enriched media such as brain heart infusion agar, chocolate agar, and blood agar at 35 to 37°C for 5 to 7 days. Occasional isolates can be difficult to convert and may require multiple subcultures and extended incubation (216). After *S. schenckii* conversion to the yeast phase, colonies acquire a creamy aspect and a yellow to tan color (170). Environmental *Sporothrix* strains may also form the yeast phase when grown on appropriate media at 37°C. For this reason, observation of dematiaceous conidia in colonies maintained at 25°C is mandatory (54, 60, 216). For this purpose, slide culture preparations with potato dextrose agar or cornmeal agar are ideal to study *S. schenckii* conidiogenesis (54).

Positive cultures provide the strongest evidence for sporotrichosis, allowing diagnosis of almost all cases of cutaneous disease. Nevertheless, culture diagnosis has significant limitations, mainly in some manifestations of the disease such as *S. schenckii* induced arthritis, where the collection of material for culture is difficult.

### Molecular Detection

Nonculture methods have been developed to improve the rate and speed of mycological diagnosis (194, 241). Molecular detection of *S. schenckii* is useful for a rapid diagnosis of sporotrichosis and also valuable in cases of negative cultures due to low fungal burden or secondary infections.

Up to now, there has been a scarcity of molecular methods for the detection of *S. schenckii* DNA from clinical specimens. Sandhu and collaborators (211) reported the development of 21 specific nucleotide probes targeting the large-subunit rRNA genes from several fungi, including *S. schenckii*. The authors adopted a protocol for DNA extraction from clinical specimens that consists of boiling the specimens in an alkaline

guanidine-phenol-Tris reagent, followed by amplification of a variable region of the 28S rRNA gene with universal primers and amplicon identification using the specific probes. The results displayed a high level of specificity for this test.

Some methodologies to identify *S. schenckii* colonies from pure cultures have been described. Specific probes for fungi with yeast-like morphology *in vivo*, including all dimorphic fungal pathogens, were developed for the detection of PCR amplicons in an enzyme immunoassay format. *S. schenckii* DNA was able to hybridize to the probe to detect all dimorphic fungi as well as to its specific probe (137). Specific oligonucleotide primers based on the chitin synthase gene were also developed. This primer was able to detect 10 pg of genomic *S. schenckii* DNA (110). Primers to distinguish *S. schenckii* from related species such as *Ceratocystis stenoceras*, based on the DNA topoisomerase II genes, permitted the amplification of fragments of 663 to 817 bp from *S. schenckii* and a 660-bp fragment from *S. schenckii* var. *lurei*. Another set of primers allowed the amplification of a specific 305-bp fragment from *S. schenckii* var. *lurei* (109). These detection systems may be useful as diagnostic tools for the detection of human and animal sporotrichosis. In fact, a PCR assay based on the internal transcriber space in the rRNA gene has been used for the identification of an *S. schenckii* strain from an atypical case of sporotrichosis (75).

#### Sporotrichin Skin Test

The cutaneous sporotrichin skin test detects delayed hypersensitivity, i.e., the cellular immune response, and can be a useful diagnostic tool, but its major usefulness is in epidemiological investigations. This reaction is usually positive in about 90% of confirmed sporotrichosis cases but can also indicate previous infection with the fungus (105). The sporotrichin skin test has been successfully applied to confirm the diagnosis of bulbar conjunctival sporotrichosis after the pathological examination revealed yeast-like cells (113).

Epidemiological studies usually involve the sporotrichin skin testing of individuals living or working in a determinate area together with attempts to isolate the fungus from the soil in that area. For instance, this test gave 6.25% positivity in a Mexican state where virulent strains of *S. schenckii* were isolated from soil (210). On the other hand, 13.67% positivity was found among healthy mine workers from Brazil, although the fungus was not isolated from soil samples from the mines investigated (198).

Despite the current use of the sporotrichin skin test in several studies throughout the world, the antigen adopted in these tests lacks standardization. Several studies on sporotrichin in Brazil were performed with a 5 McFarland standard suspension of heat-killed yeast cells (129). A retrospective 10-year study in Mexico used extracted mycelial antigens at a 1:2,000 dilution (28), while another Mexican study diluted yeast-phase antigens at 1:4,000 (210). These variations in antigen production may lead to differences in results.

#### Antibody Detection

Several methodologies have been described for the immunological diagnosis of sporotrichosis based on antibody detec-

tion in sera from infected patients. Precipitation and agglutination techniques were first adopted. Double immunodiffusion for sporotrichosis does not usually show cross-reactions with sera from patients with chromoblastomycosis or leishmaniasis, infectious diseases with similar clinical manifestations. Immunoelectrophoresis has also been employed, with an anodic arc, called S arc, being observed in all positive cases (2). Tube agglutination and latex agglutination have been utilized for sporotrichosis serodiagnosis since the 1970s, and very good sensitivity (96% and 94%, respectively) and specificity (98 and 100%, respectively) have been observed (26, 41, 112). These tests, however, lack sensitivity in cases of cutaneous sporotrichosis (2, 196) and do not permit the determination of the immunoglobulin isotype involved in the response.

Immunoenzymatic assays are currently being used more frequently for serodiagnosis purposes. The publication of an immunoblot assay for serodiagnosis of sporotrichosis dates back to 1989, when molecules of 40 and 70 kDa from exoantigen preparations from the *S. schenckii* yeast form showed 100% sensitivity and 95% specificity (229). Our group, however, in an attempt to reproduce these data, found high cross-reactivity of this antigenic preparation with sera from patients with paracoccidioidomycosis (unpublished results), which is not an endemic disease in the United States, where the first study was conducted.

Antibodies against a concanavalin A binding peptide-rhamnomannan from the *S. schenckii* yeast cell wall could be detected in an enzyme-linked immunosorbent assay (ELISA), showing 100% sensitivity when 35 serum samples from patients with culture-proven sporotrichosis were tested. However, sera from patients with cutaneous leishmaniasis showed cross-reactions in this assay format (140). This antigenic preparation was further evaluated with sera from 92 patients with sporotrichosis in Rio de Janeiro and 77 heterologous sera, with 90% sensitivity and 80% specificity (23). Other studies showed that the use of different strains in the preparation of the antigen may lead to different sensitivity and specificity results, despite the process of purification of the antigen involved in this methodology. This difference is due to O-glycan residues linked to the molecules. The strain that had better results was the 1099-18 strain obtained from the Mycology Section, Department of Dermatology, Columbia University, New York, NY (24).

Efforts to contribute to this field culminated in the development of an enzyme immunoassay with exoantigens produced by a mycelial-phase *S. schenckii* strain isolated during the Rio de Janeiro epidemic of sporotrichosis (7). This antigen was described by Mendoza and collaborators (161) and had no cross-reaction with antigens and serum samples from patients with coccidioidomycosis, histoplasmosis, or paracoccidioidomycosis. The same antigen was previously used in immunodiffusion and immunoelectrophoresis techniques, without cross-reactions with sera from patients with leishmaniasis or chromoblastomycosis (2). The methodology for production of this antigen is simple and does not require chromatographic steps, making it easy for laboratories with limited resources (7), although more variations can occur with this kind of preparation than with those involving purification procedures.

Detection of IgG antibodies against these exoantigens distinguished 90 sera from patients with different clinical forms of

sporotrichosis, 72 sera from patients with other infectious diseases, and 76 sera from healthy controls, yielding 97% sensitivity and 89% specificity (7). These values are slightly higher than those for the concanavalin A binding fraction of the *S. schenckii* yeast cell wall (23), and similar observations were made with this purified antigen and crude exoantigens in the serodiagnosis of feline sporotrichosis. Purified antigens exhibited 90% sensitivity and 96% specificity, whereas crude exoantigens showed 96% sensitivity and 98% specificity (65). It has also been demonstrated that in order to improve the overall efficiency of antibody detection for diagnosis and follow-up of human sporotrichosis with the mycelial exoantigen preparation, a search for IgG and IgA antibodies for diagnosis and a search for IgG and IgM antibodies for follow-up purposes must be undertaken (6).

Importantly, the results from all antibody detection tests provide a presumptive diagnosis of sporotrichosis and require clinical and epidemiological correlation for an accurate evaluation and determination of the final diagnosis.

## EPIDEMIOLOGY

The natural history of sporotrichosis has been changing gradually in frequency, mode of transmission, and demographic and geographic distributions. It is possible that environmental factors, increased urbanization, and improved diagnostics partly explain the alterations in the profile of the disease. Furthermore, since sporotrichosis is not a reportable disease in most countries, there is little information on the incidence, and the known data are those generated by case publications.

### Geographic Distribution

At the beginning of the last century, sporotrichosis was a common disease in France; it declined after 2 decades and today sporadically appears in Europe. In 2009, an autochthonous case was reported in France (146), and in 2008, another one was reported in the southern region of Italy (49), but these reports are rare and isolated. Despite having been described on five continents, sporotrichosis has a higher prevalence in tropical and temperate zones. The main areas of endemicity are located in Japan (248), India (156), Mexico (144), Brazil (17, 218, 222), Uruguay (45, 47), and Peru (124). In the United States, especially in the Mississippi Valley, outbreaks related to pine seedlings and manipulation of moss have been cited (185).

A bibliography search performed in PubMed with the term "*Sporothrix schenckii*" or "sporotrichosis" for the last 10 years (from January 2001 to November 2010) yielded 407 results. Of these, 83 were excluded (because they were book chapters, reports of other diseases, etc.). Of the remaining 324 references retrieved, 142 were case reports and case series for humans, 22 were case reports and case series for animals, 119 were laboratory studies (molecular studies, antifungal susceptibility tests, environmental studies, etc.), and 41 were various (reviews, letters, comments, or guidelines). These 324 publications were produced by authors from 27 countries. Obviously, these data reflect solely the scientific papers published by workers in these countries, and it is not possible to correlate with disease prevalence (Fig. 6). In the United States, where the incidence of cases is low and usually related to handling

sphagnum moss (92), the large number of publications reflects the development of research in the country. The lack of infrastructure for laboratory diagnosis and the lack of research in many countries do not allow for accurate knowledge of disease distribution and environmental sources of the fungus. Newton et al. (175), reporting a case of cutaneous-lymphatic sporotrichosis in a patient from Laos, highlighted the difficulties in laboratory diagnosis of fungal infections in Southeast Asian countries, resulting in a shortage of reports. These authors point out that in regions such as the highlands of China, Laos, Vietnam, and Burma, which have favorable conditions for *Sporothrix* growth, the prevalence of cases must be much higher than is estimated according to the literature.

### Distribution by Age and Gender

Sporotrichosis affects both genders and all ages. In most regions, the difference in case distribution by age and sex is related to occupation and exposure to the fungus. Among the cases studied by Takenaka et al. (248), 70% were older than 50 years, with an equal division between sexes. In Japan, where that study was conducted, working in agricultural activities has been associated with a higher risk for acquiring sporotrichosis. In Colombia (205) and the southern region of Brazil (10), there was a higher prevalence in men over 40 who were involved in agricultural as well as other high-risk activities. Also in Brazil, in the state of Rio de Janeiro, there was a predominance in women over 40 who were involved in housework and the care of cats with sporotrichosis, the highest risk group for acquiring the disease (18, 218). In Abancay, a rural area of Peru, of the 238 cases studied from 1995 to 1997, 60% occurred in children younger than 15 years old. In that study, no association between age, sex, and exposure to the fungus could be found (184).

### Transmission and Sources of Infection

Sporotrichosis has been traditionally known as "gardeners' disease," especially affecting those involved in the cultivation of roses (62). Although in most cases the infection results from inoculation of the fungus by thorn or other pricks, scratches, and other small injuries, a history of trauma can be absent (17, 184, 191). Certain occupational and leisure activities, such as floriculture, horticulture, gardening, fishing, hunting, farming, mining, and others that facilitate exposure to the fungus, have over the years been associated with the transmission of the disease (196). In Uruguay, and more recently in southern Brazil, the hunting of armadillos has been related to cases of sporotrichosis (10, 47). There have been reports of the mycosis following bites or scratches by animals such as cats and squirrels, insect bites, and other injuries. These conditions may either result in direct inoculation or facilitate the entry of the fungus (15, 166). In some situations, such as in an area of endemicity in Peru, the mode of transmission had not been made clear (115, 184) until another study in the same region identified the ownership of cats, outdoor activities, and low socioeconomic status as risk factors for acquiring sporotrichosis (142). Some cases have been reported in laboratory professionals who were infected by manipulating cultures of *S. schenckii* (48). Interhuman transmission is rare (215). Spor-

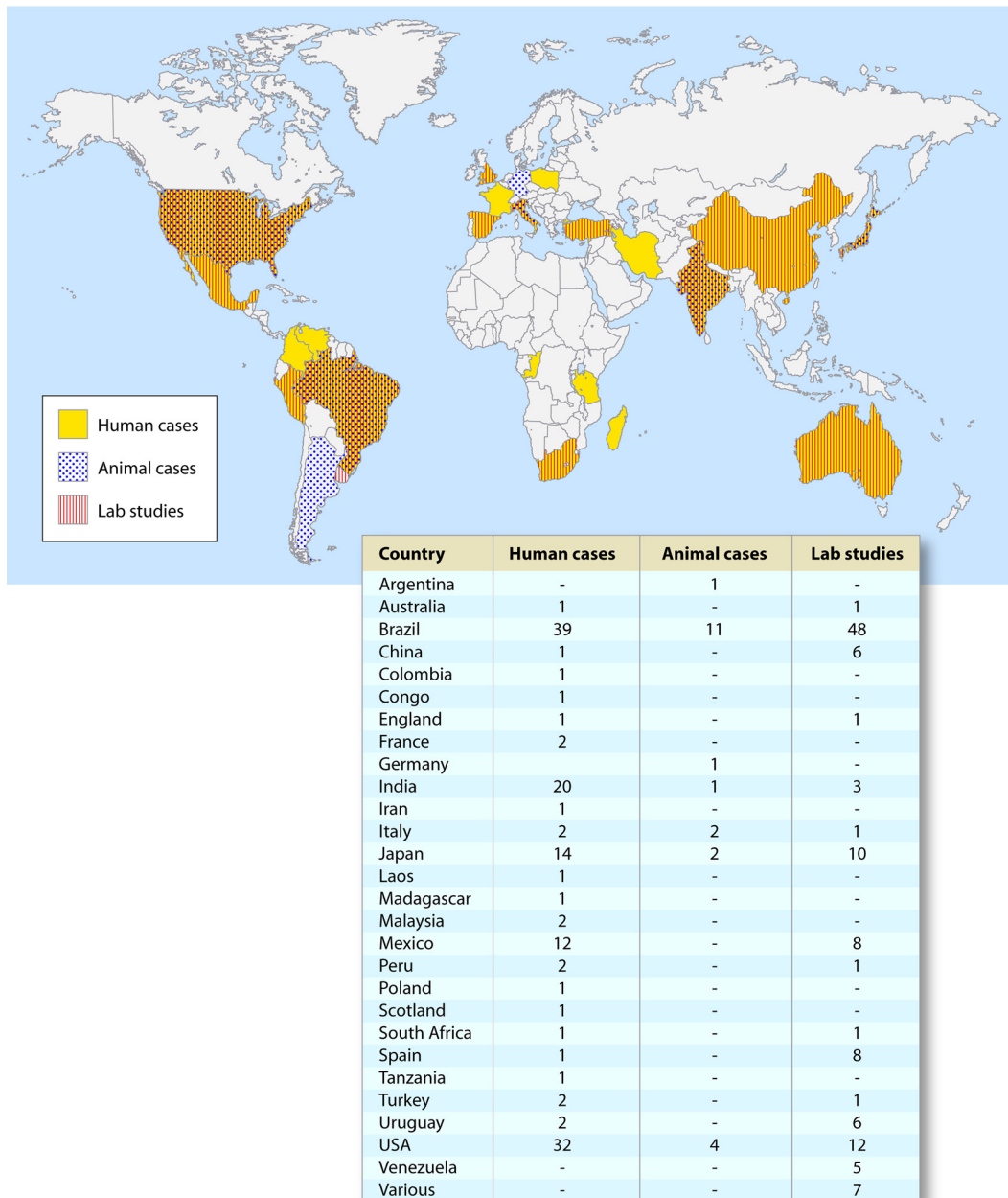


FIG. 6. Geographic distribution, by country, of scientific production on sporotrichosis in the 21st century according to the type of publication.

trichosis usually occurs in isolated cases or small outbreaks in families and professionals engaged in high-risk activities. Epidemics are rare and, when they occur, are commonly related to a single source of infection (30). The largest outbreak occurred in Witwatersrand, South Africa, and its description contributed significantly to the current knowledge of sporotrichosis, representing so far the most complete epidemiological investigation of the disease. Between 1941 and 1944, more than 3,000 gold miners were infected by the fungus, which was present in the timber of these mines (96). In the United States, the largest epidemic took place in 1988 and involved a total of 84 cases in 15 states, affecting workers who participated in reforestation programs. The cases were associated with exposure to sphag-

num moss used for the packing of seedlings from a nursery in Pennsylvania (42).

### Zoonotic Transmission

Sporotrichosis has been sporadically associated with scratches or bites from animals such as mice, armadillos, squirrels, dogs, and cats (114). The role of felines in the transmission of the mycosis has gained attention since the 1980s, when Read and Sperling (191) reported an outbreak involving five people exposed to a cat with sporotrichosis. Since then, successive reports from different geographical regions have characterized a new risk group for acquisition of sporotrichosis, composed of

cat owners and veterinarians (98, 269). The first epidemic of zoonotic sporotrichosis was detected in Rio de Janeiro (17, 222). From 1998 to December 2009, more than 2,000 cases in humans and over 3,000 cases in cats were diagnosed at Instituto de Pesquisa Clínica Evandro Chagas (IPEC)/Fiocruz, representing the largest epidemic of zoonotic transmission of this mycosis ever recorded (19). A study of 178 human cases assessed from 1998 to 2001 showed that of 156 patients who reported professional or household contact with cats with sporotrichosis, 97 had been scratched or bitten by these animals (17). Some authors believe that cats are the only animals with zoonotic transmission potential because of the large amount of yeast cells in the lesions (225, 245). Although dogs have also been affected, they do not seem to have significant zoonotic potential (223). Several studies have been conducted in an attempt to understand why sporotrichosis has reached epidemic proportions in Rio de Janeiro as well as the reason for the high susceptibility of cats to infection by *Sporothrix* (192, 224–226). However, the lack of studies on environmental, molecular, and feline immune responses against the fungus leave many questions unanswered. Gutierrez-Galhardo et al. (90) investigated the phenotypes and genotypes of *Sporothrix schenckii* isolates recovered from different clinical forms of the disease. A total of 88 isolates recovered from 59 human cases associated with the epidemic and 29 controls (cases from other Brazilian regions and Spain) were studied. Fingerprinting analysis showed that the Rio de Janeiro epidemic strains were genetically related. Although nine subtypes were found, they were not associated with specific clinical forms. Similar results were obtained by ribosomal DNA sequencing of the internal transcribed spacer sequence. These data suggest that the strains isolated from the cases of sporotrichosis in Rio de Janeiro all originated from a common source.

## PATHOGENESIS AND CLINICAL FORMS

### Human Disease

Clinical presentations of sporotrichosis may vary according to the immunological status of the host, the load and depth of the inoculum, and the pathogenicity and thermal tolerance of the strain, among other factors (14). Lavalle and Mariat (132) considered that the localized cutaneous form occurs by reinfection of patients who had previously developed immunity to *S. schenckii*, while the lymphocutaneous form manifests in patients without prior contact with the fungus. According to Rippon (196), continuous exposure to small amounts of conidia in an area of endemicity could gradually confer immunity. An experimental murine model adopted to study the genotypes, virulence, and clinical forms of *S. schenckii* showed a close relationship between genotype and clinical form. Mice inoculated with isolates from disseminated sporotrichosis presented a shorter time to the onset of the disease and more severe lesions than those inoculated with isolates from lymphocutaneous sporotrichosis. Those inoculated with isolates from the fixed form showed less severe lesions (123). Other studies have reported similar results. Brito et al. (29) studied the virulence of two strains of *Sporothrix schenckii*, isolated from patients with lymphocutaneous (group 1) or disseminated (group 2) sporotrichosis, by inoculating BALB/c mice. Com-

parison of the two groups revealed more severe disease in group 2 mice. The histopathology and large number of viable microorganisms isolated from the spleen confirmed the higher invasive ability of this strain. Furthermore, a decrease of an *in vitro* specific lymphoproliferative response and IFN- $\gamma$  production was observed over time in group 2. These results reinforce the existence of different virulence profiles in *S. schenckii* strains.

According to the location of the lesions, sporotrichosis can be classified into cutaneous, mucosal, and extracutaneous forms.

**Cutaneous forms.** In cutaneous forms, the infection usually appears after minor trauma with disruption of epidermis integrity. After penetrating through the skin, the fungus converts into the yeast form and may remain localized in the subcutaneous tissue or extend along the adjacent lymphatic vessels, constituting the fixed or the lymphocutaneous form, respectively. More rarely it may spread by the hematogenous route, characterizing the disseminated cutaneous form (239). In cases of cat-transmitted sporotrichosis, infection by the yeast form can also occur. This hypothesis is based on the large amount of this form in the lesions from cats associated with transmission without a history of scratches or bites (18). Moreover, the isolation of yeast forms in cats' claws also favors this idea (226). A molecular study revealed that DNA fingerprints of *S. schenckii* isolated from the nails and the oral cavities of cats were identical to those of related human samples, suggesting that there is a common infection source for animals and humans in the current epidemic in Rio de Janeiro (192). It is clear that cats act as a vehicle for *S. schenckii* dissemination. However, the lack of environmental studies on this epidemic and the deficit of information on natural sources that can serve as a reservoir of the fungus do not allow a conclusion to be drawn.

The fixed form is represented by a single lesion or a few lesions at the inoculation site, which is often ulcerated with erythematous edges. The morphology can also be vegetative, verrucous, plaque infiltrated, or tuberculous, without lymphatic involvement. Some cases may spontaneously regress (4). Most authors report the fixed cutaneous form as the main clinical presentation in children (252). However, the lymphocutaneous form is the most frequent overall, being present in more than 75% of cases (28, 190). The primary lesion is usually located on the extremities, especially hands and forearms, corresponding to the sites most exposed to trauma. Initially, a papule or pustule is followed by formation of a subcutaneous nodule. This lesion, exerting pressure beneath the skin, causes ischemia under the epidermis, evolves into gum, ulcerates, and oozes a purulent secretion. With the progression, secondary lesions arise along the path of regional lymphatics, featuring "sporotrichoid aspect" of the infection. Lymph node involvement or the presence of systemic symptoms is unusual.

A disseminated cutaneous form is characterized by multiple skin lesions at noncontiguous sites without extracutaneous involvement. Lesions of the fixed and lymphocutaneous forms may coexist in the same patient. Until the emergence of zoonotic transmission, this form was rare and was caused by hematogenous spread of the fungus, usually associated with immunosuppression (39, 239). In transmission by cats, several inoculations in different locations may occur, during either treatment or play with animals (20). Although there is a dis-

tinct pathogenesis for each situation, it is difficult to identify whether the clinical presentation is due to dissemination from a single lesion or to multiple inoculations.

**Mucosal form.** Some authors consider the mucosal form to be a variant of the cutaneous form. In the nasal mucosa, the lesions often involve the septum, with drainage of bloody secretions and detachment of crusts. In the conjunctiva, the granulomatous lesion is accompanied by a serous-purulent discharge, redness, and presence or not of lid edema (219). Mucosal forms are frequently accompanied by preauricular and submandibular lymph node enlargement (93, 219). These signs can be a consequence of self-inoculation through hands contaminated with the fungus, hematogenous dissemination, and inhalation of conidia (18, 20, 93). Although rare, conjunctival and nasal mucosal involvement has been diagnosed even in pediatric patients (16, 218). In cats with sporotrichosis, the nose is the most affected region and respiratory signs are common (83, 222). As the owners play with their animals in close contact, transmission is made easier.

**Extracutaneous form.** The extracutaneous forms are rare and difficult to diagnose, although they are more frequent after the onset of AIDS (31, 94, 234, 263). After the skin, bone tissue is the most affected. The osteoarticular form may occur by contiguity or hematogenous spread (120, 170). The lesions may vary from small granulomas to large lytic lesions identical to osteomyelitis (125). One or several joints and bones can be involved, as well as tenosynovitis or bursitis (115, 227). In immunocompetent patients, monoarthritis is more frequent than multiple articular involvement. The rarity of musculoskeletal disease in addition to the scarcity of fungal elements in synovial fluid culture and synovial histopathology often delays the diagnosis (11). According to Howell and Toohey, there were only 51 cases of sporotrichal arthritis reported in the English literature up to 1998 (102). Primary pulmonary sporotrichosis, resulting from inhalation of the fungus, is usually associated with chronic obstructive pulmonary disease, alcoholism, chronic use of corticosteroids and, immunosuppressive diseases (189). The clinical presentation is similar to that of tuberculosis, and the diagnosis is often delayed due to the rarity of pulmonary involvement. Radiological patterns include cavitory disease, tracheobronchial lymph nodes enlargement, and nodular lesions (183). Systemic sporotrichosis is extremely rare and always associated with immune system deficiency. De Beurmann and Gougerot (51) had suggested that sporotrichosis could be considered an opportunistic disease. Most of their patients had some comorbidity, and all cases with the extracutaneous form presented impaired health or malnutrition. Reports on meningitis associated with *Sporothrix* infection are not frequent, and these cases are often associated with immunological impairment, mainly after onset of HIV infection. Diagnosis of this form of chronic meningitis is challenging because of the rarity of demonstration of *Sporothrix schenckii* in smears of cerebrospinal fluid and the difficulty in isolating the yeast on culture. Thus, any other method that provides early and specific diagnosis, such as antibody detection in cerebrospinal fluid, may be helpful in the diagnosis (23, 228). According to Salaki et al. (209), there has been a marked increase in the number of reported cases of meningitis and brain abscess due to fungi and yeasts. This increase is due in part to better diagnostic techniques and greater awareness of the possibility

of fungal invasion of the nervous system, but the increase can also be attributed to a growing pool of severely compromised hosts. Besides AIDS, other conditions such as diabetes, alcoholism, granulomatous diseases, cirrhosis, renal transplantation, malignancies, corticosteroids, and use of immunosuppressive agents are commonly reported in patients with extracutaneous sporotrichosis (72, 82, 85). HIV-infected patients with preserved immunity seem to respond to infection by *Sporothrix schenckii* in the same way as individuals without coinfection (220). In patients with AIDS, sporotrichosis assumes the role of an opportunistic disease, with severe cases, systemic involvement, and often spread to the meninges (263). Skin lesions may be atypical, with a minimal inflammatory response (114). There are cases of disseminated sporotrichosis described in the literature as the first manifestation of AIDS (8) and associated with immune reconstitution inflammatory syndrome (76, 87).

**Associated signs and symptoms.** Erythema nodosum and erythema multiforme have been reported in cases of sporotrichosis by zoonotic transmission. These conditions appear to be associated with a hypersensitivity reaction, resulting from continuous exposure to large amounts of fungus and subclinical reinfections (86, 89).

**Differential diagnosis.** The differential diagnoses should be considered in accordance with the diversity of clinical forms and the morphology of the lesions. In the fixed form, the main differential diagnosis is cutaneous leishmaniasis. A study with application of the Montenegro skin test in 107 cases of sporotrichosis in Rio de Janeiro from 1998 to 2001 produced 48.6% positivity (21). In such cases, only mycological and parasitological examinations can establish a definitive diagnosis. Apart from cutaneous leishmaniasis, other causes, including noninfectious skin ulcers, should be considered. In the lymphocutaneous form, other disorders that present nodular lymphangitis should be investigated (58, 253), particularly mycobacteriosis. Among the mycobacteria, *Mycobacterium marinum* infection often accompanies lymphocutaneous lesions. There has been a report of sporotrichoid infection caused by *Mycobacterium fortuitum* in a pregnant woman (208). Nocardiosis (caused mainly by *Nocardia brasiliensis*), chromoblastomycosis, cryptococcosis, blastomycosis, and cat scratch disease also can be differential diagnoses. Sporotrichosis can also mimic cutaneous bacterial infections, sarcoidosis, lupus vulgaris, tuberculosis, and scrofuloderma, among others (11, 188, 268). These conditions should be differentiated by history, areas of endemicity, and lab tests.

### Feline Disease

De Beurmann et al. (52) experimentally demonstrated the susceptibility of cats to *S. schenckii* in 1909. However, naturally acquired feline sporotrichosis was reported only in 1952 by Singer and Muncie (236). Sporotrichosis in cats has been considered to be sporadic and transmission to humans to be accidental (61). In 1998 the first epizootic of cat sporotrichosis was detected. By December 2010, over 3,000 cases in cats were diagnosed at Fiocruz/Rio de Janeiro (19). A study by Schubach et al. evaluated 337 cats with sporotrichosis diagnosed by isolation of *S. schenckii* in culture, 10 asymptomatic cat carriers, and 91 asymptomatic apparently healthy cats in the period

from 1998 to 2001 (221, 222). In those 4 years of monitoring the epidemic, there was a broad spectrum in clinical presentation, ranging from subclinical infection to single lesions with spontaneous regression to fatal systemic forms. The lymphocutaneous form was determined in only 19.3% of the cases, the involvement of the mucous membranes of the respiratory tract and upper digestive tract in 34.9%, and multiple cutaneous lesions in 39.5% (222). Systemic disease was demonstrated by *in vivo* detection of *S. schenckii* in the skin and various internal organs in 10 cats necropsied (225). In cats, unlike in humans, the low frequency of granuloma (12%) and the richness of fungal elements found in the histopathology of the skin demonstrate the increased susceptibility of animals to *S. schenckii* (222). An evaluation of 142 cats with sporotrichosis regarding feline immunodeficiency virus (FIV) and/or feline leukemia virus (FeLV) infection revealed 21.8% positivity (222). There were no significant differences in clinical and laboratory profiles between animals coinfecting and not coinfecting with FIV and/or FeLV. Unlike in humans, in whom disseminated sporotrichosis typically affects immunocompromised individuals, systemic disease in cats was frequent and was not associated with immunodeficiency caused by FIV and/or FeLV.

### TREATMENT

Potassium iodide has been traditionally used in the treatment of sporotrichosis since the early 20th century, with satisfactory results (51). Some suggest that this salt acts on the resolution of granulomas through increased proteolysis (196), while others claim that it promotes an increase of phagocytosis. However, the exact mechanism of action remains unknown. Due to adverse effects related to this medication, in the 1990s the azole compounds were introduced, and itraconazole is currently the first-choice treatment (115). Itraconazole has been used effectively and safely in most cases of sporotrichosis, with low toxicity and good tolerance, even in long-term treatments. The dose varies from 100 to 200 mg/day orally for cutaneous and lymphocutaneous forms. A dose of 400 mg/day orally should be administered for cutaneous forms with a poor initial response to a lower dosage, for osteoarticular forms, for pulmonary forms, and as suppressive therapy in immunocompromised patients after induction with amphotericin B. For children weighing up to 20 kg, 5 to 10 mg/kg/day is recommended. Itraconazole is metabolized by the cytochrome P450 3A4 and has numerous drug interactions associated with the inhibition or induction of this system. The drug is contraindicated in pregnancy, and women of childbearing age should be counseled in favor of effective contraceptive methods. The safety and efficacy of itraconazole were evaluated in 645 patients with culture-proven sporotrichosis from Rio de Janeiro, Brazil. Six hundred ten (94.6%) of the patients were cured with itraconazole (50 to 400 mg/day), 547 with 100 mg/day, 59 with 200 to 400 mg/day, and 4 children with 50 mg/day. Four hundred sixty-two (71.6%) completed clinical follow-up for 3 to 6 months, and all remained cured. This study highlighted the good response to a minimal dose of itraconazole (55). Several reports have demonstrated the excellent efficacy and tolerability of the drug, even for the disseminated cutaneous and extracutaneous forms (119, 149, 165, 239, 268). The intermittent

administration of itraconazole in pulses of 400 mg/day orally for 1 week has also been studied (27). A randomized controlled study comparing the safety and efficacy of an itraconazole pulse regimen to a continuous regimen for cutaneous sporotrichosis found similar results for both groups (238). Potassium iodide and itraconazole are contraindicated in pregnant women. These patients can use thermotherapy with daily application of local heat (42 to 43°C) through a hot water bag, a source of infrared, or a similar method until healing of the lesions (115). The mechanism of action of local heat has been demonstrated in the laboratory. When cells of *S. schenckii* in serum are incubated with neutrophils at 40°C and 37°C, there is no difference related to phagocytosis in the two groups. However, once the cells are phagocytosed, the death rate of the fungus is higher at 40°C than at 37°C (99). Amphotericin B has been given for initial treatment of disseminated forms, particularly in immunocompromised subjects (115). Patients coinfecting with HIV should subsequently receive suppressive therapy with itraconazole until immune system restoration. In pregnant women, amphotericin B may be used after 12 weeks of pregnancy, but this medication is to be reserved for pulmonary and disseminated forms for which treatment cannot be delayed. Fluconazole is less effective than itraconazole and is given to patients who do not tolerate or have drug interactions with itraconazole. Ketoconazole, in addition to having greater toxicity, has not demonstrated a good response (115).

Susceptibility studies concerning good *in vitro* activity of terbinafine and posaconazole against *Sporothrix schenckii* have been encouraging (157, 235). The three studies using terbinafine in human patients demonstrated a good efficacy for doses ranging from 250 to 1,000 mg/day (43, 73, 74). A study comparing 250 mg/day of terbinafine to 100 mg/day of itraconazole resulted in healing in 92.7% and 92% of patients, respectively, indicating terbinafine to be an effective and well-tolerated option for the treatment of cutaneous sporotrichosis (73). However, the cost, which is even higher than that of itraconazole, is a barrier for developing countries. Posaconazole is a broad-spectrum triazole, but its use in clinical sporotrichosis is yet to be evaluated (214, 235). Susceptibility testing with voriconazole, ravuconazole, micafungin, and other new antifungal agents is still incipient, and so far there is no indication for use of these drugs for the treatment of sporotrichosis (9, 169, 178, 233). There are studies showing different results for the same antifungal agent according to geographic area, the species of *Sporothrix*, and the method used (9, 88, 169).

### Antifungal Susceptibility Tests

Nowadays, there is an ever-increasing interest in testing the susceptibilities of filamentous and yeast fungal pathogens to the available antifungal drugs (80). Of the available methods, two are standardized for *S. schenckii* testing. The Clinical and Laboratory Standards Institute (CLSI) proposes a microdilution test with a test inoculum of  $0.4 \times 10^4$  to  $5 \times 10^4$  CFU/ml, rendered from a 7-day-old *S. schenckii* filamentous colony, used to inoculate RPMI 1640 medium, where antifungal drugs are serially diluted and, after 46 to 50 h of incubation at 35°C without agitation, MICs determined (46). Another protocol for *S. schenckii* antifungal susceptibility testing was elaborated by the European Committee for Antimicrobial Susceptibility

TABLE 1. MIC ranges for 13 antifungal drugs against *S. schenckii* described in various publications<sup>a</sup>

Reference	Location	No. of strains analyzed	MIC ( $\mu\text{g/ml}$ ) <sup>b</sup>				
			AMB	FLC	ITR	KET	VOR
64	USA	5	0.5–16	64	0.03–16	0.25–4	NT
106	UK	10	0.5–4	NT	0.06–>16	NT	0.12–>16
155	Not reported	100	0.25–2	NT	0.03–8	NT	0.5–8
172	Japan	7	1–2	>64	0.5–1	NT	NT
121	Brazil	30	NT	NT	0.06–4	NT	NT
179	USA	3	1–4	NT	NT	NT	>16
169	Peru	22	NT	NT	0.06–1	NT	2–16
81	Mexico	15	NT	>64	0.25–2	NT	1–4
258	Brazil	34	1–4	>64	0.25–>16	0.03–16	0.5–>16
122	Brazil	43	0.5–8	NT	0.25–4	NT	NT
10	Peru	19	0.06–>16	>64	0.25–1	0.06–0.5 <sup>c</sup>	4–16
157	Brazil	12	NT	NT	0.2–1.75	NT	NT
91	Brazil/Spain	88	0.12–4	64	0.12–>8	NT	1–>8
152	Several	92	0.5–32	128	0.5–32	0.06–8	0.5–32
208	Not reported	10	NT	NT	0.5–2	NT	NT
235	Several	62	0.03–16	NT	0.03–2	NT	NT

<sup>a</sup> Results were obtained by microdilution reference methods unless otherwise specified.

<sup>b</sup> AMB, amphotericin B; FLC, fluconazole; ITR, itraconazole; KET, ketoconazole; VOR, voriconazole; MFG, micafungin; ADF, anidulafungin; TRB, terbinafine; 5FC, 5-fluorocytosine; RVC, ravuconazole; POS, posaconazole; ABC, albaconazole; EBC, eberconazole; NT, not tested.

<sup>c</sup> The MIC was determined by the Etest method.

Testing (EUCAST), which uses final test inoculums of  $1 \times 10^5$  to  $2.5 \times 10^5$  CFU/ml obtained from 2- to 5-day-old cultures to inoculate microplates with RPMI 1640 supplemented with 2% glucose. The endpoint is read visually after a 48 h of incubation at  $35 \pm 2^\circ\text{C}$  (201).

Commercial methods for *S. schenckii* susceptibility testing, however, have been adopted by some investigators. The Etest technique shows average agreement rates of 77.5% and 87.8% for amphotericin B and fluconazole, respectively, but for itraconazole and voriconazole agreement is lower, with values of 56.4% and 54.5%, respectively. MIC values for itraconazole and voriconazole determined by Etest were significantly lower than those obtained by microdilution (87). The Sensititre YeastOne and ATB Fungus 2 methods compared with CLSI M38-A2 show high agreement with microdilution for fluconazole, itraconazole, and 5-fluorocytosine, but for amphotericin B and voriconazole, agreement is lower (9).

Up to now, breakpoints have not been established for molds, including the dimorphic fungus *S. schenckii*. However, studies showed that MICs of below  $1 \mu\text{g/ml}$  are usually found for *Scedosporium apiospermum* and *Paecilomyces lilacinus* with posaconazole and voriconazole, for *Alternaria* spp. and *Bipolaris spicifera* with posaconazole, voriconazole, and itraconazole, for zygomycetes with amphotericin B and posaconazole, and for *Aspergillus* spp. with posaconazole, voriconazole, itraconazole, amphotericin, and caspofungin. Based on this, isolates can be grouped as susceptible (MIC  $\leq 1 \mu\text{g/ml}$ ), intermediate (MIC =  $2 \mu\text{g/ml}$ ), or resistant (MIC  $\geq 4 \mu\text{g/ml}$ ) only for analytical purposes. Breakpoints with proven relevance have yet to be identified by the regulatory agencies (46).

Despite the use of the nonparasitic *S. schenckii* mycelial phase in standardized methods, some studies have compared susceptibilities for the mycelial and yeast fungal morphological phases. Agreements of above 80% were found for amphotericin B, fluconazole, itraconazole, ravuconazole, and terbinafine. For posaconazole, an agreement of 76.5% was found for mycelial and yeast forms, and only 47.6% was verified for

voriconazole (87) in a study with Brazilian and Spanish *S. schenckii* strains. Another study found similar MICs for itraconazole and terbinafine, although the MIC of amphotericin B was slightly higher for mycelia (122). It has been also demonstrated that micafungin is more active against the mycelial than the yeast *S. schenckii* form (172). Table 1 displays the MIC range for several drugs tested in 16 different studies concerning *S. schenckii* susceptibility profiles. Since the methodologies used in these studies may have slight differences, comparison of results is difficult. However, some conclusions can be reached. MICs for *S. schenckii* show high variability (63), as we can see in studies on itraconazole susceptibility. *S. schenckii* susceptibility to this triazole drug ranges from 0.03 to more than  $16 \mu\text{g/ml}$ . Although some strains can show resistance to this drug, geometric means commonly are low, ranging from  $0.4 \mu\text{g/ml}$  (9) to  $4.08 \mu\text{g/ml}$  (257). In general, despite the use of fluconazole as a therapeutic agent in some human and veterinary sporotrichosis cases (31, 50), this antifungal does not inhibit *S. schenckii* growth *in vitro* (9, 63, 90, 152, 172, 257). Some *S. schenckii* strains are susceptible to voriconazole *in vitro*, since MIC values of as low as  $0.12 \mu\text{g/ml}$  have been found (107); however, the high geometric mean MIC values, ranging from  $6.50 \mu\text{g/ml}$  (155) to  $13.2 \mu\text{g/ml}$  (152), suggest that most isolates are resistant *in vitro* to this drug. High micafungin MIC values have been reported by all but one study (152, 172, 207, 257). However, the interaction of micafungin and itraconazole shows a synergy against *S. schenckii* (207).

The geographic distribution of *S. schenckii* strains also appears to play an important role in antifungal susceptibility. Strains from the sporotrichosis area of endemicity in Rio de Janeiro are more susceptible to itraconazole and terbinafine than strains from Spain or São Paulo, a neighbor state Rio de Janeiro in Brazil (90). Low terbinafine MIC values were described for strains from Venezuela, and high minimal fungicidal concentration values for posaconazole were found in Peruvian strains (235). This behavior must be related to differences in susceptibility of the newly characterized species



TABLE 1—Continued

MIC (µg/ml) <sup>b</sup>								
MFG	ADF	TRB	5FC	RVC	POS	ABC	EBC	
NT	NT	NT	NT	NT	NT	NT	NT	NT
NT	NT	NT	NT	NT	NT	NT	NT	NT
NT	NT	NT	NT	NT	NT	NT	NT	NT
0.5–1	NT	NT	NT	NT	NT	NT	NT	NT
NT	NT	0.007–0.5	NT	NT	NT	NT	NT	NT
NT	2–4	NT	NT	NT	NT	NT	NT	NT
NT	NT	NT	NT	NT	NT	NT	NT	NT
NT	NT	NT	NT	0.5–4	1–4	NT	NT	NT
>128	NT	0.12–4	16–>64	1–16	NT	0.12–16	0.06–4	NT
NT	NT	0.015–1	NT	NT	NT	NT	NT	NT
NT	NT	NT	4–>64	NT	NT	NT	NT	NT
NT	NT	0.05–0.875	NT	NT	NT	NT	NT	NT
NT	NT	0.02–>16	4–>64	0.12–>8	0.06–>8	NT	NT	NT
256	NT	0.06–4	1–128	0.06–32	0.25–16	0.25–32	0.06–32	0.06–32
2–64	NT	NT	NT	NT	NT	NT	NT	NT
NT	NT	0.03–1	NT	NT	0.03–2	NT	NT	NT

from the *Sporothrix* complex. In fact, *S. mexicana* shows high MIC values of amphotericin B and several azoles, being susceptible to terbinafine only. *S. brasiliensis* also is more susceptible to azole drugs than the other species (152).

**PREVENTION**

Most cases of sporotrichosis occur when the fungus is introduced through a cut or puncture in the skin while handling vegetation or organic matter containing the fungal spores. Control measures include wearing gloves and long sleeves during high-risk activities such as handling sphagnum moss, wires, rose bushes, hay bales, conifer (pine) seedlings, or other materials that may facilitate the exposure to the fungus. A study by Hajjeh et al. (92) showed that the risk of sporotrichosis increased significantly with the duration of working with sphagnum moss, in particular with filling topiaries, and with having less gardening experience. Wearing gloves was protective. It is also advisable to wear heavy boots to prevent puncture wounds.

Sporotrichosis in cats requires preventive measures to avoid transmission within the species and from animals to humans. Due to the itinerant nature of cats, where males frequently engage in disputes over females, infection is quite common. Cats with sporotrichosis should be correctly treated and kept isolated in a proper place. Any physical contact with the animal should be avoided until complete healing of the lesions. When handling the sick cat, during either injury treatment or medication administration, protocols must be adopted to reduce exposure to the fungus, such as using latex gloves. Another important measure is not to abandon the animal, as this facilitates the dissemination of the disease. In the case of cats with extensive lesions and no possibility of treatment, euthanasia and cremation of the body should be standard procedures in a veterinary health centers. Castration encumbers the instinct for hunting, mating, and roaming the neighborhood, therefore reducing the chance of transmission of the mycosis. Some intervention in the environment may be necessary, such as cleaning yards and removing remnants of construction materials and decaying organic matter debris. Only the treatment of

sick cats and measures regarding feline sporotrichosis will afford zoonotic transmission control (19).

**ACKNOWLEDGMENTS**

We thank Rosani Santos Reis, who kindly provided Fig. 5. This study was partially supported by the Conselho Nacional de Desenvolvimento Científico e Tecnológico (CNPq), Brazil, by the programa de Apoio a Pesquisa Estratégica em Saúde (PAPES)—Fundação Oswaldo Cruz (Fiocruz)/CNPq, and by the Fundação de Apoio a Pesquisa do Estado do Rio de Janeiro (FAPERJ), Brazil.

**REFERENCES**

1. Ahearn, D. G., and W. Kaplan. 1969. Occurrence of *Sporothrix schenckii* on a cold-stored meat product. *Am. J. Epidemiol.* **89**:116–124.
2. Albornoz, M. B., E. Villanueva, and E. D. Torres. 1984. Application of immunoprecipitation techniques to the diagnosis of cutaneous and extracutaneous forms of sporotrichosis. *Mycopathologia* **85**:177–183.
3. Albuquerque, P. C., et al. 2008. Vesicular transport in *Histoplasma capsulatum*: an effective mechanism for trans-cell wall transfer of proteins and lipids in ascomycetes. *Cell. Microbiol.* **10**:1695–1710.
4. Almeida, H. L., Jr., C. B. Lettnin, J. L. Barbosa, and M. C. Dias. 2009. Spontaneous resolution of zoonotic sporotrichosis during pregnancy. *Rev. Inst. Med. Trop. Sao Paulo* **51**:237–238.
5. Almeida-Paes, R., et al. 2009. Growth conditions influence melanization of Brazilian clinical *Sporothrix schenckii* isolates. *Microbes Infect.* **11**:554–562.
6. Almeida-Paes, R., M. A. Pimenta, P. C. Monteiro, J. D. Nosanchuk, and R. M. Zanco-Oliveira. 2007. Immunoglobulins G, M, and A against *Sporothrix schenckii* exoantigens in patients with sporotrichosis before and during treatment with itraconazole. *Clin. Vaccine Immunol.* **14**:1149–1157.
7. Almeida-Paes, R., et al. 2007. Use of mycelial-phase *Sporothrix schenckii* exoantigens in an enzyme-linked immunosorbent assay for diagnosis of sporotrichosis by antibody detection. *Clin. Vaccine Immunol.* **14**:244–249.
8. Al-Tawfiq, J. A., and K. K. Wools. 1998. Disseminated sporotrichosis and *Sporothrix schenckii* fungemia as the initial presentation of human immunodeficiency virus infection. *Clin. Infect. Dis.* **26**:1403–1406.
9. Alvarado-Ramirez, E., and J. M. Torres-Rodriguez. 2007. *In vitro* susceptibility of *Sporothrix schenckii* to six antifungal agents determined using three different methods. *Antimicrob. Agents Chemother.* **51**:2420–2423.
10. Alves, S. H., et al. 2010. *Sporothrix schenckii* associated with armadillo hunting in Southern Brazil: epidemiological and antifungal susceptibility profiles. *Rev. Soc. Bras. Med. Trop.* **43**:523–525.
11. Appenzeller, S., et al. 2006. *Sporothrix schenckii* infection presented as monoarthritis: report of two cases and review of the literature. *Clin. Rheumatol.* **25**:926–928.
12. Area-Leão, A. E., and M. Goto. 1946. Esporotricose. Observação e estudo de um novo caso. *Hospital* **30**:409–417.
13. Arenas, R., D. Miller, and P. Campos-Macias. 2007. Epidemiological data and molecular characterization (mtDNA) of *Sporothrix schenckii* in 13 cases from Mexico. *Int. J. Dermatol.* **46**:177–179.
14. Arrillaga-Moncrieff, I., et al. 2009. Different virulence levels of the species of *Sporothrix* in a murine model. *Clin. Microbiol. Infect.* **15**:651–655.

15. Barba Borrego, J. A., J. Mayorga, and V. M. Tarango-Martinez. 2009. Esporotricosis linfangítica bilateral y simultánea. *Rev. Iberoam. Micol.* **26**:247–249.
16. Barros, M. B., et al. 2008. Endemic of zoonotic sporotrichosis: profile of cases in children. *Pediatr. Infect. Dis. J.* **27**:246–250.
17. Barros, M. B. L., A. O. Schubach, A. C. do Valle, et al. 2004. Cat-transmitted sporotrichosis epidemic in Rio de Janeiro, Brazil: description of a series of cases. *Clin. Infect. Dis.* **38**:529–535.
18. Barros, M. B. L., A. O. Schubach, T. M. Schubach, B. Wanke, and S. R. Lambert-Passos. 2008. An epidemic of sporotrichosis in Rio de Janeiro, Brazil: epidemiological aspects of a series of cases. *Epidemiol. Infect.* **136**:1192–1196.
19. Barros, M. B. L., et al. 2010. Esporotricose: a evolução e os desafios de uma epidemia. *Rev. Panam. Salud Publ.* **27**:455–460.
20. Barros, M. B. L., et al. 2003. Sporotrichosis with widespread cutaneous lesions: report of 24 cases related to transmission by domestic cats in Rio de Janeiro, Brazil. *Int. J. Dermatol.* **42**:677–681.
21. Barros, M. B. L., A. Schubach, A. C. Francesconi-do-Valle, et al. 2005. Positive Montenegro skin test among patients with sporotrichosis in Rio de Janeiro. *Acta Trop.* **93**:41–47.
22. Berbee, M. L., and J. W. Taylor. 1992. Convergence in ascospore discharge mechanism among pyrenomyces fungi based on 18S ribosomal RNA gene sequence. *Mol. Phylogenet. Evol.* **1**:59–71.
23. Bernardes-Engemann, A. R., et al. 2005. Development of an enzyme-linked immunosorbent assay for the serodiagnosis of several clinical forms of sporotrichosis. *Med. Mycol.* **43**:487–493.
24. Bernardes-Engemann, A. R., et al. 2009. A comparative serological study of the SsCBF antigenic fraction isolated from three *Sporothrix schenckii* strains. *Med. Mycol.* **47**:874–878.
25. Betancourt, S., L. J. Torres-Bauza, and N. Rodriguez-Del Valle. 1985. Molecular and cellular events during the yeast to mycelium transition in *Sporothrix schenckii*. *Sabouraudia* **23**:207–218.
26. Blumer, S. O., L. Kaufman, W. Kaplan, D. W. McLaughlin, and D. E. Kraft. 1973. Comparative evaluation of five serological methods for the diagnosis of sporotrichosis. *Appl. Microbiol.* **26**:4–8.
27. Bonifaz, A., L. Fierro, A. Saul, and R. M. Ponce. 2008. Cutaneous sporotrichosis. Intermittent treatment (pulses) with itraconazole. *Eur. J. Dermatol.* **18**:61–64.
28. Bonifaz, A., et al. 2007. Sporotrichosis in childhood: clinical and therapeutic experience in 25 patients. *Pediatr. Dermatol.* **24**:369–372.
29. Brito, M. M., et al. 2007. Comparison of virulence of different *Sporothrix schenckii* clinical isolates using experimental murine model. *Med. Mycol.* **45**:721–729.
30. Bustamante, B., and P. E. Campos. 2001. Endemic sporotrichosis. *Curr. Opin. Infect. Dis.* **14**:145–149.
31. Callens, S. F., et al. 2006. Pulmonary *Sporothrix schenckii* infection in a HIV positive child. *J. Trop. Pediatr.* **52**:144–146.
32. Carlos, I. Z., M. F. Sassa, D. B. da Graca Sgarbi, M. C. Placeres, and D. C. Maia. 2009. Current research on the immune response to experimental sporotrichosis. *Mycopathologia* **168**:1–10.
33. Carlos, I. Z., D. B. Sgarbi, J. Angluster, C. S. Alviano, and C. L. Silva. 1992. Detection of cellular immunity with the soluble antigen of the fungus *Sporothrix schenckii* in the systemic form of the disease. *Mycopathologia* **117**:139–144.
34. Carlos, I. Z., D. B. Sgarbi, and M. C. Placeres. 1998. Host organism defense by a peptide-polysaccharide extracted from the fungus *Sporothrix schenckii*. *Mycopathologia* **144**:9–14.
35. Carlos, I. Z., D. B. Sgarbi, G. C. Santos, and M. C. Placeres. 2003. *Sporothrix schenckii* lipid inhibits macrophage phagocytosis: involvement of nitric oxide and tumour necrosis factor- $\alpha$ . *Scand. J. Immunol.* **57**:214–220.
36. Carlos, I. Z., et al. 1994. Disturbances in the production of interleukin-1 and tumor necrosis factor in disseminated murine sporotrichosis. *Mycopathologia* **127**:189–194.
37. Carmichael, J. W. 1962. *Chrysosporium* and some other aleuriosporic Hyphomycetes. *Can. J. Bot.* **40**:1137–1173.
38. Carvalho, L. P., et al. 2007. Differential immune regulation of activated T cells between cutaneous and mucosal leishmaniasis as a model for pathogenesis. *Parasite Immunol.* **29**:251–258.
39. Carvalho, M. T., et al. 2002. Disseminated cutaneous sporotrichosis in a patient with AIDS: report of a case. *Rev. Soc. Bras. Med. Trop.* **35**:655–659.
40. Casadevall, A. 2006. Cards of virulence and the global virulome for humans. *Microbe* **1**:359–364.
41. Casserone, S., I. A. Conti-Diaz, E. Zanetta, and M. E. P. Pereira. 1983. Serologia de la esporotricosis cutánea. *Sabouraudia* **21**:317–321.
42. Centers for Disease Control and Prevention. 1988. Multistate outbreak of sporotrichosis in seedling handlers. *Morb. Mortal. Wkly. Rep.* **37**:652–653.
43. Chapman, S. W., et al. 2004. Comparative evaluation of the efficacy and safety of two doses of terbinafine (500 and 1000 mg day<sup>-1</sup>) in the treatment of cutaneous or lymphocutaneous sporotrichosis. *Mycoses* **47**:62–68.
44. Chua, S. S., M. Momany, L. Mendoza, and P. J. Szaniszló. 1994. Identification of three chitin synthase genes in the dimorphic fungal pathogen *Sporothrix schenckii*. *Curr. Microbiol.* **29**:151–156.
45. Civilá, E. S., J. Bonasse, I. A. Conti-Diaz, and R. A. Vignale. 2004. Importance of the direct fresh examination in the diagnosis of cutaneous sporotrichosis. *Int. J. Dermatol.* **43**:808–810.
46. Clinical and Laboratory Standards Institute. 2008. Reference method for broth dilution antifungal susceptibility testing of filamentous fungi; approved standard, 2nd ed. Clinical and Laboratory Standards Institute, Wayne, PA.
47. Conti Diaz, I. A. 1989. Epidemiology of sporotrichosis in Latin America. *Mycopathologia* **108**:113–116.
48. Cooper, C. R., D. M. Dixon, and I. F. Salkin. 1992. Laboratory-acquired sporotrichosis. *J. Med. Vet. Mycol.* **30**:169–171.
49. Criseo, G., G. Malara, O. Romeo, and A. Puglisi Guerra. 2008. Lymphocutaneous sporotrichosis in an immunocompetent patient: a case report from extreme southern Italy. *Mycopathologia* **166**:159–162.
50. Crothers, S. L., S. D. White, P. J. Ihrke, and V. K. Afoller. 2009. Sporotrichosis: a retrospective evaluation of 23 cases seen in northern California (1987–2007). *Vet. Dermatol.* **20**:249–259.
51. De Beurmann, L., and H. Gougerot. 1912. Les sporotrichoses. Librairie Félix Alcan, Paris, France.
52. De Beurmann, L., H. Gougerot, and A. B. Vaucher. 1909. Sporotrichoses cutanées du chat. *C. R. Soc. Biol.* **66**:370–372.
53. de Hoog, G. S., and J. Guarro. 1995. Atlas of clinical fungi. Centraalbureau voor Schimmelcultures, Baarn and Delft, The Netherlands.
54. de Hoog, G. S., and R. G. Vitale. 2007. *Bipolaris*, *Exophiala*, *Scedosporium*, *Sporothrix* and other dematiaceous fungi, p. 1898–1917. In P. R. Murray, E. J. Baron, J. H. Jorgensen, M. L. Landry, and M. A. Pfaller (ed.), *Manual of clinical microbiology*, 9th ed., vol. 2. ASM Press, Washington, DC.
55. de Lima Barros, M. B., et al. 2011. Treatment of cutaneous sporotrichosis with itraconazole—study of 645 patients. *Clin. Infect. Dis.* **52**:e200–e206.
56. de Meyer, E. M., et al. 2008. Taxonomy and phylogeny of new wood- and soil-inhabiting *Sporothrix* species in the *Ophiostoma stenoceras-Sporothrix schenckii* complex. *Mycologia* **100**:647–661.
57. de Miranda, L. H., L. P. Quintella, I. B. dos Santos, et al. 2009. Histopathology of canine sporotrichosis: a morphological study of 86 cases from Rio de Janeiro (2001–2007). *Mycopathologia* **168**:79–87.
58. DiNubile, M. J. 2008. Nodular lymphangitis: a distinctive clinical entity with finite etiologies. *Curr. Infect. Dis. Rep.* **10**:404–410.
59. Dixon, D. M., R. A. Duncan, and N. J. Hurd. 1992. Use of a mouse model to evaluate clinical and environmental isolates of *Sporothrix* spp. from the largest U.S. epidemic of sporotrichosis. *J. Clin. Microbiol.* **30**:951–954.
60. Dixon, D. M., et al. 1991. Isolation and characterization of *Sporothrix schenckii* from clinical and environmental sources associated with the largest U.S. epidemic of sporotrichosis. *J. Clin. Microbiol.* **29**:1106–1113.
61. Dunstan, R. W., R. F. Langham, K. A. Reimann, and P. S. Wakenell. 1986. Feline sporotrichosis: a report of five cases with transmission to humans. *J. Am. Acad. Dermatol.* **15**:37–45.
62. Engle, J., J. Desir, and J. M. Bernstein. 2007. A rose by any other name. *Skinmed* **6**:139–141.
63. Espinel-Ingroff, A., et al. 1995. Comparative and collaborative evaluation of standardization of antifungal susceptibility testing for filamentous fungi. *Antimicrob. Agents Chemother.* **39**:314–319.
64. Feeney, K. T., I. H. Arthur, A. J. Whittle, S. A. Altman, and D. J. Speers. 2007. Outbreak of sporotrichosis, Western Australia. *Emerg. Infect. Dis.* **13**:1228–1231.
65. Fernandes, G. F., et al. 2011. Serodiagnosis of sporotrichosis infection in cats by enzyme-linked immunosorbent assay using a specific antigen, SsCBF, and crude exoantigens. *Vet. Microbiol.* **147**:445–449.
66. Fernandes, K. S., A. L. Coelho, L. M. Lopes Bezerra, and C. Barja-Fidalgo. 2000. Virulence of *Sporothrix schenckii* conidia and yeast cells, and their susceptibility to nitric oxide. *Immunology* **101**:563–569.
67. Fernandes, K. S., H. L. Mathews, and L. M. Lopes Bezerra. 1999. Differences in virulence of *Sporothrix schenckii* conidia related to culture conditions and cell-wall components. *J. Med. Microbiol.* **48**:195–203.
68. Fernandes, K. S., et al. 2008. Detrimental role of endogenous nitric oxide in host defence against *Sporothrix schenckii*. *Immunology* **123**:469–479.
69. Figueiredo, C. C., O. C. De Lima, L. De Carvalho, L. M. Lopes-Bezerra, and V. Morandi. 2004. The *in vitro* interaction of *Sporothrix schenckii* with human endothelial cells is modulated by cytokines and involves endothelial surface molecules. *Microb. Pathog.* **36**:177–188.
70. Figueiredo, C. C., P. M. Deccache, L. M. Lopes-Bezerra, and V. Morandi. 2007. TGF- $\beta$ 1 induces transendothelial migration of the pathogenic fungus *Sporothrix schenckii* by a paracellular route involving extracellular matrix proteins. *Microbiology* **153**:2910–2921.
71. Flournoy, D. J., J. B. Mullins, and R. J. McNeal. 2000. Isolation of fungi from rose bush thorns. *J. Okla. State Med. Assoc.* **93**:271–274.
72. Fonseca-Reyes, S., et al. 2007. Extracutaneous sporotrichosis in a patient with liver cirrhosis. *Rev. Iberoam. Micol.* **24**:41–43.
73. Francesconi, G., A. C. Francesconi do Valle, et al. 2011. Comparative study of 250 mg/day terbinafine and 100 mg/day itraconazole for the treatment of cutaneous sporotrichosis. *Mycopathologia* **171**:349–354.

74. Francesconi, G., A. C. Valle, S. Passos, R. Reis, and M. C. Galhardo. 2009. Terbinafine (250 mg/day): an effective and safe treatment of cutaneous sporotrichosis. *J. Eur. Acad. Dermatol. Venereol.* **23**:1273–1276.
75. Fujii, H., et al. 2008. A case of atypical sporotrichosis with multifocal cutaneous ulcers. *Clin. Exp. Dermatol.* **33**:135–138.
76. Galhardo, M. C., et al. 2010. *Sporothrix schenckii* meningitis in AIDS during immune reconstitution syndrome. *J. Neurol. Neurosurg. Psych.* **81**:696–699.
77. Garrison, R. G., K. S. Boyd, and F. Mariat. 1975. Ultrastructural studies of the mycelium-to yeast transformation of *Sporothrix schenckii*. *J. Bacteriol.* **124**:959–968.
78. Gezuele, E., and D. Da Rosa. 2005. Relevancia del cuerpo asteroide esporotricosico en el diagnostico rapido de la esporotricosis. *Rev. Iberoam. Micol.* **22**:147–150.
79. Ghosh, A., P. K. Maity, B. M. Hemashettar, V. K. Sharma, and A. Chakrabarti. 2002. Physiological characters of *Sporothrix schenckii* isolates. *Mycoses* **45**:449–454.
80. Gonzalez, G. M., A. W. Fothergill, D. A. Sutton, M. G. Rinaldi, and D. Loebering. 2005. *In vitro* activities of new and established triazoles against opportunistic filamentous and dimorphic fungi. *Med. Mycol.* **43**:281–284.
81. Gordon, M. A., E. W. Lapa, M. S. Fitter, and M. Lindsay. 1980. Susceptibility of zoopathogenic fungi to phytoalexins. *Antimicrob. Agents Chemother.* **17**:120–123.
82. Gottlieb, G. S., C. F. Lesser, K. K. Holmes, and A. Wald. 2003. Disseminated sporotrichosis associated with treatment with immunosuppressants and tumor necrosis factor-alpha antagonists. *Clin. Infect. Dis.* **37**:838–840.
83. Gremiao, I. D., et al. 2009. Intralesional amphotericin B in a cat with refractory localised sporotrichosis. *J. Feline Med. Surg.* **11**:720–723.
84. Guarro, J., J. Gene, and A. M. Stehlig. 1999. Developments in fungal taxonomy. *Clin. Microbiol. Rev.* **12**:454–500.
85. Gullberg, R. M., A. Quintanilla, M. L. Levin, J. Williams, and J. P. Phair. 1987. Sporotrichosis: recurrent cutaneous, articular, and central nervous system infection in a renal transplant recipient. *Rev. Infect. Dis.* **9**:369–375.
86. Gutierrez-Galhardo, M. C., et al. 2005. Erythema multiforme associated with sporotrichosis. *J. Eur. Acad. Dermatol. Venereol.* **19**:507–509.
87. Gutierrez-Galhardo, M. C., A. C. do Valle, et al. 2010. Disseminated sporotrichosis as a manifestation of immune reconstitution inflammatory syndrome. *Mycoses* **53**:78–80.
88. Gutierrez-Galhardo, M. C., R. M. Zancop-Oliveira, A. Monzon, J. L. Rodriguez-Tudela, and M. Cuenca-Estrella. 2010. Antifungal susceptibility profile in vitro of *Sporothrix schenckii* in two growth phases and by two methods: microdilution and E-test. *Mycoses* **53**:227–231.
89. Gutierrez-Galhardo, M. C., et al. 2002. Erythema nodosum associated with sporotrichosis. *Int. J. Dermatol.* **41**:114–116.
90. Gutierrez Galhardo, M. C., et al. 2008. Molecular epidemiology and antifungal susceptibility patterns of *Sporothrix schenckii* isolates from a cat-transmitted epidemic of sporotrichosis in Rio de Janeiro, Brazil. *Med. Mycol.* **46**:141–151.
91. Haddad, V. J., H. A. Miot, L. D. Bartoli, C. Cardoso Ade, and R. M. de Camargo. 2002. Localized lymphatic sporotrichosis after fish-induced injury (*Tilapia* sp.). *Med. Mycol.* **40**:425–427.
92. Hajjeh, R., et al. 1997. Outbreak of sporotrichosis among tree nursery workers. *J. Infect. Dis.* **176**:499–504.
93. Hampton, D. E., A. Adesina, and J. Chodosh. 2002. Conjunctival sporotrichosis in the absence of antecedent trauma. *Cornea* **21**:831–833.
94. Hardman, S., I. Stephenson, D. R. Jenkins, M. J. Wiselka, and E. M. Johnson. 2005. Disseminated *Sporothrix schenckii* in a patient with AIDS. *J. Infect.* **51**:e73–77.
95. Hektoen, L., and C. F. Perkins. 1900. Refractory subcutaneous abscess caused by *Sporothrix schenckii*: a new pathogenic fungus. *J. Exp. Med.* **5**:77–91.
96. Helm, M., and C. Berman. 1947. The clinical, therapeutic and epidemiological features of the sporotrichosis infection on the mines, p. 59–67. *In Sporotrichosis infection on mines of the Witwatersrand. Proceedings of the Transvaal Mine Medical Officers' Association*, December 1944, Johannesburg, South Africa. The Transvaal Chamber of Mines, Johannesburg, South Africa.
97. Hintz, W. E. 1999. Sequence analysis of the chitin synthase A gene of the Dutch elm pathogen *Ophiostoma novo-ulmi* indicates a close association with the human pathogen *Sporothrix schenckii*. *Gene* **237**:215–221.
98. Hirano, M., et al. 2006. A case of feline sporotrichosis. *J. Vet. Med. Sci.* **68**:283–284.
99. Hiruma, M., T. Katoh, I. Yamamoto, and S. Kagawa. 1987. Local hyperthermia in the treatment of sporotrichosis. *Mykosen* **30**:315–321.
100. Hogan, L. H., B. S. Klein, and S. M. Levitz. 1996. Virulence factors of medically important fungi. *Clin. Microbiol. Rev.* **9**:469–488.
101. Howard, D. H., and G. F. Orr. 1963. Comparison of strains of *Sporotrichum schenckii* isolated from nature. *J. Bacteriol.* **85**:816–821.
102. Howell, S. J., and J. S. Toohey. 1998. Sporotrichal arthritis in south central Kansas. *Clin. Orthop. Relat. Res.* **1998**:207–214.
103. Ishizaki, H., et al. 2009. Mitochondrial DNA analysis of *Sporothrix schenckii* in India, Thailand, Brazil, Colombia, Guatemala and Mexico. *Nippon Ishinkin Gakkai Zasshi* **50**:19–26.
104. Ishizaki, H., et al. 2004. Mitochondrial DNA analysis of *Sporothrix schenckii* from China, Korea and Spain. *Nippon Ishinkin Gakkai Zasshi* **45**:23–25.
105. Itoh, M., S. Okamoto, and H. Kariya. 1986. Survey of 200 cases of sporotrichosis. *Dermatologica* **172**:209–213.
106. Jacobson, E. S. 2000. Pathogenic roles for fungal melanins. *Clin. Microbiol. Rev.* **13**:708–717.
107. Johnson, E. M., A. Szekely, and D. W. Warnock. 1998. *In-vitro* activity of voriconazole, itraconazole and amphotericin B against filamentous fungi. *J. Antimicrob. Chemother.* **42**:741–745.
108. Kajiwara, H., M. Saito, S. Ohga, T. Uenotsuchi, and S. Yoshida. 2004. Impaired host defense against *Sporothrix schenckii* in mice with chronic granulomatous disease. *Infect. Immun.* **72**:5073–5079.
109. Kanbe, T., et al. 2005. Rapid and specific identification of *Sporothrix schenckii* by PCR targeting the DNA topoisomerase II gene. *J. Dermatol. Sci.* **38**:99–106.
110. Kano, R., Y. Nakamura, S. Watanabe, H. Tsujimoto, and A. Hasegawa. 2001. Identification of *Sporothrix schenckii* based on sequences of the chitin synthase I gene. *Mycoses* **44**:261–265.
111. Kaplan, W., J. R. Broderick, and J. N. Pacific. 1982. Spontaneous systemic sporotrichosis in nine-banded armadillos (*Dasypus novemcinctus*). *Sabouraudia* **20**:289–294.
112. Karlin, J. V., and H. S. Nielsen, Jr. 1970. Serologic aspects of sporotrichosis. *J. Infect. Dis.* **121**:316–327.
113. Kashima, T., R. Honma, S. Kishi, and J. Hirato. 2010. Bulbar conjunctival sporotrichosis presenting as a salmon-pink tumor. *Cornea* **29**:573–576.
114. Kauffman, C. A. 1999. Sporotrichosis. *Clin. Infect. Dis.* **29**:231–237.
115. Kauffman, C. A., B. Bustamante, S. W. Chapman, and P. G. Pappas. 2007. Clinical practice guidelines for the management of sporotrichosis: 2007 update by the Infectious Diseases Society of America. *Clin. Infect. Dis.* **45**:1255–1265.
116. Kazanas, N. 1986. Foodborne *Sporothrix schenckii*: infectivity for mice by intraperitoneal and intragastric inoculation with conidia. *Mycopathologia* **95**:3–16.
117. Kazanas, N., and G. J. Jackson. 1983. *Sporothrix schenckii* isolated from edible black fungus mushrooms. *J. Food Prot.* **46**:714–716.
118. Kenyon, E. M., L. H. Russell, and D. N. McMurray. 1984. Isolation of *Sporothrix schenckii* from potting soil. *Mycopathologia* **87**:128.
119. Kikuchi, I., K. Morimoto, S. Kawana, and H. Tanuma. 2006. Usefulness of itraconazole for sporotrichosis in Japan: study of three cases and literature comparison of therapeutic effects before and after release on the market. *Eur. J. Dermatol.* **16**:42–47.
120. Kohler, L. M., J. S. Hamdan, and T. C. Ferrari. 2007. Successful treatment of a disseminated *Sporothrix schenckii* infection and in vitro analysis for antifungal susceptibility testing. *Diagn. Microbiol. Infect. Dis.* **58**:117–120.
121. Kohler, L. M., P. C. Monteiro, R. C. Hahn, and J. S. Hamdan. 2004. *In vitro* susceptibilities of isolates of *Sporothrix schenckii* to itraconazole and terbinafine. *J. Clin. Microbiol.* **42**:4319–4320.
122. Kohler, L. M., B. M. Soares, D. de Assis Santos, M. E. Da Silva Barros, and J. S. Hamdan. 2006. *In vitro* susceptibility of isolates of *Sporothrix schenckii* to amphotericin B, itraconazole, and terbinafine: comparison of yeast and mycelial forms. *Can. J. Microbiol.* **52**:843–847.
123. Kong, X., T. Xiao, J. Lin, Y. Wang, and H. D. Chen. 2006. Relationships among genotypes, virulence and clinical forms of *Sporothrix schenckii* infection. *Clin. Microbiol. Infect.* **12**:1077–1081.
124. Kovarik, C. L., E. Neyra, and B. Bustamante. 2008. Evaluation of cats as the source of endemic sporotrichosis in Peru. *Med. Mycol.* **46**:53–56.
125. Kumar, R., E. van der Smissen, and J. Jorizzo. 1984. Systemic sporotrichosis with osteomyelitis. *J. Can. Assoc. Radiol.* **35**:83–84.
126. Kwon-Chung, K. J., and J. E. Bennet. 1992. *Medical mycology*. Lea & Febiger, Philadelphia, PA.
127. Kwon-Chung, K. J., W. B. Hill, and J. E. Bennett. 1981. New, special stain for histopathological diagnosis of cryptococcosis. *J. Clin. Microbiol.* **13**:383–387.
128. Lacaz, C. S., E. Porto, E. M. Heins-Vaccari, and N. T. Melo. 1998. Guia para identificação: fungos, actinomicetos e algas de interesse médico. Sarvier, São Paulo, Brazil.
129. Lacaz, C. S., E. Porto, J. E. C. Martins, E. M. Heins-Vaccari, and N. T. Melo. 2002. Tratado de micologia médica. Sarvier, São Paulo, Brazil.
130. Larone, D. H. 2002. Medically important fungi: a guide to identification, 4th ed. ASM Press, Washington, DC.
131. Latge, J. P. 1999. *Aspergillus fumigatus* and aspergillosis. *Clin. Microbiol. Rev.* **12**:310–350.
132. Lavalley, P., and F. Mariat. 1983. Sporotrichosis. *Bull. Inst. Pasteur* **81**:295–322.
133. Lima, O. C., et al. 2004. Immunofluorescence and flow cytometry analysis of fibronectin and laminin binding to *Sporothrix schenckii* yeast cells and conidia. *Microb. Pathog.* **37**:131–140.
134. Lima, O. C., et al. 1999. Adhesion of the human pathogen *Sporothrix schenckii* to several extracellular matrix proteins. *Braz. J. Med. Biol. Res.* **32**:651–657.
135. Lima, O. C., et al. 2001. Involvement of fungal cell wall components in

- adhesion of *Sporothrix schenckii* to human fibronectin. *Infect. Immun.* **69**:6874–6880.
136. Lin, J., et al. 1999. Mitochondrial DNA analysis of *Sporothrix schenckii* clinical isolates from China. *Mycopathologia* **148**:69–72.
  137. Lindsley, M. D., S. F. Hurst, N. J. Iqbal, and C. J. Morrison. 2001. Rapid identification of dimorphic and yeast-like fungal pathogens using specific DNA probes. *J. Clin. Microbiol.* **39**:3505–3511.
  138. Lloyd, K. O., and M. A. Bitoon. 1971. Isolation and purification of a peptido-rhamnomannan from the yeast form of *Sporothrix schenckii*. Structural and immunochemical studies. *J. Immunol.* **107**:663–671.
  139. Reference deleted.
  140. Loureiro y Penha, C. V., and L. M. Lopes Bezerra. 2000. Concanavalin A-binding cell wall antigens of *Sporothrix schenckii*: a serological study. *Med. Mycol.* **38**:1–7.
  141. Lutz, A., and A. Splendore. 1907. Sobre uma mycose observada em homens e ratos. *Rev. Med. São Paulo* **21**:433–450.
  142. Lyon, G. M., et al. 2003. Population-based surveillance and a case-control study of risk factors for endemic lymphocutaneous sporotrichosis in Peru. *Clin. Infect. Dis.* **36**:34–39.
  143. Mackinnon, J. E., I. A. Conti-Diaz, E. Gezele, E. Civila, and S. da Luz. 1969. Isolation of *Sporothrix schenckii* from nature and considerations on its pathogenicity and ecology. *Sabouraudia* **7**:38–45.
  144. Macotela-Ruiz, E., and E. Nochebuena-Ramos. 2006. Esporotricosis en algunas comunidades rurales de la sierra norte de Puebla: informe de 55 casos (Septiembre 1995-Diciembre 2005). *Gac. Med. Mex.* **142**:377–380.
  145. Madrid, H., et al. 2009. *Sporothrix globosa*, a pathogenic fungus with wide-spread geographical distribution. *Rev. Iberoam. Micol.* **26**:218–222.
  146. Magand, F., J. L. Perrot, F. Cambazard, M. H. Raberin, and B. Labeille. 2009. Sporotrichose cutanée autochtone française. *Ann. Dermatol. Venerol.* **136**:273–275.
  147. Maia, D. C., M. F. Sassa, M. C. Placeres, and I. Z. Carlos. 2006. Influence of Th1/Th2 cytokines and nitric oxide in murine systemic infection induced by *Sporothrix schenckii*. *Mycopathologia* **161**:11–19.
  148. Malliaris, S. D., J. N. Steenbergen, and A. Casadevall. 2004. *Cryptococcus neoformans* var. *gattii* can exploit *Acanthamoeba castellanii* for growth. *Med. Mycol.* **42**:149–158.
  149. Manohar, A., and M. N. Nizlan. 2008. Chronic nonhealing ulcer of the right thumb with multiple subcutaneous nodules. *Orthopedics* **31**:710.
  150. Marimon, R., et al. 2007. *Sporothrix brasiliensis*, *S. globosa*, and *S. mexicana*, three new *Sporothrix* species of clinical interest. *J. Clin. Microbiol.* **45**:3198–3206.
  151. Marimon, R., J. Gene, J. Cano, and J. Guarro. 2008. *Sporothrix luriei*: a rare fungus from clinical origin. *Med. Mycol.* **46**:621–625.
  152. Marimon, R., C. Serena, J. Gene, J. Cano, and J. Guarro. 2008. *In vitro* antifungal susceptibilities of five species of *Sporothrix*. *Antimicrob. Agents Chemother.* **52**:732–734.
  153. Masoko, P., L. K. Mdee, L. J. Mampuru, and J. N. Eloff. 2008. Biological activity of two related triterpenes isolated from *Combretum nelsonii* (*Combretaceae*) leaves. *Nat. Prod. Res.* **22**:1074–1084.
  154. Masoko, P., J. Picard, R. L. Howard, L. J. Mampuru, and J. N. Eloff. 2010. *In vivo* antifungal effect of *Combretum* and *Terminalia* species extracts on cutaneous wound healing in immunosuppressed rats. *Pharm. Biol.* **48**:621–632.
  155. McGinnis, M. R., N. Nordoff, R. K. Li, L. Pasarell, and D. W. Warnock. 2001. *Sporothrix schenckii* sensitivity to voriconazole, itraconazole and amphotericin B. *Med. Mycol.* **39**:369–371.
  156. Mehta, K. I., N. L. Sharma, A. K. Kanga, V. K. Mahajan, and N. Ranjan. 2007. Isolation of *Sporothrix schenckii* from the environmental sources of cutaneous sporotrichosis patients in Himachal Pradesh, India: results of a pilot study. *Mycoses* **50**:496–501.
  157. Meinerz, A. R., et al. 2007. Suscetibilidade *in vitro* de isolados de *Sporothrix schenckii* frente à terbinafina e itraconazol. *Rev. Soc. Bras. Med. Trop.* **40**:60–62.
  158. Mendes-Giannini, M. J., et al. 2006. Binding of extracellular matrix proteins to *Paracoccidioides brasiliensis*. *Microbes Infect.* **8**:1550–1559.
  159. Mendonca-Hagler, L. C., L. R. Travassos, K. O. Lloyd, and H. J. Phaff. 1974. Deoxyribonucleic acid base composition and hybridization studies on the human pathogen *Sporothrix schenckii* and *Ceratocystis* species. *Infect. Immun.* **9**:934–938.
  160. Mendoza, M., P. Alvarado, E. Diaz de Torres, L. Lucena, and M. C. de Alborno. 2005. Comportamiento fisiológico y de sensibilidad *in vitro* de aislamientos de *Sporothrix schenckii* mantenidos 18 años por dos métodos de preservación. *Rev. Iberoam. Micol.* **22**:151–156.
  161. Mendoza, M., et al. 2002. Production of culture filtrates of *Sporothrix schenckii* in diverse culture media. *Med. Mycol.* **40**:447–454.
  162. Mendoza, M., E. Diaz, P. Alvarado, E. Romero, and M. C. Bastardo de Alborno. 2007. Aislamiento de *Sporothrix schenckii* del medio ambiente en Venezuela. *Rev. Iberoam. Micol.* **24**:317–319.
  163. Mesa-Arango, A. C., et al. 2002. Phenotyping and genotyping of *Sporothrix schenckii* isolates according to geographic origin and clinical form of sporotrichosis. *J. Clin. Microbiol.* **40**:3004–3011.
  164. Migaki, G., R. L. Font, W. Kaplan, and E. D. Asper. 1978. Sporotrichosis in a Pacific white-sided dolphin (*Lagenorhynchus obliquidens*). *Am. J. Vet. Res.* **39**:1916–1919.
  165. Milby, A. H., N. D. Pappas, J. O'Donnell, and D. J. Bozentka. 2010. Sporotrichosis of the upper extremity. *Orthopedics* **16**:273–275.
  166. Miller, S. D., and J. H. Keeling. 2002. Ant sting sporotrichosis. *Cutis* **69**:439–442.
  167. Miranda, L. H., et al. 2010. Comparative histopathological study of sporotrichosis and American tegumentary leishmaniasis in dogs from Rio de Janeiro. *J. Comp. Pathol.* **143**:1–7.
  168. Mora-Cabrera, M., R. A. Alonso, R. Ulloa-Arvizu, and H. Torres-Guerrero. 2001. Analysis of restriction profiles of mitochondrial DNA from *Sporothrix schenckii*. *Med. Mycol.* **39**:439–444.
  169. Morera-Lopez, Y., J. M. Torres-Rodriguez, and T. Jimenez-Cabello. 2005. Estudio de la sensibilidad *in vitro* de aislamientos clínicos de mohos y levaduras a itraconazol y voriconazol. *Rev. Iberoam. Micol.* **22**:105–109.
  170. Morris-Jones, R. 2002. Sporotrichosis. *Clin. Exp. Dermatol.* **27**:427–431.
  171. Morris-Jones, R., et al. 2003. Synthesis of melanin-like pigments by *Sporothrix schenckii* in vitro and during mammalian infection. *Infect. Immun.* **71**:4026–4033.
  172. Nakai, T., et al. 2003. *In vitro* antifungal activity of Micafungin (FK463) against dimorphic fungi: comparison of yeast-like and mycelial forms. *Antimicrob. Agents Chemother.* **47**:1376–1381.
  173. Nascimento, R. C., and S. R. Almeida. 2005. Humoral immune response against soluble and fractionate antigens in experimental sporotrichosis. *FEMS Immunol. Med. Microbiol.* **43**:241–247.
  174. Nascimento, R. C., et al. 2008. Passive immunization with monoclonal antibody against a 70-kDa putative adhesion of *Sporothrix schenckii* induces protection in murine sporotrichosis. *Eur. J. Immunol.* **38**:3080–3089.
  175. Newton, P. N., W. H. Chung, R. Phetsouvanh, and N. J. White. 2005. Sporotrichosis, Plain of Jars, Lao People's Democratic Republic. *Emerg. Infect. Dis.* **11**:1496–1497.
  176. Nobre, M. O., et al. 2005. Differences in virulence between isolates of feline sporotrichosis. *Mycopathologia* **160**:43–49.
  177. Noriega, C. T., R. R. Garay, G. Sabanero, R. T. Basurto, and M. Sabanero-Lopez. 1993. *Sporothrix schenckii*: culturas en diferentes suelos. *Rev. Latinoam. Micol.* **35**:191–194.
  178. Odabasi, Z., V. L. Paetznick, J. R. Rodriguez, E. Chen, and L. Ostrosky-Zeichner. 2004. *In vitro* activity of anidulafungin against selected clinically important mold isolates. *Antimicrob. Agents Chemother.* **48**:1912–1915.
  179. Oliveira, M. M. E. 2009. M.Sc. thesis. Fundação Oswaldo Cruz, Rio de Janeiro, Brazil.
  180. Oliveira, M. M. E., et al. 2010. Sporotrichosis caused by *Sporothrix globosa* in Rio de Janeiro, Brazil: case report. *Mycopathologia* **169**:359–363.
  181. O'Reilly, L. C., and S. A. Altman. 2006. Macrorestriction analysis of clinical and environmental isolates of *Sporothrix schenckii*. *J. Clin. Microbiol.* **44**:2547–2552.
  182. Orellana, A., G. Moreno-Coutino, E. Poletti, M. E. Vega, and R. Arenas. 2009. Esporotricosis fija con cuerpo asteroide junto al fragmento vegetal. *Rev. Iberoam. Micol.* **26**:250–251.
  183. Palomino, J., O. Saeed, P. Daroca, and J. Lasky. 2009. A 47-year-old man with cough, dyspnea, and an abnormal chest radiograph. *Chest* **135**:872–875.
  184. Pappas, P. G., et al. 2000. Sporotrichosis in Peru: description of an area of hyperendemicity. *Clin. Infect. Dis.* **30**:65–70.
  185. Powell, K. E., et al. 1978. Cutaneous sporotrichosis in forestry workers. Epidemic due to contaminated Sphagnum moss. *JAMA* **240**:232–235.
  186. Pupo, J. A. 1917. Frecuencia da sporotrichose em São Paulo. *Ann. Paulistas Med. Cirurgia* **8**:53–68.
  187. Quintella, L. P., S. R. Lambert Passos, A. C. Francesconi do Vale, et al. 2011. Histopathology of cutaneous sporotrichosis in Rio de Janeiro: a series of 119 consecutive cases. *J. Cutan. Pathol.* **38**:25–32.
  188. Ramesh, V. 2007. Sporotrichoid cutaneous tuberculosis. *Clin. Exp. Dermatol.* **32**:680–682.
  189. Ramirez, J., R. P. Byrd, Jr., and T. M. Roy. 1998. Chronic cavitary pulmonary sporotrichosis: efficacy of oral itraconazole. *J. Ky. Med. Assoc.* **96**:103–105.
  190. Ramos-e-Silva, M., C. Vasconcelos, S. Carneiro, and T. Cestari. 2007. Sporotrichosis. *Clin. Dermatol.* **25**:181–187.
  191. Read, S. I., and L. C. Sperling. 1982. Feline sporotrichosis. Transmission to man. *Arch. Dermatol.* **118**:429–431.
  192. Reis, R. S., et al. 2009. Molecular characterisation of *Sporothrix schenckii* isolates from humans and cats involved in the sporotrichosis epidemic in Rio de Janeiro, Brazil. *Mem. Inst. Oswaldo Cruz* **104**:769–774.
  193. Reiss, E. 1986. Molecular immunology of mycotic and actinomycotic infections. Elsevier, Amsterdam, The Netherlands.
  194. Reiss, E., T. Obayashi, K. Orle, M. Yoshida, and R. M. Zancoppe-Oliveira. 2000. Non-culture based diagnostic tests for mycotic infections. *Med. Mycol. (Suppl. 1)*:147–159.
  195. Resto, S., and N. Rodriguez-del Valle. 1988. Yeast cell cycle of *Sporothrix schenckii*. *J. Med. Vet. Mycol.* **26**:13–24.
  196. Rippon, J. 1988. Sporotrichosis, p. 325–352. *In* J. Rippon (ed.), *Medical*

- mycology—the pathogenic fungi and the pathogenic actinomycetes, 3rd ed. W. B. Saunders Company, Philadelphia, PA.
197. **Rodrigues, M. L., L. Nimrichter, D. L. Oliveira, J. D. Nosanchuk, and A. Casadevall.** 2008. Vesicular trans-cell wall transport in fungi: a mechanism for the delivery of virulence-associated macromolecules? *Lipid Insights* 2:27–40.
  198. **Rodrigues, M. T., and M. A. Resende.** 1996. Epidemiologic skin test survey of sensitivity to paracoccidioidin, histoplasmin and sporotrichin among gold mine workers of Morro Velho Mining, Brazil. *Mycopathologia* 135:89–98.
  199. **Rodriguez-del Valle, N., and J. R. Rodriguez-Medina.** 1993. Calcium stimulates molecular and cellular events during the yeast-to-mycelium transition in *Sporothrix schenckii*. *J. Med. Vet. Mycol.* 31:43–53.
  200. **Rodriguez-Del Valle, N., M. Rosario, and G. Torres-Blasini.** 1983. Effects of pH, temperature, aeration and carbon source on the development of the mycelial or yeast forms of *Sporothrix schenckii* from conidia. *Mycopathologia* 82:83–88.
  201. **Rodriguez-Tudela, J. L., et al.** 2008. Method for the determination of broth dilution minimum inhibitory concentrations of antifungal agents for conidia forming moulds. EUCAST E.DEF. 9.1.
  202. **Romero-Martinez, R., M. Wheeler, A. Guerrero-Plata, G. Rico, and H. Torres-Guerrero.** 2000. Biosynthesis and functions of melanin in *Sporothrix schenckii*. *Infect. Immun.* 68:3696–3703.
  203. **Rosa, W. D., E. Gezuele, L. Calegari, and F. Goni.** 2008. Asteroid body in sporotrichosis. Yeast viability and biological significance within the host immune response. *Med. Mycol.* 46:443–448.
  204. **Rosa, W. D., E. Gezuele, L. Calegari, and F. Goñi.** 2009. Excretion-secretion products and proteases from live *Sporothrix schenckii* yeast phase: immunological detection and cleavage of human IgG. *Rev. Inst. Med. Trop. São Paulo* 51:1–7.
  205. **Rubio, G., G. Sanchez, L. Porras, and Z. Alvarado.** 2010. Esporotricosis: prevalencia, perfil clínico y epidemiológico en un centro de referencia en Colombia. *Rev. Iberoam. Micol.* 27:75–79.
  206. **Ruiz-Baca, E., et al.** 2009. Isolation and some properties of a glycoprotein of 70 kDa (Gp70) from the cell wall of *Sporothrix schenckii* involved in fungal adherence to dermal extracellular matrix. *Med. Mycol.* 47:185–196.
  207. **Ruiz-Cendoya, M., M. M. Rodriguez, M. Marine, F. J. Pastor, and J. Guarro.** 2008. *In vitro* interactions of itraconazole and miconazole against clinically important filamentous fungi. *Int. J. Antimicrob. Agents* 32:418–420.
  208. **Safdar, A.** 2003. Clinical microbiological case: infection imitating lymphocutaneous sporotrichosis during pregnancy in a healthy woman from the south-eastern USA. *Clin. Microbiol. Infect.* 9:221, 224–226.
  209. **Salaki, J. S., D. B. Louria, and H. Chmel.** 1984. Fungal and yeast infections of the central nervous system. A clinical review. *Medicine* 63:108–132.
  210. **Sanchez-Aleman, M. A., J. Araiza, and A. Bonifaz.** 2004. Aislamiento y caracterización de cepas silvestres de *Sporothrix schenckii* e investigación de reactores a la esporotricosis. *Gac. Med. Mex.* 140:507–512.
  211. **Sandhu, G. S., B. C. Kline, L. Stockman, and G. D. Roberts.** 1995. Molecular probes for diagnosis of fungal infections. *J. Clin. Microbiol.* 33:2913–2919.
  212. **Saravanakumar, P. S., P. Eslami, and F. A. Zar.** 1996. Lymphocutaneous sporotrichosis associated with a squirrel bite: case report and review. *Clin. Infect. Dis.* 23:647–648.
  213. **Sashidhara, K. V., S. P. Singh, and P. K. Shukla.** 2009. Antimicrobial evaluation of clerodane diterpenes from *Polyalthia longifolia* var. *pendula*. *Nat. Prod. Commun.* 4:327–330.
  214. **Scheinfeld, N.** 2007. A review of the new antifungals: posaconazole, micafungin, and anidulafungin. *J. Drugs Dermatol.* 6:1249–1251.
  215. **Schell, W.** 1998. Agents of chromoblastomycosis and sporotrichosis, p. 315–336. *In* L. Ajello and R. J. Hay (ed.), *Topley & Wilson's microbiology and microbial infections*, 9th ed., vol. 4. Arnold, London, United Kingdom.
  216. **Schell, W. A., I. F. Salkin, L. Pasarell, and M. R. McGinnis.** 1999. *Bipolaris, Exophiala, Scedosporium, Sporothrix* and other dematiaceous fungi, p. 1295–1317. *In* P. R. Murray, E. J. Baron, M. A. Pfaller, F. C. Tenover, and R. H. Tenover (ed.), *Manual of clinical microbiology*, 7th ed. ASM Press, Washington, DC.
  217. **Schenck, B. R.** 1898. On refractory subcutaneous abscess caused by a fungus possibly related to the Sporotricha. *Bull. Johns Hopkins Hosp.* 9:286–290.
  218. **Schubach, A., M. B. Barros, and B. Wanke.** 2008. Epidemic sporotrichosis. *Curr. Opin. Infect. Dis.* 21:129–133.
  219. **Schubach, A., M. B. de Lima Barros, T. M. Schubach, A. C. Francesconi-do-Valle, et al.** 2005. Primary conjunctival sporotrichosis: two cases from a zoonotic epidemic in Rio de Janeiro, Brazil. *Cornea* 24:491–493.
  220. **Schubach, A. O., T. M. Schubach, and M. B. Barros.** 2005. Epidemic cat-transmitted sporotrichosis. *N. Engl. J. Med.* 353:1185–1186.
  221. **Schubach, T. M., A. de Oliveira Schubach, R. S. dos Reis, et al.** 2002. *Sporothrix schenckii* isolated from domestic cats with and without sporotrichosis in Rio de Janeiro, Brazil. *Mycopathologia* 153:83–86.
  222. **Schubach, T. M., et al.** 2004. Evaluation of an epidemic of sporotrichosis in cats: 347 cases (1998–2001). *J. Am. Vet. Med. Assoc.* 224:1623–1629.
  223. **Schubach, T. M., et al.** 2006. Canine sporotrichosis in Rio de Janeiro, Brazil: clinical presentation, laboratory diagnosis and therapeutic response in 44 cases (1998–2003). *Med. Mycol.* 44:87–92.
  224. **Schubach, T. M., et al.** 2003. Haematogenous spread of *Sporothrix schenckii* in cats with naturally acquired sporotrichosis. *J. Small Anim. Pract.* 44:395–398.
  225. **Schubach, T. M., et al.** 2003. Pathology of sporotrichosis in 10 cats in Rio de Janeiro. *Vet. Rec.* 152:172–175.
  226. **Schubach, T. M., et al.** 2001. Isolation of *Sporothrix schenckii* from the nails of domestic cats (*Felis catus*). *Med. Mycol.* 39:147–149.
  227. **Schwartz, D. A.** 1989. *Sporothrix* tenosynovitis—differential diagnosis of granulomatous inflammatory disease of the joints. *J. Rheumatol.* 16:550–553.
  228. **Scott, E. N., L. Kaufman, A. C. Brown, and H. G. Muchmore.** 1987. Serologic studies in the diagnosis and management of meningitis due to *Sporothrix schenckii*. *N. Engl. J. Med.* 317:935–940.
  229. **Scott, E. N., and H. G. Muchmore.** 1989. Immunoblot analysis of antibody responses to *Sporothrix schenckii*. *J. Clin. Microbiol.* 27:300–304.
  230. **Scott, E. N., H. G. Muchmore, and D. P. Fine.** 1986. Activation of the alternative complement pathway by *Sporothrix schenckii*. *Infect. Immun.* 51:6–9.
  231. **Sgarbi, D. B., et al.** 1997. Isolation of ergosterol peroxide and its reversion to ergosterol in the pathogenic fungus *Sporothrix schenckii*. *Mycopathologia* 139:9–14.
  232. **Sia, R. A., K. B. Lengeler, and J. Heitman.** 2000. Diploid strains of the pathogenic basidiomycete *Cryptococcus neoformans* are thermally dimorphic. *Fungal Genet. Biol.* 29:153–163.
  233. **Sigler, L., et al.** 1990. Microbiology and potential virulence of *Sporothrix cyanescens*, a fungus rarely isolated from blood and skin. *J. Clin. Microbiol.* 28:1009–1015.
  234. **Silva-Vergara, M. L., et al.** 2005. Multifocal sporotrichosis with meningeal involvement in a patient with AIDS. *Med. Mycol.* 43:187–190.
  235. **Silveira, C. P., et al.** 2009. MICs and minimum fungicidal concentrations of amphotericin B, itraconazole, posaconazole and terbinafine in *Sporothrix schenckii*. *J. Med. Microbiol.* 58:1607–1610.
  236. **Singer, J. I., and J. E. Muncie.** 1952. Sporotrichosis. Etiologic considerations and report of additional cases from New York. *N. Y. State J. Med.* 52:2147–2153.
  237. **Smith, M. T., and W. H. Batenburg-Van der Vegte.** 1985. Ultrastructure in septa in *Blastobotrys* and *Sporothrix*. *Antonie Van Leeuwenhoek* 51:121–128.
  238. **Song, Y., et al.** 2011. Efficacy and safety of itraconazole pulses vs. continuous regimen in cutaneous sporotrichosis. *J. Eur. Acad. Dermatol. Venerol.* 25:302–305.
  239. **Stalkup, J. R., K. Bell, and T. Rosen.** 2002. Disseminated cutaneous sporotrichosis treated with itraconazole. *Cutis* 69:371–374.
  240. **Steenbergen, J. N., J. D. Nosanchuk, S. D. Malliaris, and A. Casadevall.** 2004. Interaction of *Blastomyces dermatitidis*, *Sporothrix schenckii*, and *Histoplasma capsulatum* with *Acanthamoeba castellanii*. *Infect. Immun.* 72:3478–3488.
  241. **Stevens, D. A.** 2002. Diagnosis of fungal infections: current status. *J. Antimicrob. Chemother.* 49(Suppl. 1):11–19.
  242. **St-Germain, G., and R. C. Summerbell.** 1996. Identifying filamentous fungi. A clinical laboratory handbook. Star Publishing Company, Belmont, CA.
  243. **Suzuki, K., M. Kawasaki, and H. Ishizaki.** 1988. Analysis of restriction profiles of mitochondrial DNA from *Sporothrix schenckii* and related fungi. *Mycopathologia* 103:147–151.
  244. **Svoboda, A., and A. Trujillo-Gonzalez.** 1990. *Sporothrix schenckii*—a freeze-fracture study. *J. Basic Microbiol.* 30:371–378.
  245. **Taboada, J.** 2000. Systemic mycoses, p. 453–476. *In* S. Ettinger and E. Feldman (ed.), *Textbook of veterinary internal medicine—diseases of the dog and cat*, 5th ed., vol. 1. W. B. Saunders Company, Philadelphia, PA.
  246. **Tachibana, T., T. Matsuyama, and M. Mitsuyama.** 1998. Characteristic infectivity of *Sporothrix schenckii* to mice depending on routes of infection and inherent fungal pathogenicity. *Med. Mycol.* 36:21–27.
  247. **Tachibana, T., T. Matsuyama, and M. Mitsuyama.** 1999. Involvement of CD4+ T cells and macrophages in acquired protection against infection with *Sporothrix schenckii* in mice. *Med. Mycol.* 37:397–404.
  248. **Takenaka, M., S. Sato, and K. Nishimoto.** 2009. Survey of 155 sporotrichosis cases examined in Nagasaki Prefecture from 1951 to 2007. *Nippon Ishinkin Gakkai Zasshi* 50:101–108.
  249. **Tateishi, T., S. Y. Murayama, F. Otsuka, and H. Yamaguchi.** 1996. Karyotyping by PFGE of clinical isolates of *Sporothrix schenckii*. *FEMS Immunol. Med. Microbiol.* 13:147–154.
  250. **Teixeira, P. A., et al.** 2010. L-DOPA accessibility in culture medium increases melanin expression and virulence of *Sporothrix schenckii* yeast cells. *Med. Mycol.* 48:687–695.
  251. **Teixeira, P. A., et al.** 2009. Cell surface expression of adhesins for fibronectin correlates with virulence in *Sporothrix schenckii*. *Microbiology* 155:3730–3738.
  252. **Tlougan, B. E., J. O. Podjasek, S. P. Patel, X. H. Nguyen, and R. C. Hansen.** 2009. Neonatal sporotrichosis. *Pediatr. Dermatol.* 26:563–565.

253. **Tobin, E. H., and W. W. Jih.** 2001. Sporotrichoid lymphocutaneous infections: etiology, diagnosis and therapy. *Am. Fam. Physician* **63**:326–332.
254. **Toledo, M. S., et al.** 2010. Effect of anti-glycosphingolipid monoclonal antibodies in pathogenic fungal growth and differentiation. Characterization of monoclonal antibody MEST-3 directed to Manpa1→3Manpa→2IPC. *BMC Microbiol.* **10**:47.
255. **Torinuki, W., and H. Tagami.** 1985. Complement activation by *Sporothrix schenckii*. *Arch. Dermatol. Res.* **277**:332–333.
256. **Torres-Guerrero, H.** 1999. Ploidy studies in *Sporothrix schenckii*. *Fungal Genet. Biol.* **27**:49–54.
257. **Trilles, L., et al.** 2005. In vitro antifungal susceptibilities of *Sporothrix schenckii* in two growth phases. *Antimicrob. Agents Chemother.* **49**:3952–3954.
258. **Uenotsuchi, T., et al.** 2006. Differential induction of Th1-prone immunity by human dendritic cells activated with *Sporothrix schenckii* of cutaneous and visceral origins to determine their different virulence. *Int. Immunol.* **18**:1637–1646.
259. **Valentin-Berrios, S., W. Gonzalez-Velazquez, L. Perez-Sanchez, R. Gonzalez-Mendez, and N. Rodriguez-Del Valle.** 2009. Cytosolic phospholipase A2: a member of the signalling pathway of a new G protein alpha subunit in *Sporothrix schenckii*. *BMC Microbiol.* **9**:100.
260. **Valle-Aviles, L., S. Valentin-Berrios, R. R. Gonzalez-Mendez, and N. Rodriguez-Del Valle.** 2007. Functional, genetic and bioinformatic characterization of a calcium/calmodulin kinase gene in *Sporothrix schenckii*. *BMC Microbiol.* **7**:107.
261. **van Duin, D., A. Casadevall, and J. D. Nosanchuk.** 2002. Melanization of *Cryptococcus neoformans* and *Histoplasma capsulatum* reduces their susceptibilities to amphotericin B and caspofungin. *Antimicrob. Agents Chemother.* **46**:3394–3400.
262. **Vicentini, A. P., et al.** 1994. Binding of *Paracoccidioides brasiliensis* to laminin through surface glycoprotein gp43 leads to enhancement of fungal pathogenesis. *Infect. Immun.* **62**:1465–1469.
263. **Vilela, R., G. F. Souza, G. Fernandes Cota, and L. Mendoza.** 2007. Cutaneous and meningeal sporotrichosis in a HIV patient. *Rev. Iberoam. Micol.* **24**:161–163.
264. **Wenker, C. J., L. Kaufman, L. N. Bacciarini, and N. Robert.** 1998. Sporotrichosis in a nine-banded armadillo (*Dasypus novemcinctus*). *J. Zoo Wildl. Med.* **29**:474–478.
265. **Woods, J. P.** 2003. Knocking on the right door and making a comfortable home: *Histoplasma capsulatum* intracellular pathogenesis. *Curr. Opin. Microbiol.* **6**:327–331.
266. **Xu, T. H., et al.** 2010. Identification of *Sporothrix schenckii* of various mtDNA types by nested PCR assay. *Med. Mycol.* **48**:161–165.
267. **Xue, S. L., and L. Li.** 2009. Oral potassium iodide for the treatment of sporotrichosis. *Mycopathologia* **167**:355–356.
268. **Yang, D. J., et al.** 2006. Disseminated sporotrichosis mimicking sarcoidosis. *Int. J. Dermatol.* **45**:450–453.
269. **Yegneswaran, P. P., et al.** 2009. Zoonotic sporotrichosis of lymphocutaneous type in a man acquired from a domesticated feline source: report of a first case in southern Karnataka, India. *Int. J. Dermatol.* **48**:1198–1200.
270. **Zarnowski, R., and J. P. Woods.** 2005. Glutathione-dependent extracellular ferric reductase activities in dimorphic zoopathogenic fungi. *Microbiology* **151**:2233–2240.
271. **Zhang, X., and J. H. Andrews.** 1993. Evidence for growth of *Sporothrix schenckii* on dead but not on living sphagnum moss. *Mycopathologia* **123**:87–94.

**Mônica Bastos de Lima Barros** obtained her medical degree from the Federal University of the State of Rio de Janeiro, Brazil, in 1984. She completed her residency in public health at Oswaldo Cruz Foundation and subsequently her M.Sc. and Ph.D. degrees in infectious diseases from the Federal University of Rio de Janeiro. Her thesis was on sporotrichosis and the first description of an epidemic due to zoonotic transmission. During the past 10 years she has gained broad experience in the clinical aspects, epidemiology, treatment, and prevention of sporotrichosis. She works as a researcher and professor at the Oswaldo Cruz Foundation, affiliated with the Ministry of Health, developing studies in infectious diseases.



**Rodrigo Almeida Paes** obtained his undergraduate degree from the Federal University of the State of Rio de Janeiro, Brazil, in 2004. Since 2002 he has worked at the Oswaldo Cruz Foundation, where he completed his M.Sc. degree in cellular and molecular biology in 2007. He is now a Ph.D. student, working on several aspects of *S. schenckii* virulence. He is also the supervisor of the Mycological Diagnosis section of the Mycology Laboratory of the Oswaldo Cruz Foundation and teaches medical mycology to technicians and undergraduate students.



**Armando de Oliveira Schubach** obtained his medical degree from the University of the State of Rio de Janeiro, Brazil, in 1980, a specialization in dermatology from the Federal University of the State of Rio de Janeiro in 1990, an M.Sc. degree in tropical medicine from the Oswaldo Cruz Foundation (Fiocruz) in 1990, and a Ph.D. degree in parasite biology from Fiocruz in 1997. He is currently a senior researcher at the Evandro Chagas Clinical Research Institute (IPEC/Fiocruz), coordinator of the Laboratory of Leishmaniasis Surveillance at IPEC/Fiocruz, coordinator of the Postgraduation Program in Clinical Research in Infectious Diseases of IPEC/Fiocruz, Level 2 researcher of the National Council of Scientific and Technological Development (CNPq), leader of the Parasitic Diseases (CNPq) research group, and a “Scientist of Our State” from the Foundation for Research of Rio de Janeiro (FAPERJ). He has experience in the study of infectious and parasitic diseases, mainly the clinical, diagnostic, treatment, and epidemiological aspects of sporotrichosis and leishmaniasis.

