



Case Report

Cluster of leptospirosis cases among military personnel in Rio de Janeiro, Brazil

Otilia Lupi^{a,*}, Marco Antonio Carvalho Netto^b, Katia Avelar^c, Carolina Romero^d,
Robson Bruniera^a, Patricia Brasil^d

^a Center for Strategic Information in Health Surveillance, Oswaldo Cruz Foundation, Rio de Janeiro, RJ 21.040-900, Brazil

^b Municipal Department of Epidemiological Surveillance, Resende, Brazil

^c Oswaldo Cruz Institute, Oswaldo Cruz Foundation, Rio de Janeiro, Brazil

^d Evandro Chagas Institute of Clinical Research, Oswaldo Cruz Foundation, Rio de Janeiro, Brazil

ARTICLE INFO

Article history:

Received 24 October 2012

Accepted 31 October 2012

Corresponding Editor: Eskild Petersen, Skejby, Denmark

Keywords:

Brazil

Leptospira

Leptospirosis

Military troops

Rural areas

SUMMARY

We report two cases of leptospirosis in military personnel in southeastern Brazil. The cases were hospitalized following field training exercises, and presented with acute meningoencephalitis, respiratory illnesses, and skin rash. *Leptospira interrogans* serovars Icterohaemorrhagiae, Hebdomadis, Patoc, and Cynopteri were identified in the cases by microscopic agglutination test and PCR.

© 2012 International Society for Infectious Diseases. Published by Elsevier Ltd. All rights reserved.

1. Introduction

Leptospirosis, a spirochetal zoonotic disease, has been recognized as an important emerging global public health problem because of its increasing incidence in both developing and developed countries in the last 10 years. A number of leptospirosis outbreaks have recently occurred around the world as a result of occupational exposure, recreational activities, and natural calamities such as earthquakes, hurricanes, and floods.^{1,2}

Leptospirosis has spread from its traditional rural base to cause epidemics in poor-income urban communities in developing countries. The disease is endemic in Brazil, with a higher incidence during times of heavy rain and flooding. Between 2001 and 2008, a mean of 3416 new cases of leptospirosis were reported annually to the Brazilian health authorities (Figure 1). In 2008, 183 leptospirosis cases, with 42 deaths (mortality rate of 22.9%), were confirmed in the state of Rio de Janeiro, reflecting the national strategy of surveillance based on admitted patients.³

Most leptospiral infections are either subclinical or result in a very mild illness followed by recovery without complications. However, a small proportion of patients develop complications due to multiple organ involvement. The case–fatality ratio varies for

the severe disease forms, such as Weil's disease (>10%) and severe pulmonary hemorrhage syndrome (>50%), even when optimal treatment is provided.^{1,3}

Neurological manifestations have been described during the immune phase of disease. Aseptic meningitis occurs in nearly 25% of all leptospirosis cases; other rare neurological complications include cerebrovascular accidents and Guillain–Barré syndrome, as well as cerebral arteritis, which resembles Moyamoya disease.^{1,4} Because of the protean manifestations of leptospirosis, it is often misdiagnosed and under-reported, leading to underestimated official numbers.^{1,3}

There is currently no human vaccine available for leptospirosis. As such, effective preventive measures guided by an understanding of the eco-epidemiology of the reservoir involved in local transmission, consideration of chemoprophylaxis when possible, and optimization of specific diagnostic and therapeutic methods are essential.¹

Here, we report a cluster of febrile acute cases of leptospirosis with neurological manifestations in military recruits during training in the state of Rio de Janeiro. Training occurred in the vicinity of the city of Resende (Figure 1), in the Paraíba do Sul river valley in southern Rio de Janeiro state on the border of Itatiaia National Park and the Funil Dam, where the Brazilian Military Academy of Agulhas Negras is located. The region has a high tropical area with a temperature range of 1–26 °C and rainfall of 230 mm in October, when the rainy season begins.

* Corresponding author.

E-mail address: otilia.lupi@ipecc.fiocruz.br (O. Lupi).

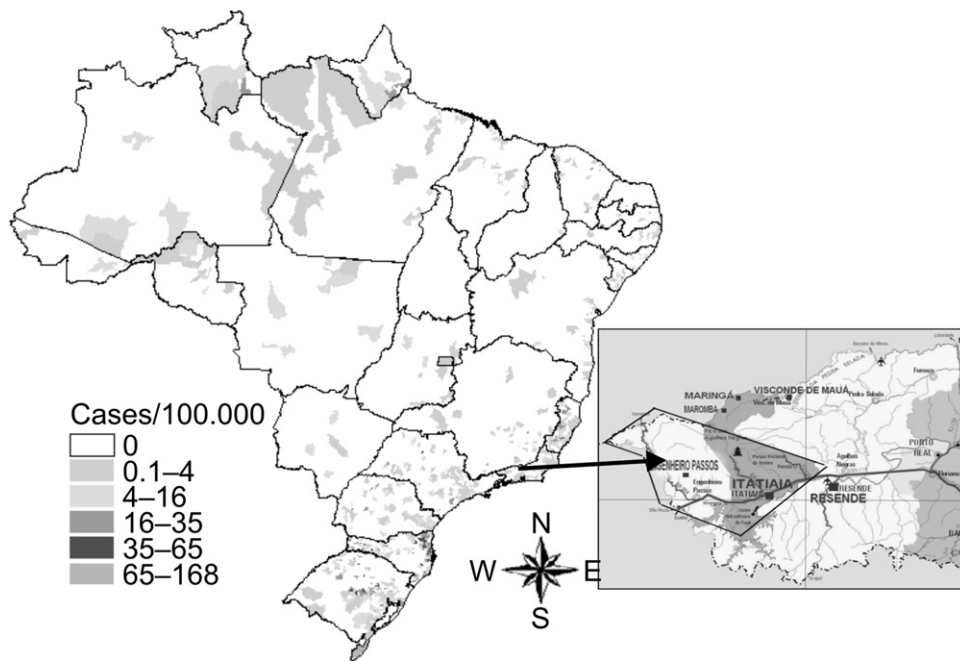


Figure 1. Incidence of leptospirosis cases by municipality in Brazil, 2006–2008, and a regional map showing the Military Academy of Agulhas Negras (AMAN), Itatiaia National Park, and Funil Dam.

During November 2009, Resende health officials, in collaboration with federal researchers from the Oswaldo Cruz Foundation (FIOCRUZ), investigated reports of febrile encephalitic and respiratory illnesses among military personnel who had participated in the training. Four cases were reported. Two of these cases were hospitalized 12 days after returning from field training exercises due to an acute febrile illness with meningitis, headache, myalgia, mild conjunctival hyperemia, and a cutaneous rash. The other two ill recruits, who were not admitted but identified among the nearly 200 men, were not further investigated due to their return to other Brazilian states. Dengue fever was the initial diagnosis in these cases, but the predominance of neurological signs and known exposure to ticks and a water reservoir suggested a different cause, such as viral hepatitis, malaria, babesiosis, ehrlichiosis, or Brazilian spotted fever.

Although military personnel are considered at high risk and this academy has been using the area for many years, there were no other confirmed cases of leptospirosis prior to this cluster. This may reflect the diagnostic challenge of nonspecific febrile syndromes, which frequently remain misdiagnosed.

2. Case reports

2.1. Case 1

A 23-year-old male presented to the hospital with a fever of 38.9 °C, headache, conjunctival hyperemia, myalgia, malaise, and arthralgia. During the physical examination, he exhibited a body temperature of 38.8 °C, blood pressure of 120/80 mmHg, pulse of 80 bpm, eupneic respiration, no adenopathy, and was anicteric. On day 9 following hospital admission, the patient presented with pleural effusion and splenomegaly. A chest X-ray revealed a diffuse, ill-defined ground glass density in the base of the left lung. Empirical treatment with doxycycline was initiated on day 9. The microscopic agglutination test (MAT) was strongly positive on day 12 for *Leptospira interrogans* serovars Icterohaemorrhagiae (1:400), Hebdomadis (1:100), and Patoc (1:400) and on day 28 for Hebdomadis (1:200), Icterohaemorrhagiae (1:100), and Patoc (1:400). The fever disappeared on day 12. On day 9, hematology

tests indicated moderate leukocytosis with neutrophilia, lymphopenia, and thrombocytopenia. Biochemical tests indicated mild hypokalemia with normal serum creatinine and blood urea nitrogen (BUN). Hepatic function tests showed two times the normal levels of serum alanine aminotransferase (ALT) as well as elevated γ -glutamyltransferase (GGT), but normal bilirubin. The liquoric profile showed mild lymphocytic pleocytosis and normal cerebrospinal fluid (CSF) glucose and protein levels. Results of PCR on blood and CSF samples were negative for *Leptospira spp.* Direct bacteriological examination and cultures were negative. A cranial computerized tomography (CT) scan was normal. After 6 weeks, the patient had completely recovered and had normal X-rays and hematological and biochemical parameters.

2.2. Case 2

A 20-year-old male was hospitalized with a continuous fever of 38.5–39 °C, a strong headache, and vomiting. Upon physical examination, his body temperature was 38.5 °C, blood pressure was 130/70 mmHg, pulse was 72 bpm, and he displayed signs of meningismus without altered sensorium (Glasgow coma scale score of 15). A cranial CT scan showed signs of supratentorial hydrocephalus and the liquoric profile showed mild lymphocytic pleocytosis and normal CSF glucose and protein levels. Direct bacteriological examination and cultures were negative. Hematology tests showed moderate leukocytosis with neutrophilia, lymphopenia, and thrombocytopenia. Biochemical tests demonstrated mild hypokalemia with normal serum creatinine and BUN; hepatic function was normal. Empirical treatment with doxycycline was initiated on day 10. The MAT was strongly positive for *L. interrogans* serovars Cynopteri (1:400) and Patoc (1:200) on day 18 and was positive for Cynopteri (1:6400) and Patoc (1:600) on day 28. PCR for *Leptospira spp.* was positive in both blood and CSF on day 16. The hydrocephalus continued for 4 weeks and a new puncture was required for relief. The case was followed for 6 months with complete resolution of the hydrocephalus as determined by magnetic resonance imaging.

Extensive etiological research was conducted in both cases. Serological and/or molecular tests were negative for dengue fever,

yellow fever, hantavirus, babesiosis, ehrlichiosis, Brazilian spotted fever, typhoid fever, cytomegalovirus, and hepatitis A, B, and C viruses. All thick blood smears for malaria and babesiosis were negative.

3. Discussion

Leptospirosis occurs in urban environments of industrialized and emerging countries, as well as in rural regions worldwide. Several outbreaks and clusters of leptospirosis have recently been described, demonstrating the importance of this widespread zoonotic disease. Mortality remains significant due to delays in diagnosis because of a lack of infrastructure and adequate clinical suspicion, as well as other poorly understood factors, including the inherent pathogenicity of some leptospiral strains and genetically-determined host immunopathological responses. Prevention of leptospirosis may be achieved by avoiding high-risk exposure, the adoption of protective measures, and the use of chemoprophylaxis, depending upon the environment and degree of human activity.^{1–3}

This study describes the first outbreak of leptospirosis among military troops during training in the mountainous southeast region of Brazil. Investigation of this cluster showed significantly elevated neurological manifestations, such as aseptic meningitis, representing 50% of acute febrile illness cases. A serovar identified in one of the cases, *Cynopteri* (the genomospecies associated *Leptospira santarosai* and *Leptospira kirschneri*), is an uncommon variant encountered in urban areas of Rio de Janeiro state. In tropical and subtropical, wet, rural areas, many serovars infect humans and animals, and a large number of reservoir species are present, including rodents, farm animals, and dogs.^{1,5}

Our hypothesis is that the anthropic environment present within the Military Academy of Agulhas Negras, Funil Dam, and the Itatiaia National Park, with fields and the remains of a rain forest, is home to many potential *Leptospira* reservoir species which may have caused the cluster of cases presented here.^{1,2,5}

Although major progress has been made regarding the basic research of leptospirosis, the translation of these advances into

public health measures for emerging countries remains a challenge. Yet, in slum areas, the most effective responses may be interventions that directly address the social determinants of poverty, such as poor sanitation, which are often responsible for transmission.

Moreover, the overall disease burden is currently underestimated because leptospirosis is a significant cause of undifferentiated fever and frequently goes unrecognized. Barriers to addressing this problem have been the lack of an adequate diagnostic test and effective control measures.^{1,3}

Acknowledgements

We thank the staff of the Department of Neurosurgery at the Central Army Hospital, Rio de Janeiro.

Funding: This research was funded by an internal grant from the Fundação Oswaldo Cruz (FIOTEC VPAAPS 006LIV 10-02-08). The funders had no role in the study design, data collection, analysis, decision to publish, or preparation of the manuscript.

Ethical approval: All study participants provided informed consent, and the study design was approved by the appropriate ethics review boards.

Conflict of interest: The authors declare no conflict of interest.

References

- Hartskeerl RA, Collares-Pereira M, Ellis WA. Emergence, control and re-emerging leptospirosis: dynamics of infection in the changing world. *Clin Microbiol Infect* 2011;**17**:494–501.
- Russel KL, Gonz ales MA, Watts DM. An outbreak of leptospirosis among Peruvian military recruits. *Am J Trop Med Hyg* 2003;**69**:53–7.
- Brazilian Ministry of Health. Epidemiological situation of zoonosis with interest for public health. *Electronic Epidemiological Bulletin* 10, No. 2, April 2010. Brazil: Secretaria de Vigil ncia em Sa de, Minist rio da Sa de; 2010. Available at: http://portal.saude.gov.br/portal/arquivos/pdf/ano10_n02_sit_epidemiol_zoonoses_br.pdf (accessed).
- Sanjee J, Mohd KA. Leptospirosis presenting as acute meningoencephalitis. *J Infect Dev Ctries* 2010;**4**:179–82.
- Lins ZC, Lopes ML. Isolation of *Leptospira* from wild forest animals in Amazonian Brazil. *Trans R Soc Trop Med Hyg* 1984;**78**:124–6.