

# Successful Treatment of Canine Sporotrichosis with Terbinafine: Case Reports and Literature Review

Paula Gonçalves Viana · Anna Barreto Fernandes Figueiredo · Isabella Dib Ferreira Gremião · Luisa Helena Monteiro de Miranda · Isabela Maria da Silva Antonio · Jéssica Sepulveda Boechat · Ana Caroline de Sá Machado · Manoel Marques Evangelista de Oliveira · Sandro Antonio Pereira

Received: 27 June 2017 / Accepted: 10 November 2017 / Published online: 8 December 2017  
© Springer Science+Business Media B.V., part of Springer Nature 2017

**Abstract** Sporotrichosis occurs worldwide, and the metropolitan region of Rio de Janeiro, Brazil, is a main endemic area, with a large number of human and animal cases in the last 19 years. This mycosis is more frequently described in cats rather than in dogs. There are a limited number of oral antifungal agents for the treatment of sporotrichosis in animals. In this context, the effectiveness of terbinafine in the treatment of sporotrichosis in humans, as well as the promising results of in vitro susceptibility tests, inspired us to use this drug in the therapy of this mycosis in dogs. We reported for the first time the use of terbinafine in the treatment of two dogs with sporotrichosis caused by *Sporothrix brasiliensis*. Moreover, we provided an overview of therapeutic features of canine sporotrichosis cases reported since the 1960s. One of the dogs presented the fixed cutaneous form of the disease,

while the other patient presented hyperemia of the nasal mucosa and respiratory signs only. Terbinafine showed high antifungal activity in vitro against the canine *Sporothrix* isolates. The dogs were successfully treated with terbinafine, with remission of all clinical signs initially presented. The current reports indicate that this drug can emerge as a therapeutic option for canine sporotrichosis.

**Keywords** *Sporothrix brasiliensis* · Dogs · Terbinafine · Therapy

## Introduction

Sporotrichosis is a subcutaneous mycosis caused by thermodimorphic pathogenic species of the genus *Sporothrix* [1]. This disease occurs worldwide, and the metropolitan region of Rio de Janeiro, located in the southeast region of Brazil, is a main endemic area, with a large number of human and animal cases in the last 19 years [2, 3]. In this country, the most prevalent etiological agent of sporotrichosis is *Sporothrix brasiliensis* [4].

Canine sporotrichosis cases are minimal compared to the number of feline cases. Most documented cases in dogs have been from France, USA, Canada, Italy, and especially in Brazil, where the highest number has been reported thus far [3, 5–9].

In dogs, the infection can be acquired during hunting activities with the possible introduction of

---

P. G. Viana (✉) · A. B. F. Figueiredo ·  
I. D. F. Gremião · L. H. M. de Miranda ·  
I. M. da Silva Antonio · J. S. Boechat ·  
A. C. de Sá Machado · M. M. E. de Oliveira ·  
S. A. Pereira

Laboratory of Clinical Research on Dermatозoonosis in Domestic Animals, Evandro Chagas National Institute of Infectious Diseases, Fiocruz, Avenida Brasil, 4365, Manguinhos, Rio de Janeiro 21040-360, Brazil  
e-mail: paulaviana.veterinaria@gmail.com

M. M. E. de Oliveira  
Laboratory of Mycology, Evandro Chagas National Institute of Infectious Diseases, Fiocruz, Avenida Brasil, 4365, Manguinhos, Rio de Janeiro 21040-360, Brazil

*Sporothrix* sp. through thorns or wood splinters [10]. However, in Rio de Janeiro, approximately 80% of the cases was because of the dogs being in contact with infected cats [6]. To date, there have been no reports of zoonotic transmission of *Sporothrix* sp. from infected dogs in Rio de Janeiro [3].

The cutaneous form of sporotrichosis, with ulcers and/or nodules on the head, ears, neck, back, and thorax, is the most frequently reported in dogs [11]. However, in some cases, cutaneous lesions might not be present [8]. Extracutaneous signs, particularly respiratory signs (sneezing, dyspnea, and nasal discharge), are frequent, and oftentimes related to nasal mucosa lesions [12]. The occurrence of masses protruding from the nostrils can be observed. In addition, most of the cases had presented lymphadenitis, while lymphangitis was uncommon [6, 9]. Rare forms of sporotrichosis that can develop in dogs include osteoarticular and disseminated forms [9, 13, 14].

Oral itraconazole, ketoconazole, and potassium iodide are the most common drugs used for the treatment of canine sporotrichosis [11]. Terbinafine is an allylamine antifungal agent, which inhibits squalene epoxidase resulting in ergosterol deficiency of the cell wall and intracellular squalene accumulation leading to the death of the fungal cell [15]. This drug is recommended for dermatophytosis [16] and chromoblastomycosis treatment in humans [17, 18]. Reports in dogs involving terbinafine were focused solely on the treatment of malasseziasis and dermatophytosis [19, 20].

So far the therapeutic potential of terbinafine for sporotrichosis has been confirmed in human patients [21, 22], and it is especially important when the use of itraconazole is not indicated due to the interaction with other drugs in patients with underlying diseases [21]. At this time, the effectiveness of terbinafine in the treatment of animal sporotrichosis is not known. In contrast, *in vitro* activity has proven to be effective against *Sporothrix* sp. isolates from humans, dogs, and cats [23–25]. Because of this, terbinafine should be considered a potential alternative for the treatment of animal sporotrichosis. Therefore, we report for the first time the use of terbinafine in the treatment of two dogs with sporotrichosis.

## Case Reports

Two mongrel dogs, from the metropolitan area of Rio de Janeiro, RJ, Brazil, were presented to the Laboratory of Clinical Research on Dermatозoonosis in Domestic Animals (Lapclin-Dermzoo), Evandro Chagas National Institute of Infectious Diseases (INI)/Oswaldo Cruz Foundation (Fiocruz), Rio de Janeiro. These dogs were castrated, in good overall condition, and with suspicion of sporotrichosis.

The animals underwent a clinical examination and blood collection for hematological and biochemical analyses (urea, creatinine, alanine aminotransferase, aspartate aminotransferase, alkaline phosphatase, total protein, albumin, and globulin). In addition, biological samples from the dogs were collected for fungal culture. Blood collection and consecutive analyses were performed during and after the antifungal treatment.

### Case 1

The 1-year-old dog was a female, weighing 10 kg. The animal was referred to us by a veterinary dermatologist due to the presence of a persistent skin lesion for 12 weeks. The dog did not have contact with any cats. And another dog in the same household did not present any lesion.

During the clinical examination, an ulcerated skin lesion was found on the right lower abdomen area (Fig. 1). The exudate from the lesion was collected by sterile swab and submitted for a routine mycological examination [6]. No relevant alterations were identified in routine hematology or serum biochemistry panels.

Sporotrichosis was confirmed by the isolation of *Sporothrix* sp. from the exudate of the skin lesion. This isolate was identified by means of genotypic testing. The genomic DNA was extracted from the mycelial phase, and the isolate was identified using T3B PCR fingerprinting to distinguish between the species of the genus *Sporothrix* [26, 27]. Strains of the genus *Sporothrix* associated with clinical cases in humans and animals: *S. brasiliensis* (IPEC16490), *S. globosa* (IPEC27135), *S. mexicana* (MUM11.02), and *S. schenckii* (IPEC27722) were used as controls for molecular identification. T3B PCR fingerprinting identified the isolate (IPEC14245Z) as *S. brasiliensis*.

The antifungal susceptibility tests were conducted according to the M38-A2 protocol of the Clinical and Laboratory Standards Institute (CLSI) [28]. Amphotericin B (AMB), terbinafine (TRB), posaconazole (POS), ketoconazole (KTZ), and itraconazole (ITZ) (Sigma Chemical Corporation, St. Louis, MO, USA) were tested. The in vitro antifungal activity tests showed minimum inhibitory concentration (MIC) values for AMB (4.0 µg/mL), TRB (0.06 µg/mL), POS (1.0 µg/mL), KTZ (0.25 µg/mL), and ITZ (0.5 µg/mL).

Oral terbinafine tablets (25 mg/kg) were prescribed once a day with food. The dog was followed up monthly for clinical evaluation and assessment of hematological and biochemical parameters. The clinical cure was achieved at 12 weeks of antifungal therapy, as the animal had no active lesion, merely a scar on the abdomen area (Fig. 1). The drug was well tolerated, and no clinical or laboratory adverse effects were observed.

The patient returned for an evaluation 23 weeks after discharge. The dog presented in a good overall condition and had no clinical signs of sporotrichosis. No relevant alterations were identified in full blood examination and serum biochemical analysis.

## Case 2

The 2-year-old animal was a male, weighing 8.2 kg had a history of respiratory signs in the last year and lived in the same household with cats and his owner, who was previously diagnosed with sporotrichosis.

Inspiratory dyspnea, sneezing, nasal discharge, increased mandibular lymph nodes, and hyperemia

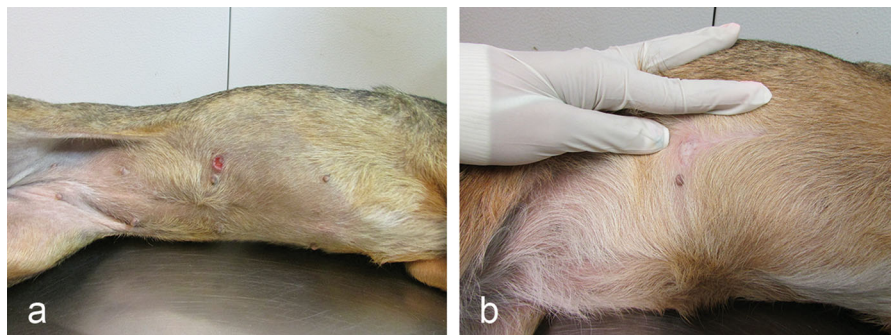
in both nostrils were observed during the clinical examination. Skin lesions were not present. No changes were observed in the hematological and serum biochemical analyses.

Nasal secretion was collected by sterile swab for mycological examination. As in Case 1, the diagnosis of sporotrichosis was confirmed by the isolation of *Sporothrix* sp. in culture, and the result of T3B PCR fingerprinting identified this isolate (IPEC10949) also as *S. brasiliensis*. The in vitro antifungal activity tests showed MIC values for AMB (4.0 µg/mL), TRB (0.06 µg/mL), POS (1.0 µg/mL), KTZ (0.5 µg/mL), and ITZ (0.5 µg/mL).

Terbinafine tablets (30 mg/kg) were prescribed once a day with food. Clinical follow-up was carried out monthly, as well as the evaluation of laboratorial parameters including complete blood count and serum biochemical analysis.

The respiratory signs ceased after 4 weeks of antifungal treatment. Posteriorly, at the 11th week of treatment, the hyperemia in the nostrils was no longer observed. Mandibular lymphadenomegaly regressed at 15 weeks. After the disappearance of all the clinical signs initially presented, the treatment was maintained for another 4 weeks (totaling 19 weeks), and the animal was discharged. Terbinafine was well tolerated, and no adverse effects were detected during the treatment, moreover no relevant alterations were identified in routine hematology or serum biochemistry panels.

Three months after discharge, the dog returned for an evaluation, and no clinical signs of sporotrichosis were detected. Collection of nasal secretion and blood was performed, and there was no fungal growth, as



**Fig. 1** **a** Dog with sporotrichosis presenting an ulcerated skin lesion on the right lower abdomen area before antifungal treatment. **b** The same skin lesion has resolved after 12 weeks of terbinafine treatment

well as no relevant alterations in hematological and serum biochemistry analyses.

## Discussion

Sporotrichosis is a sporadic disease in dogs, and the current knowledge about this mycosis, including therapeutic response, has been obtained from the review of a few isolated cases and the data from the Rio de Janeiro epizootic (Table 1). Both dogs lived in areas with the heavy transmission of *Sporothrix* sp. In Case 1, it was not possible to determine the source of the infection, whereas in Case 2, the dog came into contact with infected cats of the same domicile.

The identification of canine *Sporothrix* strains at the molecular level is not common. *Sporothrix brasiliensis* was the etiological agent of the cases herein presented, and this was the first description of this species in dogs from Rio de Janeiro. The agent was also identified in a few cases from São Paulo and Rio Grande do Sul states, Brazil [1].

Nowadays, there are a limited number of oral antifungal agents for the treatment of sporotrichosis in animals. In this context, the promising results of *in vitro* susceptibility tests, as well as the effectiveness of terbinafine in the treatment of sporotrichosis in humans, inspired us to use this drug in the therapy of this mycosis in dogs. To the best of our knowledge, the use of terbinafine to treat a dog with sporotrichosis has not been described previously.

Significant differences in antifungal susceptibilities have been observed among the four pathogenic species of the genus *Sporothrix*. In general, antifungal drugs show a good response against *Sporothrix* isolates from Brazil, especially terbinafine [23, 47–50]. In our reports, terbinafine was effective *in vitro* and *in vivo*, with remission of all clinical signs initially presented, as previously described in most cases of sporotrichosis in humans treated with this drug [21, 22, 51–54].

The presence of hyperemia in the nasal mucosa and respiratory signs in the absence of skin lesions were observed in Case 2. Despite the occurrence of skin lesions being commonly described in canine sporotrichosis [6], dogs with nasal involvement with no cutaneous disease are described at a lower rate [8].

Treatment of canine sporotrichosis has historically involved oral administration of potassium or sodium

iodide. In another case report, a dog with cutaneous involvement was treated with saturated solution of potassium iodide [33]. Although the treatment time until the clinical cure was shorter than the dog reported in Case 1, the animal presented adverse effects like weight loss, anorexia, and diarrhea.

The use of ketoconazole and itraconazole to treat dogs with sporotrichosis has been reported, and the duration of the treatment ranged from 8 to 60 weeks and 8 to 20 weeks, respectively [6, 42, 45]. The length of treatment until discharge in the cases reported here was similar to itraconazole treatment time range described above. The presence of hyperemia and respiratory signs in Case 2 might have contributed to the longer time period of treatment in relation to the dog that presented only the skin lesion (Case 1), since the nasal mucosa involvement is typically linked to hard-to-treat lesions [55] and to life-threatening sporotrichosis in cats [56]. Although this correlation is not confirmed in the canine disease, the treatment with terbinafine was successful in Case 2, leading to an optimistic outlook for further studies with this drug.

To the authors' knowledge, in the other only case of intranasal canine sporotrichosis, the animal presented sneezing, nasal congestion, and loss of smell. The dog was treated with oral itraconazole. Pulse therapy with the same drug was chosen following the initial therapy due to the clinical adverse effects related to the azole [8]. In Case 2, treatment time to clinical cure was shorter, and no clinical, nor laboratory adverse effects were observed.

The occurrence of gastrointestinal adverse effects (GAE) such as anorexia, vomiting, or diarrhea, as well as the increase of hepatic enzymes, was described in canine sporotrichosis cases treated with azolic antifungal agents [6]. In dogs with dermatophytosis and malasseziasis treated with terbinafine (20–30 mg/kg/day), the occurrence of GAE was low [57, 58], and the increase of alanine aminotransferase was transient, with parameters back to normal 1 week after discharge [58].

In the cases described here, terbinafine was well tolerated with no clinical adverse effects and no relevant hematological and biochemical changes associated with the treatment. At the moment of reevaluation, the dogs' overall condition was good and had no clinical signs consistent with the disease.

Despite these encouraging outcomes, we are aware that terbinafine's excellent *in vitro* susceptibility tests

**Table 1** Therapeutic features of canine sporotrichosis cases, confirmed by isolation of *Sporothrix* sp. in culture, reported since 1963

Year	Authors	Origin	Types of studies	N	Drugs	Adverse effects	Outcome
1963–1964	Migliano et al. [29]	Brazil	Case report	2	GSF/KI	None	Clinical cure/relapse
1964	Londero et al. [30]	Brazil	Case report	2	KI	None	Clinical cure
1965	Freitas et al. [31]	Brazil	Case series	12	KI	Not reported	Loss of follow-up
1971	Berry et al. [32]	USA	Case report	1	KI	None	Clinical cure
1971	Koehne et al. [33]	USA	Case report	1	KI	Diarrhea, weight loss, anorexia	Clinical cure
1974	Scott et al. [34]	USA	Case report	3	NaI	None	Clinical cure
1978	Dion et al. [35]	Canada	Case report	1	KI	Constipation and hyporexia	Clinical cure
1980	Woodard [36]	USA	Case report	1	NaI	None	Clinical cure
1986	Goad e Goad [37]	USA	Case report	1	KTZ	None	Clinical cure
1988	Iwasaki e al. [38]	Brazil	Case report	1	NaI	None	Clinical cure
1988	Moriello et al. [39]	USA	Case report	1	NaI	None	Clinical cure
1992	Sanford [40]	Canada	Case report	1	KI/KTZ	None	Relapse
2001	Sykes et al. [13]	USA	Case report	1	ITZ	Increased hepatic enzyme	Clinical cure
2006	Schubach et al. [6]	Brazil	Case series	37	KTZ/ITZ	Anorexia, vomit, diarrhea, increased hepatic enzymes, vasculitis (only ITZ)	Clinical cure/loss of follow-up
2007	Bernstein et al. [41]	USA	Case report	1	ITZ	None	Clinical cure
2007	Cafarchia et al. [7]	Italy	Case report	1	ITZ	None	Loss of follow-up
2007	Madrid et al. [42]	Brazil	Case report	3	ITZ	None	Clinical cure
2007	Whittemore et al. [8]	USA	Case report	1	ITZ	Hyporexia, weight loss	Clinical cure
2009	Crothers et al. [9]	USA	Case series	4	KTZ/ITZ/NaI then KTZ	Anorexia (only KTZ)	Clinical cure
2009	Filgueira [43]	Brazil	Case report	1	ITZ	None	Loss of follow-up
2012	Grassani et al. [44]	Brazil	Case report	1	KTZ/ITZ/ITZ + KI	None	Clinical cure
2013	Rossi et al. [45]	Brazil	Case series	3	ITZ	None	Clinical cure/relapse
2014	Guterres et al. [46]	Brazil	Case report	1	ITZ/ITZ + (1-3) $\beta$ -Glucan	None	Clinical cure
2015	Farias et al. [14]	Brazil	Case report	1	ITZ/ITZ + KI	None	Clinical cure

GSF, griseofulvin; IK, potassium iodide; NaI, sodium iodide; KTZ, ketoconazole; ITZ, itraconazole

results may not necessarily agree with its clinical effectiveness, and evasion from host immunity seems to be the clue for fungal resistance in vivo [59]. This should be especially addressed when it comes to *S. brasiliensis*, the main species identified in the Rio de Janeiro epidemic and described as being highly virulent. In fact, virulent factors such as melanin production may compromise terbinafine's interaction

with the fungal wall, leading to an impairment in its antifungal ability [60]. Having said that, we strongly suggest that some light be shed on these key factors, and that they should be carefully interpreted while evaluating new regimens of treatment for sporotrichosis.

Although terbinafine safety and effectiveness in vivo still need to be further investigated and studies

on a larger number of animals are required, the current reports indicate that it can emerge as a therapeutic option for canine sporotrichosis. Moreover, considering the complete remission of the respiratory signs, we believe that the use of terbinafine in cats is also promising and should be kept in mind for clinical studies in the future.

**Acknowledgements** The authors are thankful to Tânia Maria Pacheco Schubach for revising the manuscript and for processing figures; to James Czarnecki for the careful English review of the article; and to the staff of Diagnostic Section of the Mycology Laboratory of INI/Fiocruz. This study was supported by Fundação Carlos Chagas de Amparo à Pesquisa do Estado do Rio de Janeiro (FAPERJ—Programa Jovem Cientista do Nosso Estado/E-26/203.303/2016). SAP holds a research productivity fellowship granted by Conselho Nacional de Pesquisa e Desenvolvimento Tecnológico (CNPq). PGV holds a PhD scholarship granted by CNPq.

#### Compliance with Ethical Standards

**Conflict of interest** The authors declared no potential conflict of interest with respect to the research, authorship, and/or publication of this article.

**Ethical Approval** All procedures performed in studies involving animals were in accordance with the ethical standards of the institution or practice at which the studies were conducted.

**Informed Consent** The owners gave verbal informed consent for using the following data obtained from their dog and were informed that these data would remain anonymous.

#### References

- Rodrigues AM, de Melo Teixeira M, de Hoog GS, Schubach TM, Pereira SA, Fernandes GF, et al. Phylogenetic analysis reveals a high prevalence of *Sporothrix brasiliensis* in feline sporotrichosis outbreaks. *PLoS Negl Trop Dis*. 2013;7(6): e2281. <https://doi.org/10.1371/journal.pntd.0002281>.
- Silva MBT, Costa MMM, Torres CCS, Gutierrez-Galhardo MC, Valle ACF, de Magalhães MAFM, et al. Urban sporotrichosis: a neglected epidemic in Rio de Janeiro, Brazil. *Cad Saude Publica*. 2012;28(10):1867–80.
- Gremião IDF, Miranda LHM, Reis EG, Rodrigues AM, Pereira AS. Zoonotic epidemic of sporotrichosis: cat to human transmission. *PLoS Pathog*. 2017. <https://doi.org/10.1371/journal.ppat.1006077>.
- Oliveira MM, Almeida-Paes R, Muniz MM, Gutierrez-Galhardo MC, Zancoppe-Oliveira RM. Phenotypic and molecular identification of *Sporothrix* isolates from an epidemic area of sporotrichosis in Brazil. *Mycopathologia*. 2011;172(4):257–67. <https://doi.org/10.1007/s11046-011-9437-3>.
- Meyer KKF. The relation of animal to human sporotrichosis studies on American sporotrichosis. *JAMA*. 1915;LXV(7): 579–85.
- Schubach TM, Schubach A, Okamoto T, Barros MB, Figueiredo FB, Cuzzi T, et al. Canine sporotrichosis in Rio de Janeiro, Brazil: clinical presentation, laboratory diagnosis and therapeutic response in 44 cases (1998–2003). *Med Mycol*. 2006;44(1):87–92.
- Cafarchia C, Sasaneli M, Lia RP, Caprariis D, Guillot J, Otranto D. Lymphocutaneous and nasal sporotrichosis in a dog from southern Italy: case report. *Mycopathologia*. 2007;163:75–9.
- Whittemore JC, Webb CB. Successful treatment of nasal sporotrichosis in dog. *Can Vet J*. 2007;48(4):411–4.
- Crothers SL, White SD, Ihrke PJ, Affolter VK. Sporotrichosis: a retrospective evaluation of 23 cases seen in northern California (1987–2007). *Vet Dermatol*. 2009; 20(4):249–59.
- Rosser E, Dunstan R. Sporotrichosis. In: Greene CE, editor. *Infectious diseases of the dog and cat*. 3rd ed. Philadelphia: Saunders Elsevier; 2006. p. 608–12.
- Schubach TM, Menezes RC, Wanke B. Sporotrichosis. In: Greene EC, editor. *Infectious diseases of the dog and cats*. 4th ed. Missouri: Elsevier; 2012. p. 645–50.
- Pereira SA, Gremião IDF, Menezes RC. Sporotrichosis in animals: zoonotic transmission. In: Carlos IZ, editor. *Sporotrichosis new developments and future prospects*. Berlin: Springer; 2015. p. 83–102.
- Sykes JE, Torres SM, Armstrong PJ, Lindeman CJ. Itraconazole for treatment of sporotrichosis in a dog residing on a Christmas tree farm. *J Am Vet. Med Assoc*. 2001;218(9): 1440–3, 1421.
- Farias MR, Assunção DL, Duarte G, Vandresen G, Werner J, Tarqeti U. Canine bone sporotrichosis: a case report. *Sem Cienc Agrar*. 2015;36(3):1445–50.
- Ryder NS. Terbinafine: mode of action and properties of the squalene epoxidase inhibition. *Br J Dermatol*. 1992; 126(Suppl 39):2–7.
- Gupta AK, Lynde CW, Lauzin GJ, et al. Cutaneous adverse effects associated with terbinafine therapy: 10 cases reports and a review of the literature. *Br J Dermatol*. 1998;138: 529–32.
- Esterre P, Inzan CK, Ramarcel ER, Andriantsimahavandy A, Ratsioharana M, Pecarrere JL, et al. Treatment of chromomycosis with terbinafine: preliminary results of an open pilot study. *Br J Dermatol*. 1996;134(Suppl 46):33–6.
- Silva-Rocha WP, Cardoso FJ, Colalto W, Melo AS, Chaves GM. Clinical improvement of chromoblastomycosis refractory to itraconazole successfully treated with high dose of terbinafine. *J Dermatol*. 2013;40(9):775–6.
- Moriello KA. Treatment of dermatophytosis in dogs and cats: review of published studies. *Vet Dermatol*. 2004; 15:99–107.
- Rosales MS, Marsella R, Kunkle G, et al. Comparison of the clinical efficacy of oral terbinafine and ketoconazole combined with cephalixin in the treatment of *Malassezia* dermatitis in dogs—a pilot study. *Vet Dermatol*. 2005;16: 171–6.
- Francesconi G, Valle AC, Passos S, Reis R, Galhardo MC. Terbinafine (250 mg/day): effective and safe treatment of

- cutaneous sporotrichosis. *J Eur Acad Dermatol Venereol.* 2009;23(11):1273–6.
22. Francesconi G, Francesconi do Valle AC, Passos SL, Lima Barros MB, Almeida-Paes R, Curi AL, et al. Comparative study of 250 mg/day terbinafine and 100 mg/day itraconazole for the treatment of cutaneous sporotrichosis. *Mycopathologia.* 2011;171(5):349–54.
  23. Meinerz AR, Nascente OS, Schuch LFD, Cleff MB, Santin R, Brun CS, et al. In vitro susceptibility of isolates of *Sporothrix schenckii* to terbinafine and itraconazole. *Rev Soc Bras Trop.* 2007;40(1):60–2.
  24. Gutierrez-Galhardo MC, Oliveira RMZ, Valle ACF, Almeida Paes R, Silvatavares PM, Monzon A, et al. Molecular epidemiology and antifungal susceptibility patterns of *Sporothrix schenckii* isolates from a cat-transmitted epidemic of sporotrichosis in Rio de Janeiro, Brazil. *Med Mycol.* 2008;46:141–51.
  25. Borba-Santos LP, Rodrigues AM, Gagini TB, Fernandes GF, Castro R, Camargo ZP, et al. Susceptibilidade of *Sporothrix brasiliensis* isolates to amphotericin B, azoles and terbinafine. *Med Mycol.* 2015;53(2):178–88.
  26. Oliveira de Oliveira MM, Sampaio P, Almeida-Paes R, Pais C, Gutierrez-Galhardo MC, Zancope-Oliveira RM. Rapid identification of *Sporothrix* species by T3B fingerprinting. *J Clin Microbiol.* 2012;50(6):2159–62. <https://doi.org/10.1128/JCM.00450-12>.
  27. Oliveira MM, Franco-Duarte R, Romeo O, Pais C, Criseo G, Sampaio P, Zancope-Oliveira RM. Evaluation of T3B fingerprinting for identification of clinical and environmental *Sporothrix* species. *FEMS Microbiol Lett.* 2015;362(6):pii: fmv027. <https://doi.org/10.1093/femsle/fmv027>.
  28. Clinical and Laboratory Standards Institute (CLSI). 2008. Reference method for broth dilution antifungal susceptibility testing of filamentous fungi, 2nd ed Approved standard M38-A2. Clinical and Laboratory Standards Institute, Wayne, PA.
  29. Migliano MF, de Freitas DC, Moreno G. Sporotrichosis in dogs. *Rev Fac Med Vet S Paulo.* 1963;7(1):225–35.
  30. Londero AT, Castro RM, Fischman O. Two cases of sporotrichosis in dogs in Brazil. *Sabouraudia.* 1964;3(4):273–4.
  31. Freitas D, Moreno G, Saliba A, Bottino J, Mós E. Sporotrichosis in dogs and cats. *Rev Fac Med Vet S Paulo.* 1965;7(2):381–7.
  32. Berry JM, Kelley DC, Strafuss AC. Sporotrichosis in a dog: a case report. *Vet Med Sm Anim Clin.* 1971;66:226–9.
  33. Koehne G, Powell HS, Hail RI. Sporotrichosis in a dog. *J Am Vet Med Assoc.* 1971;159(7):892–4.
  34. Scott DW, Bentinck-Smith J, Haggerty GF. Sporotrichosis in three dogs. *Cornell Vet.* 1974;64(416/42):6.
  35. Dion WM, Speckmann G. Canine otitis externa caused by the fungus *Sporothrix schenckii*. *Can Vet J.* 1978;19:40–1.
  36. Woodard DC. Splenic sporotrichosis in a dog. *Vet Med Small Anim Clin.* 1980;75:1011–2.
  37. Goad DL, Goad ME. Osteoarticular sporotrichosis in a dog. *J Am Vet Med Assoc.* 1986;189:1326–8.
  38. Iwasaki M, Hagiwara MK. Skeletal sporotrichosis. *Companion Anim Pract.* 1988;2:27–31.
  39. Moriello KA, Franks P, Lewis DD, King R. Cutaneous-lymphatic and nasal sporotrichosis in a dog. *J Am Anim Hosp Assoc.* 1988;24:621–6.
  40. Sanford SE. Persistent sporotrichosis in a dog. *Can Vet J.* 1992;33:826.
  41. Bernstein JA, Cook HE, Gill AF, Ryan KA, Siminger J. Cytologic diagnosis of generalized cutaneous sporotrichosis in a hunting hound. *Vet Clin Pathol.* 2007;36(1):94–6.
  42. Madrid IM, Xavier MO, Mattei AS, Carapeto LP, Antunes TA, Júnior RS, Nobre MO, Meireles MCA. Canine sporotrichosis: report of three cases. *Braz J Vet Res Anim Sci.* 2007;44(6):441–3.
  43. Filgueira KD. Sporotrichosis in the canine species: a case report on city of Mossoro, RN. *Cienc Anim Bras.* 2009;10(2):673–7.
  44. Grassani MH, Juppa ALC, da Silva DA, Figueiredo FB. Use of potassium iodide in the treatment of sporotrichosis in dog after failure treatment with ketoconazole and itraconazole—a case report. *Clin Vet.* 2012;101:116–20.
  45. Rossi CN, Odagui J, Larsson CE. Retrospective assessment of the treatment of sporotrichosis in cats and dogs using itraconazole. *Acta Sci Vet.* 2013;41:1112.
  46. Guterres KA, Matos CB, Osório LG, Schuch ID, Cleff MB. The use of (1-3)  $\beta$ -glucan along with itraconazole against canine refractory sporotrichosis. *Mycopathologia.* 2014;177(3–4):217–21.
  47. Kohler LM, Monteiro PC, Hahn RC, Hamdan JS. In vitro susceptibilities of isolates of *Sporothrix schenckii* to itraconazole and terbinafine. *J Clin Microbiol.* 2004;42(9): 4319–20.
  48. Rodrigues AM, de Hoog GS, de Cássia Pires D, Brihante RS, Sidrim JJ, Gadelha MF, Colombo AL, de Camargo ZP. Genetic diversity and antifungal susceptibility profiles in causative agents of sporotrichosis. *BMC Infect Dis.* 2014;14:219. <https://doi.org/10.1186/1471-2334-14-219>.
  49. Almeida-Paes R, Brito-Santos F, Figueiredo-Carvalho MHG, Machado ACS, Oliveira MME, Pereira SA, Gutierrez-Galhardo MC, Zancope-Oliveira RM. Minimal inhibitory concentration distributions and epidemiological cutoff values of five antifungal agents against *Sporothrix brasiliensis*. *Mem Inst Oswaldo Cruz.* 2017;112(5):376–81. <https://doi.org/10.1590/0074-02760160527>.
  50. Sanhotene KO, Brandolt TM, Klafke GB, Poester VR, Xavier MO. In vitro susceptibility of *Sporothrix brasiliensis*: comparison of yeast and mycelial phases. *Med Mycol.* 2017;55(8):869–76. <https://doi.org/10.1093/mmy/myw143>.
  51. Hull PR, Vismer HF. Treatment of cutaneous sporotrichosis with terbinafine. *Br J Dermatol.* 1992;126(39):51–5.
  52. Kauffman CA, Bustamante B, Chapman SW, Pappas PG. Clinical practice guidelines for the management of sporotrichosis: 2007 update by the infectious diseases society of America. *Clin. Infect. Dis.* 2007; 15; 45(10): 1255–65.
  53. Song Y, Zhong SX, Yao L, Cai Q, Zhou JF, Liu YY, et al. Efficacy and of itraconazole pulses vs. continuous regimen in cutaneous sporotrichosis. *J Eur Acad Dermatol Venereol.* 2011;25(3):302–5.
  54. Heidrich D, Senter L, Valente P, Stopiglia CDO, Vettoratto G, Scroferneker ML. Successful treatment of terbinafine in a case of sporotrichosis. *An Bras Dermatol.* 2011;86(4 suppl 1):S182–5.
  55. Gremião IDF, Menezes RC, Schubach TM, Figueiredo AB, Cavalcanti MC, Pereira SA. Feline sporotrichosis:

- epidemiological and clinical aspects. *Med Mycol.* 2015;53:15–21.
56. Pereira SA, Passos SR, Silva JN, Gremiao ID, Figueiredo FB, Teixeira JL, et al. Response to azolic antifungal agents for treating feline sporotrichosis. *Vet Rec.* 2010;166(10):290–4.
57. Balda AC, Otsuka M, Larsson CE. A clinical trial using griseofulvin and terbinafine in the treatment of canine and feline dermatophytosis. *Cienc Rural.* 2007;37(3):750–4.
58. Berger DJ, Lewis TP, Schick AE, Stone RT. Comparison of once-daily versus twice-weekly terbinafine administration for the treatment of canine *Malassezia dermatitis*—a pilot study. *Vet Dermatol.* 2012;23(5):418–e79. <https://doi.org/10.1111/j.1365-3164.2012.01074.x>.
59. Freitas DF, Santos SS, Almeida-Paes R, de Oliveira MM, do Valle AC, Gutierrez-Galhardo MC, et al. Increase in virulence of *Sporothrix brasiliensis* over 5 years in a patient with chronic disseminated sporotrichosis. *Virulence.* 2015;6(2):112–20. <https://doi.org/10.1080/21505594.2015.1014274>.
60. Almeida-Paes R, Figueiredo-Carvalho MHG, Brito-Santos F, Almeida-Silva F, Oliveira MME, Zancampé-Oliveira RM. Melanins protect *Sporothrix brasiliensis* and *Sporothrix schenckii* from the antifungal effects of terbinafine. *PLoS ONE.* 2016;11(3):e0152796. <https://doi.org/10.1371/journal.pone.0152796>.