

Giant squamous cell carcinoma in HIV-positive patient

Authors *

Cassio Porto Ferreira¹
Heliomar de Azevedo
Valle²

José Alvimar Ferreira³
Ricardo Barbosa Lima⁴
Carlos José Martins⁵

¹Master – Dermatologist
of IPEC/FIOCRUZ

²PhD/Professor –
Discipline of Pathological
Anatomy, Universidade
Federal do Estado do
Rio de Janeiro (UNIRIO)

³Specialist/Professor –
Discipline of Dermatology,
Universidade Federal do
Estado do Rio de Janeiro
(UNIRIO)

⁴Specialist/Professor -
Discipline of Dermatology,
Universidade Federal do
Estado do Rio de Janeiro
(UNIRIO)

⁵Specialist /
Professor - Discipline
of Dermatology,
Universidade Federal do
Estado do Rio de Janeiro
(UNIRIO)

*Department of
Dermatology, Hospital
Universitário Gaffrée
e Guinle/Universidade
Federal do Estado do Rio
de Janeiro (UNIRIO).

Submitted on: 04/27/2009
Approved on: 09/25/2009

Correspondence to:
Cassio Porto Ferreira
Travessa Regina, 79/85 –
Centro, Nova Iguaçu – RJ
– Brasil. CEP: 26210-350
Phone: 55 21 27679722
Fax: 55 21 27688008
E-mail: drcassioferreira@
yahoo.com.br

We declare no conflict of
interest.

CLINICAL INFECTIOUS DISEASES IMAGES

Sixty year-old male, white, and HIV seropositive in use of zidovudine, lamivudine and efavirenz, presenting tumor located in scalp, progressing with rapid growth during one year. Upon dermatological examination, it was evidenced extensive tumor of infiltrated and exophytic appearance, covered by necrotic material, and located bilaterally in the parietal region (Figures 1, 2). The histopathological examination revealed a diagnosis of well differentiated squamous cell carcinoma (SCC), (Figures 3, 4). Additional tests were performed, such as CD4: 62 cells/mm³; CD8: 1,654 cells/mm³; viral load: 91,000 copies. CT brain scan revealed cerebral foci of calcification in the suprasellar region

[Braz J Infect Dis 2010;14(2):209-210]©Elsevier Editora Ltda.

Este é um artigo Open Access sob a licença de [CC BY-NC-ND](https://creativecommons.org/licenses/by-nc-nd/4.0/)

Figure 1: Front view of the lesion, with its appearance and vegetative tumor.

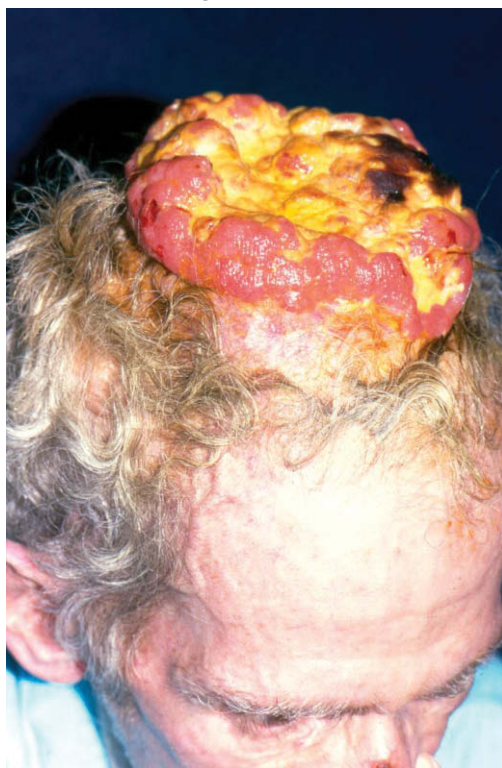

Figure 2: More detail, showing the real extent of the tumor with necrotic and infiltrating appearance.

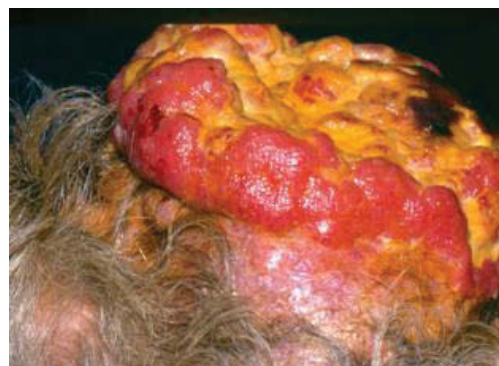

Figure 3: Neoplastic proliferation composed of squamous cell masses (HE, 10X).

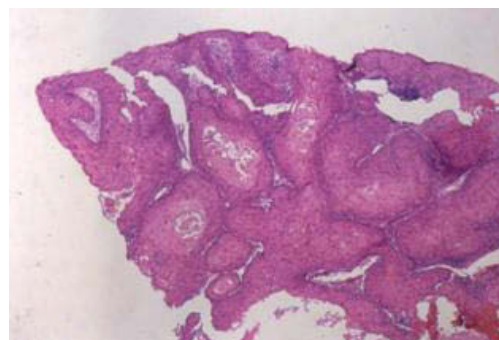
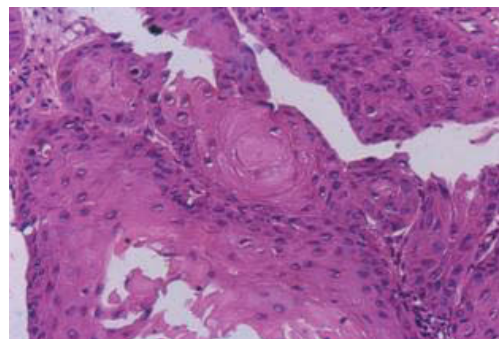
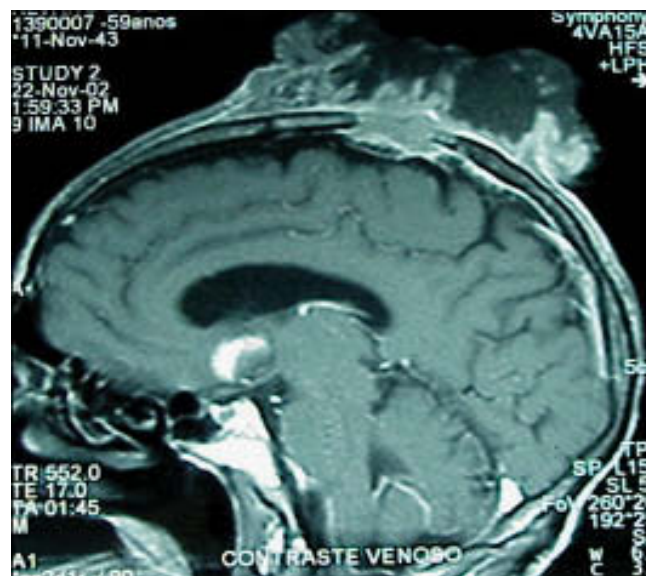


Figure 4: Formation of structures that replicate the look of pearl cornea (HE, 100X).



and basal ganglia on the left, with about 1.50 cm in diameter and invasion to the skull along the interparietal suture (Figure 5). The patient evolved with pneumonia and subsequent death, it was not possible to investigate visceral metastases. The skin is the most frequently organ affected in HIV seropositive patients, and the prevalence of skin problems during the course of infection may reach 92%.¹ SCC is a malignant skin cancer with an invasive nature, consisting of atypical proliferation of spinous cells that may cause metastases to regional lymph nodes and internal organs, accounting for about 25% of skin cancers.² Immunosuppressed patients have a greater potential for tumor growth, cell differentiation, and aggressiveness that can occur in all HIV infection stages.³ The local recurrence, metastasis, and survival are not related to the number of opportunistic infections or CD4 count and should be treated aggressively, after assessing the degree of immunosuppression and prognosis of HIV infection. Mohs micrographic surgery is the treatment of choice.⁴

Figure 5: Brain Computerized tomography: tumor invasion through the skull.



REFERENCES

1. Porro AM. Manifestações dermatológicas da infecção pelo HIV. *An Bras Dermatol* 2000; 75(6):665-91.
2. Marks R. Squamous cell carcinoma. *Lancet* 1996; 347:735-8.
3. Maurer TA. Cutaneous Squamous Cell Carcinoma in Human Immunodeficiency Virus-Infected Patients. *Arch Dermatol* 1997; 133:577-83.
4. Nguyen P. Aggressive Squamous Cell Carcinomas in Persons Infected with the Human Immunodeficiency Virus. *Arch Dermatol* 2002; 138:758-63.