

## CASE REPORT

### CMV AND HSV-2 MYELORADICULITIS IN AN HIV INFECTED PATIENT

Adriana PINTO, Edwiges SANTOS, Danusa F. CORREA, Rodrigo ESCADA, Carla de Mello VORSATZ,  
Sandra Wagner CARDOSO & Marco A. LIMA

---

#### SUMMARY

While CMV myeloradiculitis is a known complication in AIDS patients with severe immunosuppression, HSV-2 necrotizing myeloradiculitis is rare and often associated with disabling a fatal outcome. We hereby describe a 46 year-old HIV infected patient with profound and sustained immunosuppression who presented with an acute ascending paraparesis and urinary retention. Lumbar spine MRI showed contrast enhancement at the conus medullaris and cauda equine, and both CMV and HSV-2 CSF PCR were positive. Despite treatment, the patient died 20 days later. We review the main diagnostic and therapeutic aspects of herpes virus associated myeloradiculitis and discuss the approach in similar cases.

**KEYWORDS:** Cytomegalovirus; Herpes simplex 2; HIV; Myelitis; Foscarnet; Ganciclovir.

---

#### INTRODUCTION

Currently, there are more than 33 million people living with HIV around the world. The introduction of highly active antiretroviral therapy (HAART) brought an improvement in the survival rate and a decrease in the incidence of opportunistic infections. Concerning the opportunistic infections of the central nervous system (CNS), recent studies have shown a decrease in the incidence of progressive multifocal leukoencephalopathy (PML), CMV encephalitis and myelitis as well as other herpesviruses-associated diseases<sup>19</sup>.

Nevertheless, there is a proportion of HIV infected patients under treatment that become resistant to any HAART regimen during the course of the disease<sup>13</sup>. In such individuals, the CD4+ T cell count is persistently low and opportunistic infections are common in this scenario. In particular, disseminated cytomegalovirus (CMV) infection, disseminated *Mycobacterium avium* complex (MAC) and Epstein Barr virus associated primary central nervous system lymphoma frequently occur when CD4+ T cell count is under 50 mm<sup>3</sup> (5). Furthermore, concomitant infections may occur in patients with advanced immunosuppression, increasing morbidity and mortality.

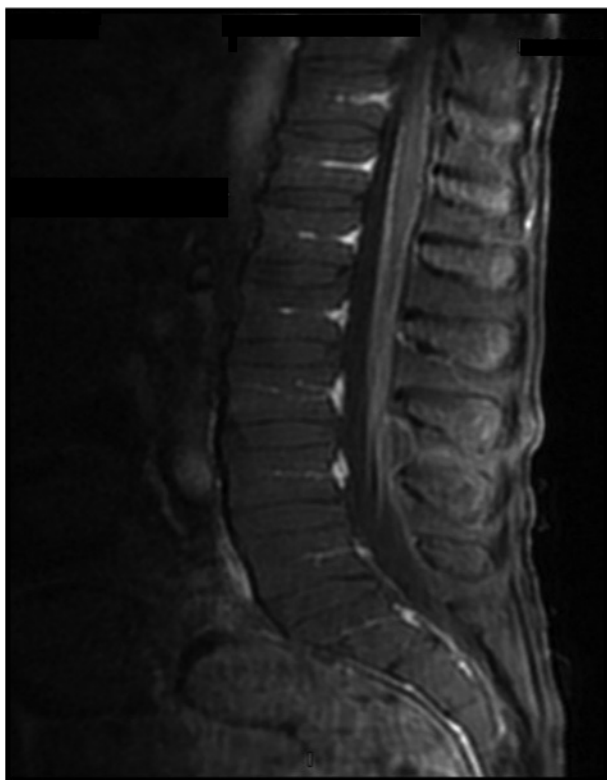
In this study, we sought to describe a long-term AIDS patient with HAART failure, who developed a myeloradiculitis due to concurrent HSV-2 and CMV infections, and review the diagnostic and therapeutic approaches in similar cases.

#### CASE REPORT

A 46 year-old male HIV infected patient presented with a five-day history of progressive bilateral, asymmetric ascendant weakness in the lower limbs, associated with hypoesthesia, imbalance and urinary retention. His physical examination showed an asymmetric flaccid paraparesis, abolished deep tendon reflexes in the lower extremities and diminished in the upper extremities. There was sensory loss in the feet, but the patient had already had a previous diagnosis of HIV-related sensory neuropathy.

His previous history revealed a diagnosis of HIV infection in 1993. His most recent HIV viral load was 23,100 copies/mL and the CD4+ T lymphocyte count was 2 cells/mm<sup>3</sup>. His T CD4+ cell count had been under 20 cells/mm<sup>3</sup> in the previous three years despite several antiretroviral regimens. At the time he was taking lamivudine, raltegravir, ritonavir, etravirine and darunavir. Ten months before admission, a diagnosis of CMV retinitis was made. He received initially 21 days of IV ganciclovir 5 mg/kg every 12h as induction treatment. However, he could tolerate IV maintenance treatment due to bone marrow suppression despite of the daily filgrastim use, and was switched to intravitreal ganciclovir 2.5 mg weekly one month before admission. There was no clinical evidence of systemic CMV infection, but no blood CMV PCR or CMV pp65 antigenemia were performed. Two weeks before the development of neurological symptoms, he presented with a pruriginous and painful anal lesion that was diagnosed as secondary to HSV infection.

A lumbar spine magnetic resonance (MR) demonstrated contrast enhancement at the conus medullaris and cauda equina (Fig. 1). The cerebrospinal fluid (CSF) analysis disclosed 22 cells/mm<sup>3</sup> with mononuclear predominance, glucose: 42 mg/dL, protein: 225 mg/dL. Stains and cultures for bacteria, mycobacteria and fungi were negative. Pending results of herpes viruses CSF PCR, he was started on intravenous ganciclovir. Both CSF HSV-2 and CMV PCR were positive, but, again, the therapy had to be suspended after 16 days because of severe bone marrow suppression. The patient developed septic shock associated with multidrug-resistant *Pseudomonas aeruginosa* infection and died 20 days after hospitalization.



**Fig. 1** - Lumbar spine T1-weighted MRI sequence showing contrast enhancement of the conus medullaris and cauda equina.

## DISCUSSION

Ascending myelitis syndrome is associated with infection by different agents such as CMV, HSV-1, HSV-2, Varicella zoster, *Treponema pallidum*, *Toxoplasma gondii* and *Schistosoma mansoni*<sup>4</sup>. In particular, Herpes viruses are neuropathic viruses, which can cause myelitis/polyradiculopathy, especially in immunosuppressed individuals. In AIDS patients, most cases are related to CMV infection, mainly at advanced stages, when T CD4+ cell count < 50 cell/mm<sup>3</sup> (12). CMV myelitis is often associated with CMV infection in other organs<sup>11</sup>. In our patient, CMV retinitis had been diagnosed previously, but we were not able to show systemic CMV infection at the onset of neurological disease, nor determine CMV viral load since blood CMV PCR was not available at our institution. The clinical picture is of a painful rapidly ascending paraparesis with urinary retention. CSF analysis usually

shows a neutrophilic pleocytosis with hypoglycorrhachia and elevated protein levels, although a normal cell count can be observed, which can make diagnosis difficult. CMV CSF PCR is highly sensitive and specific for diagnosis and higher viral loads are observed in patients with CMV myelitis than in encephalitis<sup>21</sup>. Combination treatment with ganciclovir and foscarnet is recommended as the optimal approach, but evidence is scarce. ANDUZE-FARIS *et al.* evaluated 31 individuals with CMV encephalitis or myelitis and observed improvement or stabilization in 74% of the patients treated with this regimen<sup>1</sup>. Failure to respond to ganciclovir monotherapy is common. Possible factors are the poor penetration of the drug into the CNS, development of resistant ganciclovir strains or irreversible neurological damage<sup>1,20</sup>. Genotypical and phenotypical susceptibility testing should be performed when clinical improvement is not observed, but these tests are not available in most centers in developing countries.

HSV-2 is an important cause of encephalitis in neonates. Additionally, after primary infection, it establishes latent infection in sacral ganglia and may be responsible for a recurrent lymphocytic meningitis (Mollaret's meningitis) at the time of recurrences<sup>22</sup>. In immunocompromised individuals, HSV-2 can rarely cause encephalitis or myelitis<sup>3</sup>. Any combination of flaccid paraparesis, loss of sensation, urinary retention, constipation and erectile dysfunction can be observed<sup>9</sup>. As observed in our patient, a previous or concurrent HSV-2 rash in the anogenital area can be seen in some patients. CSF HSV-2 PCR has replaced biopsy as gold standard with a sensitivity and specificity higher than 95%. However, PCR results should be interpreted in relation of time of CSF collection. Negative results can be observed in the first 72 hours, or in patients already being treated with acyclovir. In such cases, a retrospective diagnosis of CNS HSV-2 infection can be carried out in 80% of patients by a fourfold increase in the titers of HSV antibodies after one month<sup>6</sup>. Treatment with IV acyclovir for 10-14 days results in improvement in most patients, but severe myelitic deficits may persist despite therapy<sup>16</sup>. Additionally, there are reports of HIV infected patients with HSV-2 myeloradiculitis who had a favorable outcome after being treated with this drug<sup>2,7</sup>. However, we decided not to add it since ganciclovir is also efficacious against both viruses<sup>15</sup> and in order to avoid additional side effects. Foscarnet would be an interesting option since it is efficacious against both CMV and HSV-2 and has a good CSF penetration<sup>18</sup>. Nevertheless, this drug is not readily available in our country.

Neuropathological findings in herpes virus associated necrotizing myeloradiculitis include extensive necrotic and hemorrhagic changes associated with necrotizing vasculitis and perivascular lymphocytic infiltration involving both gray and white matter as well as spinal roots<sup>10,14</sup>.

Infection of the CNS by two or more viruses is a well-recognized event<sup>24</sup>, but myelitis due to concurrent HSV-2 and CMV infection is extremely rare and probably related to severe immune system impairment, as observed in our patient. In this case, there was evidence of HSV cutaneous reactivation concurrent to the development of the neurological picture. In addition, systemic ganciclovir maintenance treatment had been stopped one month before admission, which predisposed him to a systemic CMV reactivation. In a setting of persistent low CD4+ T count and impaired cellular response, both viruses were able to invade the spinal cord. Since either CMV or HSV-2 can infect multiple cell types (neurons, astrocytes, oligodendrocytes and microglia) in the CNS<sup>3,12</sup> we can speculate on a possible synergistic effect of this concurrent infection in producing spinal cord lesion. To corroborate this hypothesis, we were able to find only

three previous reports<sup>8,17,23</sup> in HIV patients. All these patients had profound immunosuppression, and the prognosis was grim in the two patients it was available (death in one and minimal recovery in the other).

In conclusion, neurological deficits in immunosuppressed individuals can be secondary to more than one infectious agent. A careful review of the medical history coupled to a rational use of imaging and CSF analysis can disclose multiple infections in the CNS, allowing the proper treatment and reduction of morbidity and mortality.

## RESUMO

### Mieloradiculite por CMV e HSV2 em paciente infectado pelo HIV

Enquanto a mieloradiculite pelo CMV é complicação conhecida em pacientes com SIDA e imunossupressão grave, a mieloradiculite necrosante por HSV-2 é rara e muitas vezes associada a sequelas ou desfecho fatal. Descrevemos um paciente de 46 anos de idade, infectado pelo HIV com imunossupressão profunda e sustentada que apresentou paraparesia aguda ascendente e retenção urinária. A RM de coluna lombar mostrou o realce de contraste no cone medular e cauda equina e ambos PCR para CMV e HSV-2 no LCR foram positivos. Apesar do tratamento, o paciente morreu 20 dias depois. Revisamos os principais aspectos diagnósticos e terapêuticos da mieloradiculite associada aos herpesvírus e discutimos a abordagem em casos semelhantes.

## REFERENCES

1. Anduze-Faris BM, Fillet AM, Gozlan J, Lancar R, Boukli N, Gasnault J. *et al.* Induction and maintenance therapy of cytomegalovirus central nervous system infection in HIV-infected patients. *AIDS*. 2000;14:517-24.
2. Aurelius E, Forsgren M, Gille E, Skoldenberg B. Neurologic morbidity after herpes simplex virus type 2 meningitis: a retrospective study of 40 patients. *Scand J Infect Dis*. 2002;34:278-83.
3. Baringer JR. Herpes simplex infections of the nervous system. *Neurol Clin*. 2008;26:657-74, viii.
4. Berger JR, Sabet A. Infectious myelopathies. *Semin Neurol*. 2002;22:133-42.
5. Boissé L, Gill MJ, Power C. HIV infection of the central nervous system: clinical features and neuropathogenesis. *Neurol Clin*. 2008;26:799-819, x.
6. Boivin G. Diagnosis of herpesvirus infections of the central nervous system. *Herpes*. 2004;11(Suppl 2):48A-56A.
7. Corral I, Quereda C, Navas E, Perez-Elias MJ, Jover F, Moreno S. Sacral myeloradiculitis complicating genital herpes in a HIV-infected patient. *Int J STD AIDS*. 2005;16:175-7.
8. Corti M, Soto I, Villafañe MF, Bouzaz B, Duarte JM, Yampolsky C. *et al.* Mielitis aguda necrotizante en un paciente con SIDA. *Medicina (B Aires)*. 2003;63:143-6.
9. Eberhardt O, Küker W, Dichgans J, Weller M. HSV-2 sacral radiculitis (Elsberg syndrome). *Neurology*. 2004;63:758-9.
10. Folpe A, Lapham LW, Smith HC. Herpes simplex myelitis as a cause of acute necrotizing myelitis syndrome. *Neurology*. 1994;44:1955-7.
11. Fuller GN. Cytomegalovirus and the peripheral nervous system in AIDS. *J Acquir Immune Defic Syndr*. 1992;5(Suppl 1):S33-6.
12. Griffiths P. Cytomegalovirus infection of the central nervous system. *Herpes*. 2004;11(Suppl 2):95A-104A.
13. Hull MW, Lima VD, Hogg RS, Harrigan PR, Montaner JS. Epidemiology of treatment failure: a focus on recent trends. *Curr Opin HIV AIDS*. 2009;4:467-73.
14. Iwamasa T, Utsumi Y, Sakuda H, Yoshitake H, Kakazu T, Kubota R. *et al.* Two cases of necrotizing myelopathy associated with malignancy caused by herpes simplex virus type 2. *Acta Neuropathol*. 1989;78:252-7.
15. Matthews T, Boehme R. Antiviral activity and mechanism of action of ganciclovir. *Rev Infect Dis*. 1988;10(Suppl 3):S490-4.
16. Nakajima H, Furutama D, Kimura F, Shinoda K, Ohsawa N, Nakagawa T. *et al.* Herpes simplex virus myelitis: clinical manifestations and diagnosis by the polymerase chain reaction method. *Eur Neurol*. 1998;39:163-7.
17. Quereda C, Corral I, Laguna F, Valencia ME, Tenorio A, Echeverria JE. *et al.* Diagnostic utility of a multiplex herpesvirus PCR assay performed with cerebrospinal fluid from human immunodeficiency virus-infected patients with neurological disorders. *J Clin Microbiol*. 2000;38:3061-7.
18. Raffi F, Taburet AM, Ghaleh B, Huart A, Singlas E. Penetration of foscarnet into cerebrospinal fluid of AIDS patients. *Antimicrob Agents Chemother*. 1993;37:1777-80.
19. Sacktor N. The epidemiology of human immunodeficiency virus-associated neurological disease in the era of highly active antiretroviral therapy. *J Neurovirol*. 2002;8(Suppl 2):115-21.
20. Schreiber A, Härter G, Schubert A, Bunjes D, Mertens T, Michel D. Antiviral treatment of cytomegalovirus infection and resistant strains. *Expert Opin Pharmacother*. 2009;10:191-209.
21. Shinkai M, Spector SA. Quantitation of human cytomegalovirus (HCMV) DNA in cerebrospinal fluid by competitive PCR in AIDS patients with different HCMV central nervous system diseases. *Scand J Infect Dis*. 1995;27:559-61.
22. Steiner I, Kennedy PG, Pachner AR. The neurotropic herpes viruses: herpes simplex and varicella-zoster. *Lancet Neurol*. 2007;6:1015-28.
23. Tucker T, Dix RD, Katzen C, Davis RL, Schmidley JW. Cytomegalovirus and herpes simplex virus ascending myelitis in a patient with acquired immune deficiency syndrome. *Ann Neurol*. 1985;18:74-9.
24. Vago L, Nebuloni M, Sala E, Cinque P, Bonetto S, Isella A. *et al.* Coinfection of the central nervous system by cytomegalovirus and herpes simplex virus type 1 or 2 in AIDS patients: autopsy study on 82 cases by immunohistochemistry and polymerase chain reaction. *Acta Neuropathol*. 1996;92:404-8.

Received: 15 December 2010

Accepted: 28 April 2011.

# Revista do Instituto de Medicina Tropical de São Paulo *on line.*

Publications from 1990 to the present data are now available on:

<http://www.scielo.br/rimtsp>  
**PAST ISSUES 1959-1989 (PDF)**  
[www.imt.usp.br/portal/](http://www.imt.usp.br/portal/)

The screenshot shows the website interface for the journal. At the top, there is a navigation bar with 'Arquivo', 'Editar', 'Exibir', 'Favoritos', 'Ferramentas', and 'Ajuda'. Below this is a search bar with 'Live Search' and a search icon. The main content area features the journal's logo, a navigation menu with 'issues' and 'articles search' sections, and a central graphic with the journal title 'REVISTA DO INSTITUTO DE MEDICINA TROPICAL DE SÃO PAULO'. To the left, there are links for 'português' and 'español', and a list of links including 'about the journal', 'editorial board', 'instructions to authors', 'subscription', and 'statistics'. Below these links is a table of SCImago indicators for the years 2000-2007. The table shows three indicators: SJR (0.1), Cites per doc (0.8), and Total cites (205). At the bottom, there is contact information for the Instituto de Medicina Tropical, including the address, phone number, and email address.

Indicator	2000-2007	Value
SJR		0.1
Cites per doc		0.8
Total cites		205

**SciELO** – The Scientific Electronic Library OnLine - SciELO is an electronic virtual covering a selected collection of Brazilian scientific journals.

The library is an integral part of a project being developed by FAPESP – Fundação de Amparo à Pesquisa do Estado de São Paulo, in partnership with BIREME – the Latin American and Caribbean Center on Health Sciences Information.

SciELO interface provides access to its serials collection via an alphabetic list of titles or a subject index or a search by word of serial titles, publisher names, city of publication and subject.

The interface also provides access to the full text of articles via author index or subject index or a search form on article elements such as author names, words from title, subject and words from full text.

FAPESP/BIREME Project on Scientific Electronic Publications  
Latin American and Caribbean Center on Health Sciences Information  
Rua Botucatu 862 – 04023-901 São Paulo, SP – Brazil  
Tel. (011) 5576-9863  
[scielo@bireme.br](mailto:scielo@bireme.br)