

Segmental Absence of Intestinal Musculature – Presentation in a 10-Year-Old Boy with an Extensive Involved Segment

Daniel Abensur Athanazio,^{1,*} Mateus T. Amaral Rocha,² Angela
 P. Mattos,³ Tereza Cristina Medrado Ribeiro,³ Ney Cristian Boa Sorte,³ 5
 Luiz Antonio R. Freitas,¹ and Luciana R. Silva¹

¹Federal University of Bahia, Salvador, Brazil; ²Hospital Universitário Professor Edgard
 Santos, Salvador, Brazil; ³Faculty of Medicine, Federal University of Bahia, Salvador, Brazil

Segmental absence of the intestinal musculature is a rare cause of acute abdomen most likely associated with intestinal perforation and sepsis in neonates and adults. We present a case of a 10-year-old boy who developed acute abdomen and was treated with right hemicolectomy and partial resection of the ileum. The ileum showed a 20-cm-long stenotic segment showing prominent thinning of the intestinal wall. This case occurred in an older child, which appears to be rare when comparing the literature. The bowel defect was also the largest described to date, indicating the potential effect of an atonic segment leading to obstructive disease. 10 15

Keywords congenital abnormalities, peritonitis, ileum

INTRODUCTION

Segmental absence of the intestinal musculature (SAIM) is a rare clinicopathological entity characterized by thinning or complete absence of the muscularis propria with preservation of the mucosa[1]. Patients with SAIM usually present with progressive acute abdomen that is most likely associated with intestinal perforation and sepsis.[1, 2] Less commonly, patients may present with more prolonged clinical features such as intolerance to feeding and bilious vomiting[1]. 20

The typical pathology of SAIM is of an isolated affected segment (usually less than 5 cm long) surrounded by normal bowel or bowel loops with preserved layers showing features of perforation and acute peritonitis. The diagnosis is dependent on histopathologic demonstration of absent muscularis propria[1, 2]. 25

SAIM has been reported in isolated case reports and small series (approximately 20 cases to date), usually associated with prematurity; most cases share presentation within the first 99 days of life[1–4]. 30

CASE REPORT

A 10-year-old boy sought medical assistance due to pain in the upper quadrants and postprandial vomiting. An upper GI endoscopy-based biopsy revealed mild atrophy

Received 14 April 2014; Revised xx xxxx; accepted 11 November 2014.

Address correspondence to Daniel Abensur Athanazio, Federal University of Bahia, Salvador, Brazil. E-mail: dathanazio@gmail.com

AQ3

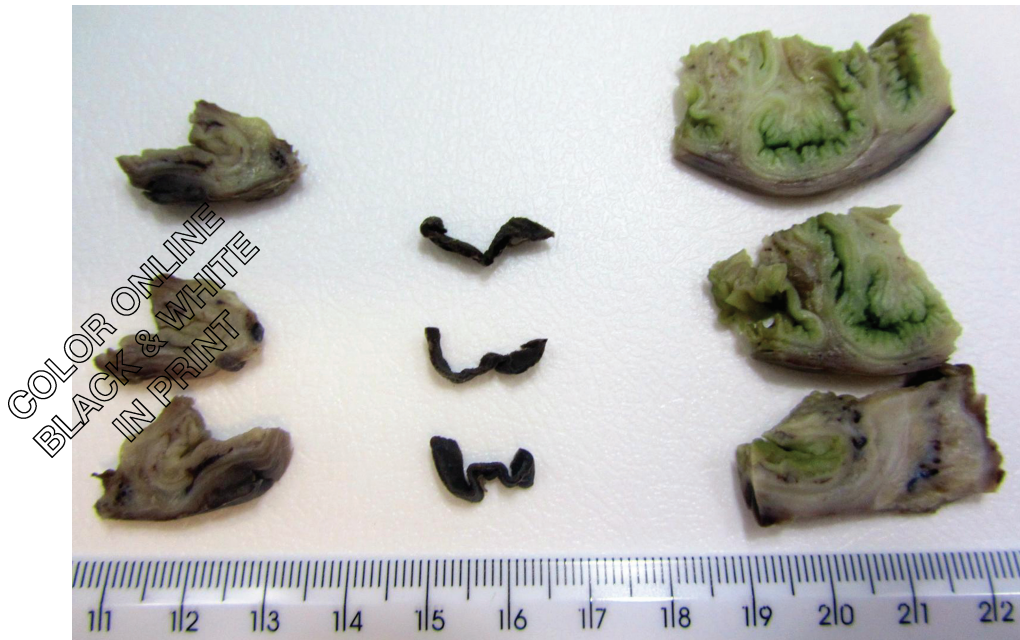

Figure 1. Gross appearance: the cut surface of the proximal 8-cm segment with no gross abnormalities (left); a 20-cm-long stenotic segment showing a reddish appearance on both serosal and mucosal surfaces and prominent thinning of the intestinal wall (center); and a distal 27-cm-long segment of ileal loops with preserved thickness of the intestinal wall but with prominent fibrous adhesences between them (right).

(villous to crypt ratio of 3:1 to 2:1) and chronic inflammation at the duodenal mu-
35 cosa. Detection of serum anti-gliadin IgA yielded weak reactivity. The patient was rec-
ommended to adhere to a gluten-free diet; however, this recommendation was never
strictly followed. The patient's symptoms worsened during the following 45 days and
were associated with the onset of fever. He developed signs of acute abdomen of prob-
40 able obstructive origin and was treated with a right hemicolectomy and partial resec-
tion of the ileum. Examination of the surgical specimen (by the original pathology
laboratory and on consultation of the specimen and slides) yielded the same find-
ings. The right colon measured 18 cm, and the appendix measured 9 cm. The ileum
measured 55 cm and could be grossly divided into three segments: an 8 cm proximal
45 segment with no gross abnormalities; a 20-cm-long stenotic segment showing a red-
dish appearance on both serosal and mucosal surfaces and prominent thinning of the
intestinal wall; and a distal 27-cm-long segment of ileal loops with preserved thick-
ness of the intestinal wall but with prominent fibrous adhesences between them (Fig-
ure 1). The external surface of the right colon, appendix and ileum showed deposits
of fibrinous/fibrous material suggestive of an organizing peritonitis. Microscopic ex-
50 amination of slides confirmed recent fibrosis and granulation tissue on the surface of
the colon, appendix, and ileum. All three also showed marked reactive lymphoid ag-
gregates. The most striking feature at histology was the absence of muscularis propria
along the whole 20 cm ileal segment with grossly stenotic appearance associated with
thinning of the intestinal wall (Figure 2). The submucosa showed remarkable conges-
55 sion. The surgical specimen also had five regional lymph nodes with reactive follicular
and sinusal hyperplasia.

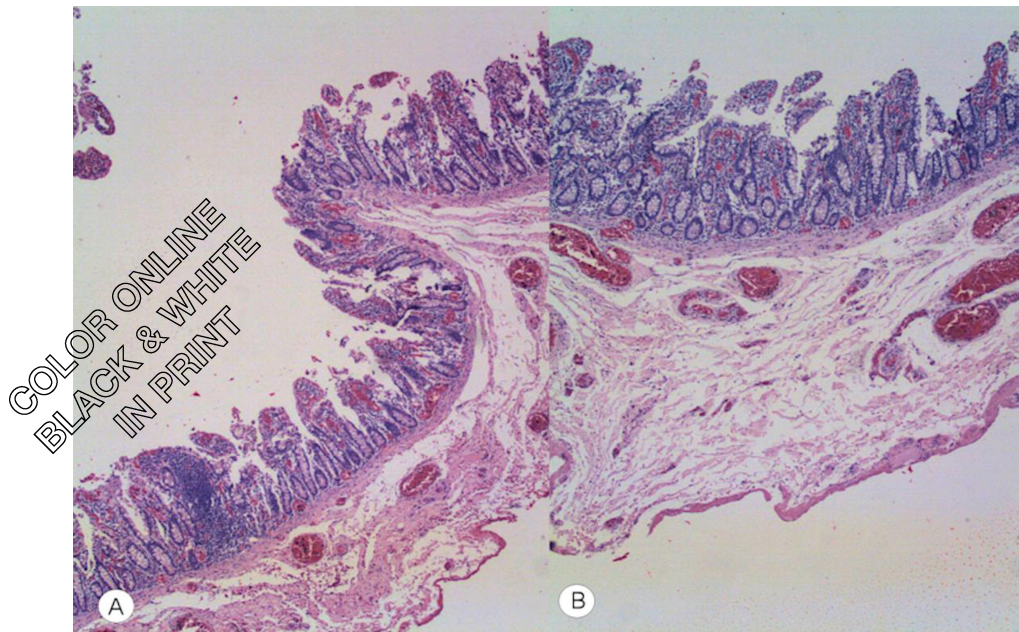


Figure 2. Absence of the muscular wall (A, 40 \times magnification and B, 100 \times magnification).

After surgery, the patient suffered intra-abdominal abscess and septic shock, which were treated with parenteral nutrition and antibiotics. After discharge, the family was recommended to seek a specialized service of pediatric gastroenterology.

At admission, the patient presented with severe malnutrition. He weighed 16.3 Kg with a Z score of -5.64 for height and of -2.45 for age. The patient had a history of birth by vaginal delivery at 2800 g (full term) without intercurrents. Tests for *Giardia* in feces and *Mycobacterium* spp. in gastric aspirate were negative. Chloride sweat was normal. Thyroid function was normal. Imaging tests (computed tomography and ultrasonography) 2 months after surgery showed diffuse thickening of small bowel loops. Ultrasonography showed also mild ascites. A new duodenal biopsy showed no signs of celiac disease. Five months after surgery, the patient still shows severe malnutrition and has developed recurrent episodes of respiratory tract infections.

DISCUSSION

Most reported cases of SAIM involve short affected segments. It has been stated that affected segments may be nearly normal at visual/gross inspection or may look like a small herniation of the intestinal wall. In such cases, the most obvious consequence is the risk of perforation[1, 3]. In some of the literature, some speculate that SAIM may be a common condition that is not recognized. One argument favoring this hypothesis is the observation that spontaneous intestinal perforation, which is characterized by localized perforation without clinical and histologic features of necrotizing enterocolitis, is often associated with thinning muscularis propria[5].

In this present case, however, the total extent of the lesion was larger than in previous reports, and the age of presentation was considerably higher than expected. Rather than a herniation, SAIM presented as a stenotic segment, which most likely caused intestinal obstruction due to segmental atony of the ileum.

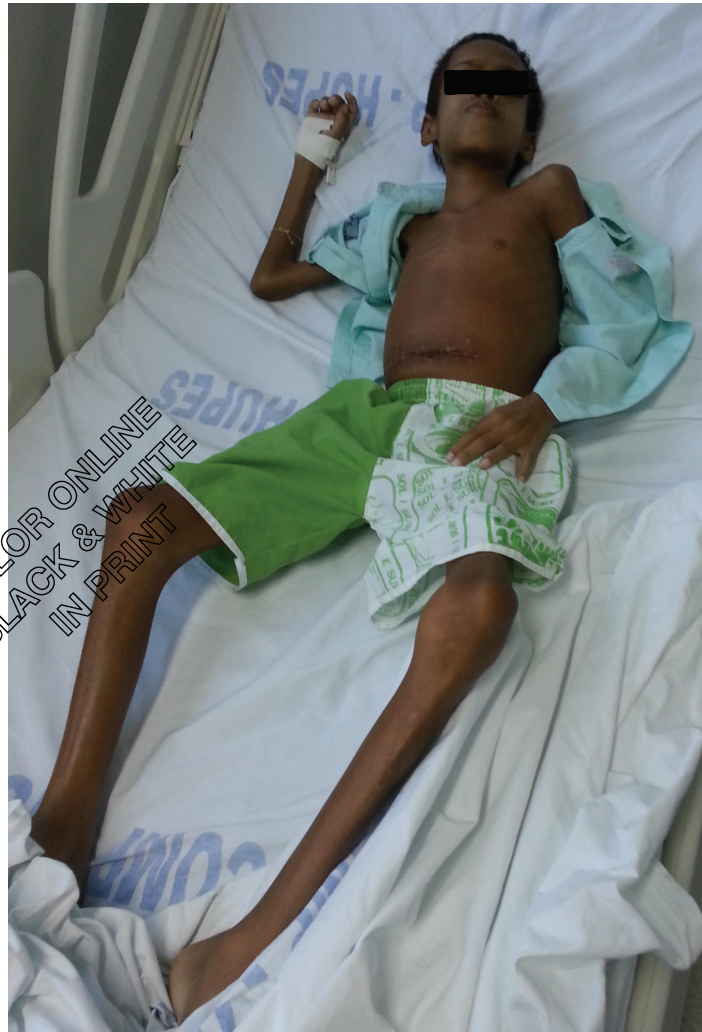

Figure 3. Five months after surgery, the patient shows severe malnutrition.

While well described in neonates, presentation of SAIM in older children and adults is exceptionally rare. To the best of our knowledge, there are three reports of SAIM in adults in the literature. Two reports were of a 34-year-old male and a 64-year-old female presenting as recurrent bowel obstruction and perendoscopic perforation, respectively[6, 7]. The former case is similar to the case reported here with regard to the extent of the SAIM segment (11 cm long in mid-jejunum) and the association with obstructive symptoms[6]. The third report was somewhat different in presentation, with multiple large diverticula in the jejunum as an incidental finding at surgery in a middle-aged male patient[8].

In conclusion, SAIM is a rare but well-described cause of bowel obstruction and perforation. It typically presents as small defects of the bowel wall in neonates and is usually associated with prematurity. It has also been reported in adults as an incidental finding or associated with perforation/obstruction. In the present case, an older child (10-year old) presented with severe malnutrition, a previous history of bowel obstruction and pathologic features of organizing peritonitis. The bowel defect was also the

largest described to date, indicating the potential effects of an atonic segment leading to obstructive disease.

Declaration of Interest

The authors report no conflicts of interest. The authors alone are responsible for the content and writing of the article. 100
AQ5

REFERENCES

- [1] [Davis JS, Ryan ML, Shields JM, et al. Segmental absence of intestinal musculature: an increasingly reported pathology. *J Pediatr Surg* 2012;7:566-1571.](#)
- [2] [Moore SW, Schneider JW, Kaschula RO. Unusual variations of gastrointestinal smooth muscle abnormalities associated with chronic intestinal pseudo-obstruction. *Pediatric Surgery International* 2002;8:3-20.](#) 105
- [3] [McCarthy DW, Qualman S, Besner GE. Absent intestinal musculature: anatomic evidence of an embryonic origin of the lesion. *J Pediatr Surg* 1994;9:476-1478.](#)
- [4] [Huang SF, Vacanti J, Kozakewich H. Segmental defect of the intestinal musculature of a newborn: evidence of acquired pathogenesis. *J Pediatr Surg* 1996;1:21-725.](#) 110
- [5] [Pumberger W, Mayr M, Kohlhauser C, Weninger M. Spontaneous localized intestinal perforation in very-low-birth-weight infants: a distinct clinical entity different from necrotizing enterocolitis. *J Am Coll Surg* 2002;95:96-803.](#)
- [6] [Tawfik O, Newell B, Lee KR. Segmental absence of intestinal musculature in an adult. *Dig Dis Sci* 1998;3:97-399.](#) 115
- [7] [Darcha C, Orliaguet T, Levrel O, et al. \[Segmental absence of colonic muscularis propria. Report of a case in an adult\]. *Annales de Pathologie* 1997;7:1-33.](#)
- [8] [Aldalati O, Phelan C, Ibrahim H. Segmental absence of intestinal musculature \(SAIM\): a case report in an adult. *BMJ Case Rep* 2009;009.](#) AQ6
120