

# The influence of the strain of *Trypanosoma cruzi* in placental infections in mice

SONIA G. ANDRADE\*

*Dept. of Pathology, Faculty of Medicine, Federal University of Bahia, Brazil*

## Summary

Pregnant female mice were infected with *Trypanosoma cruzi* strains which differed according to several parameters and were classified as three different types. Mice were killed during either the acute or the chronic phase of infection. Animals' tissues and foetuses together with the placentas, were studied histopathologically. Clear cut differences were noted in the incidence of placental parasitism and in the localization of amastigotes in the vascular sinus of the placenta amongst the animals in the acute phase of the infection with different strains. No parasitism of the foetal tissues was seen. The incidence of placental parasitism reached 98% for the *Colombian* strain, 18.4% for the *Peruvian* strain, 17% for the Y strain and 13.2% for the *Honorina* strain (isolated from a woman that transmitted the infection to twins). The presence of parasites in the vascular part of the placenta was prominent with the *Colombian* strain and rare with the others. These experimental data seem to show that parasite strain plays a role in congenital *T. cruzi* infection.

## Introduction

Congenital transmission of Chagas's disease has been detected in both man (DAO, 1949; HOWARD *et al.*, 1957; LISBOA, 1960) and experimental animals (NATTAN-LARRIER, 1921; CAMPOS, 1929). However, the epidemiological significance of such a mechanism of transmission has not been established. In some series, the percentage of proven cases of congenital *T. cruzi* transmission is relatively high (LISBOA, 1960; BITTENCOURT, 1967; BITTENCOURT & BARBOSA, 1972a, b) as may be seen in patients from the endemic area of Bahia, Brazil. In other series from different geographical areas, transplacental transmission of *T. cruzi* is claimed to be rare or absent (BARCELOS, 1960; LOPES *et al.*, 1967). It is not known if these results reflect differences in methodology, parasite strain or some other factor.

In this attempt to evaluate the potential role of parasite strain in congenital transmission of *T. cruzi* infection, placental infections of mice inoculated with different strains of *T. cruzi* were studied and compared. The strains used had been previously characterized as belonging to one of three different types referred to as Type I, Type II and Type III, taking into account the standard criteria for virulence and pathogenicity, evolution of parasitaemia, tissue tropism in infected mice, morphology of the parasite in the peripheral blood and the histopathological lesions (ANDRADE, 1974, 1976).

## Material and Methods

Outbred white Swiss female mice, weighing 18 to 20 g, were infected with three different strains of *T. cruzi* and studied during pregnancy, in both the acute and chronic phase of infection.

### Strains of *T. cruzi*

Type I—Y and *Peruvian* strains (SILVA & NUSSENZWEIG, 1953; NUSSENZWEIG & GOBLE, 1966); Type II—*Honorina* strain, isolated from a woman who had transmitted the infection to twins (HOFF *et al.*, 1978); Type III—*Colombian* strain (FEDERICI *et al.*, 1964).

Briefly, Type I strains are characterized by a rapid course of the infection in mice, high levels of parasitaemia and mortality around the 9th and 10th day of infection, predominance of slender blood forms and reticulotropism during the acute phase of the infection. Type II strains show a parasitaemia that

Work sponsored by grants from the Conselho Nacional de Desenvolvimento Científico e Tecnológico (CNPq)-Brazil (PDE 01-1-11).

\*Present address: Centro de Pesquisas Gonçalo Moniz, Rua Valdemar Falcão, 121—Brotas 4000—Salvador, Bahia, Brazil.

Table I—Experimental study of placental infection with *T. cruzi* in mice (acute phase)

Strains (Types)	Number of Females	Inoculum (No. TRY/0.2 ml)	Day of Infection	Number of Placentas and Foetuses	Presence of Amastigotes Placentas	Presence of Amastigotes Foetuses
I—Y <i>Peruvian</i>	7	144.470	7 to 9	28	5/28 (17.0%)	Neg.
	5	463.420	7 to 9	38	7/38 (18.4%)	Neg.
II— <i>Honorina</i>	9	72.500 (3)	10 to 21	68	9/68 (13.2%)	Neg.
		180.000 (2)				
		500.000 (4)				
III— <i>Colombian</i>	8	472.820	21 to 23	52	51/52 (98.0%)	Neg.

Table II—Experimental study of placental infection with *T. cruzi* in mice (chronic phase)

Strain (Types)	Number of Females	Inoculum (No. TRYP/0.2 ml)	Day of Infection	Number of Placentas and Foetuses	Presence of Amastigotes in Placentas & Foetuses
I— <i>Peruvian</i>	6	157.480	57 to 70	22	Neg.
II— <i>Honorina</i>	3	72.000 (1)	35 to 40	17	Neg.
		180.000 (1)			
		500.000 (1)			
III— <i>Colombian</i>	13	206.460 (9)	63 to 132	24	Neg.
		472.820 (4)			

increases from the 12th to the 20th day of infection, a slow rate of mortality, a predominance of broad forms of the parasites and myocardial tropism. Type III strains present a slow course of parasitaemia that reaches high levels 20 to 30 days after inoculation, with a low mortality and predominance of parasitism of the skeletal muscles.

#### Study of congenital transmission in the acute phase

With the *Y* and *Peruvian* (Type I) strains, in which the infection takes a very rapid course, and with the Type II strain (*Honorina*), females were mated and infected in an early phase of gestation which was detected by measuring the abdominal circumference and body-weight daily. Inoculation was subcutaneous with blood forms of *T. cruzi* obtained from infected mice. Female mice infected with the Type I strains were killed from the seventh to the ninth day of infection. The animals infected with the Type II strain (*Honorina*) were killed after 10 days of infection (four animals which received the highest inoculum—Table I) or after 21 days of infection (five animals which received medium or low inocula—Table I). With the Type III strain (*Colombian*), in which the course of the infection is slower, the animals were infected subcutaneously and then mated. They were killed 21 to 23 days later.

Data related to the inoculum size, number of foetuses and placentas appear in Table I. Parasitaemia levels of infected animals were followed daily.

#### Study in the chronic phase of infection

To obtain the chronic phase of infection in animals infected with the *Y* and *Peruvian* strains, a drug which suppressed parasitaemia\* (ANDRADE *et al.*, 1972) was administered from the 3rd to 12th days after inoculation.

Animals infected with the Type II and III strains progressed spontaneously to the chronic phase.

Animals were killed in advanced pregnancy (20 to 25 days after mating). Data on inoculum size and duration of the infection are shown in Table II.

Parasitaemia was recorded daily and in those animals without an apparent parasitaemia infection was later confirmed by inoculation of the blood into suckling mice.

For histopathological study, animals killed during pregnancy and the foetuses and placentas, were fixed

in 10% formalin. Foetuses were measured after fixation and varied in size from 0.5 to 0.7 cm (early phase of pregnancy) to 1.5 to 2.0 cm (advanced phase) in the several groups. The entire foetus together with the respective placenta was embedded in paraffin and sagittally sectioned. The 5 $\mu$  sections from the maternal and foetal tissues were stained with haematoxylin and eosin.

## Results

#### Acute infection

The course of parasitaemia in the infected females varied according to the strain as (see Fig. 1), which shows the parasitaemia levels in animals inoculated with the highest inocula for each strain. The incidence of placental parasitism varied with the strain, regardless of the size of the inoculum (Table I).

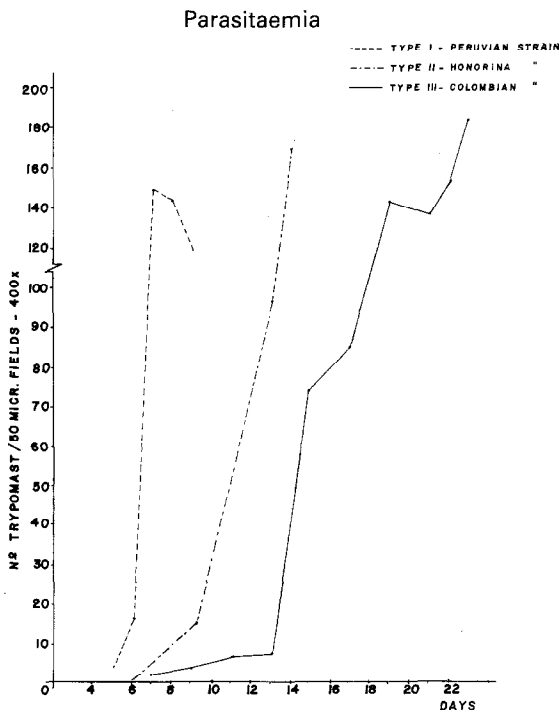


Fig. 1. Curves of parasitaemia in pregnant mice infected with different strains of *T. cruzi* and killed during the acute phase. Inocula: *Peruvian* strain—463,420 (trypomastigotes/0.2 ml); *Honorina* strain—500,000; *Colombian* strain—472,820.

\*CL 71, 366 (Cyanamid International)

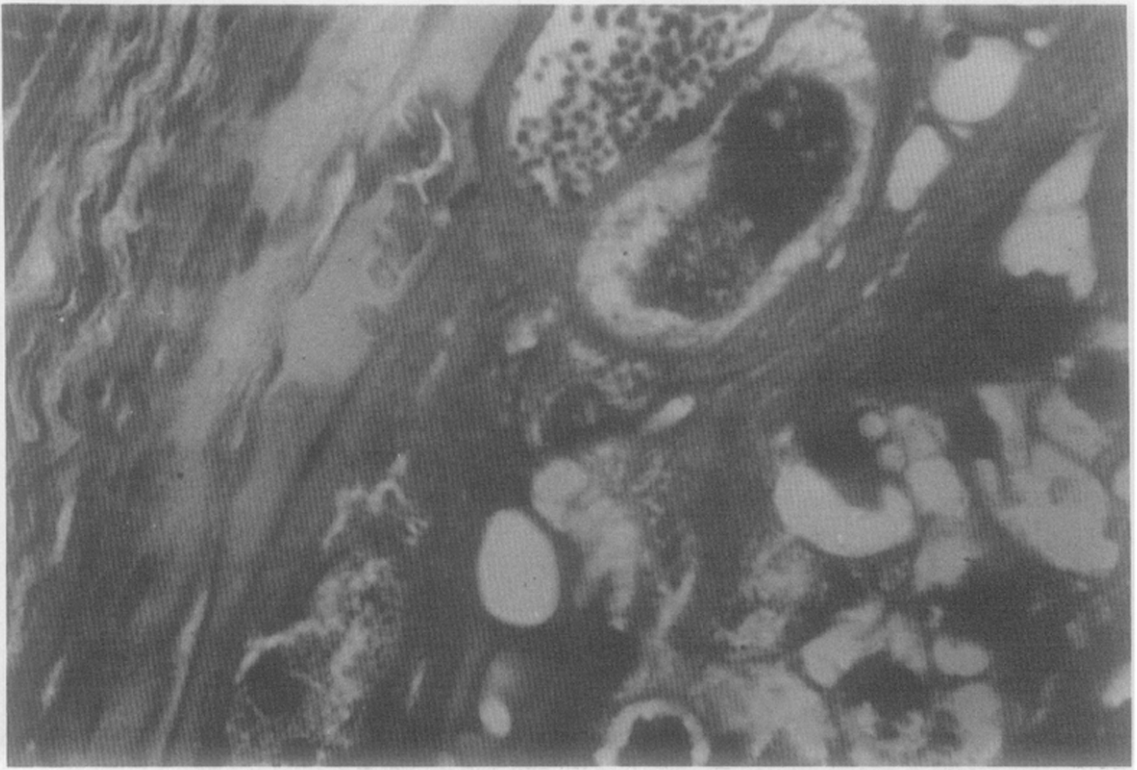


Fig. 2. Megakaryocytes in the basal part of the placenta of infected mouse, showing amastigote forms of *T. cruzi* in the cytoplasm and nuclear and cytoplasmic alterations. *Colombian* strain. H & E  $\times$  276.

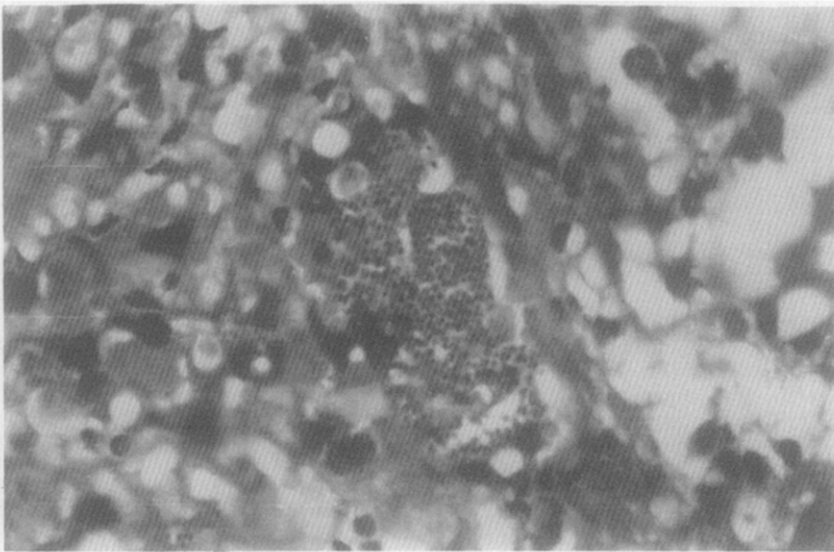


Fig. 3. Vascular portion of the placenta of infected mouse, showing amastigotes of *T. cruzi* within the blood sinus. *Colombian* strain. H & E  $\times$  400.

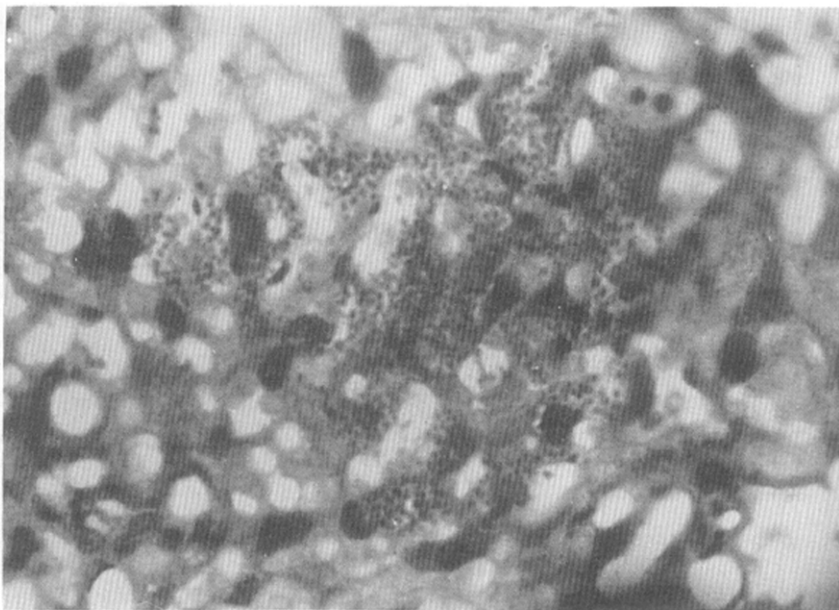


Fig. 4. *T. cruzi* amastigotes in the cytoplasm of endothelial cells lining blood sinus wall. Colombian strain. H & E  $\times$  400.

The degree of parasitism was also different. With the *Y* and *Peruvian* strains (Type I), placental parasitism was scanty, some amastigotes being found in the cytoplasm of megakaryocytes localized in the basal portion of the placenta and rarely in the vascular part. No parasites were found in foetal tissues. Parasitism of maternal tissues was intense and amastigotes were found principally inside macrophages in the liver and spleen, with a few localized within the uterine muscle and decidual cells. With the *Honorina* strain (Type II), placental parasitism was as with Type I. Maternal tissues displayed mild myocarditis and myositis with a few parasites in the heart, skeletal muscle, uterine wall and decidual cells. In the animals infected with the *Colombian* strain (Type III) parasitism of megakaryocytes (Fig. 2) was more frequent than with the other strains and many amastigotes were seen in the vascular part of the placenta, in the cytoplasm of endothelial cells or filling the vascular sinus (Figs. 3 and 4). As with the other groups, no parasites were seen in the foetuses. Maternal tissues showed moderate myocarditis and myositis with amastigotes in the myocardium, skeletal muscle, uterine wall and decidual cells.

#### Chronic infection

In the animals with induced chronic infection (57 to 83 days) due to the *Peruvian* strain (Type I), there was focal mononuclear infiltration in the myocardium and skeletal muscle and a few amastigotes were seen in these tissues. These findings were similar to those obtained for animals with chronic infection due to Type II *Honorina* strain (35 to 40 days). In animals chronically infected with Type III *Colombian* strain (63 to 132 days) the same lesions were seen, but these were more severe. No parasites were seen in the placenta or in the foetal tissues, regardless of the

strain (Table II). The course of parasitaemia before the chronic phase of infection is shown in Fig. 5. At the time of mating, the animals infected with each strain showed either very low levels of parasitaemia, or were negative on direct peripheral blood examination.

#### Discussion

The murine placenta is of the haemochorial type in the early stage of gestation and changes to haemendothelial later, so there is a close relationship between maternal and foetal blood in the labyrinthine vascular portion of the placenta (AMOROSO, 1956). Only a thin membrane of foetal endothelium separates the two circulations. The presence of parasites in the vascular part of the placenta is suggestive of foetal infection.

Some authors (BITTENCOURT, 1967; APT & DIAZ, 1965), consider that the presence of parasites in the villous stroma of the placenta is evidence of transmission. However, in the present investigation placental infection was not accompanied by detectable congenital transmission.

In the present paper, not only the incidence of placental parasitism but its intensity and the involvement of the vascular part of the placenta were considered. Involvement of the foetal part of the placenta occurred especially in giant cells (megakaryocytes) which are of trophoblastic origin (MULNARD, 1967). Clear cut differences in placental parasitism were seen in the acute phase of the infection in mice experimentally infected with different strains of *T. cruzi*. Parasitism of the vascular part of the placenta was rare and scanty in the animals infected with the strains of Types I and II (*Y*, *Peruvian* and *Honorina*) and was intense and frequent in those infected with the *Colombian* strain (Type III). In the infection with

## Parasitaemia

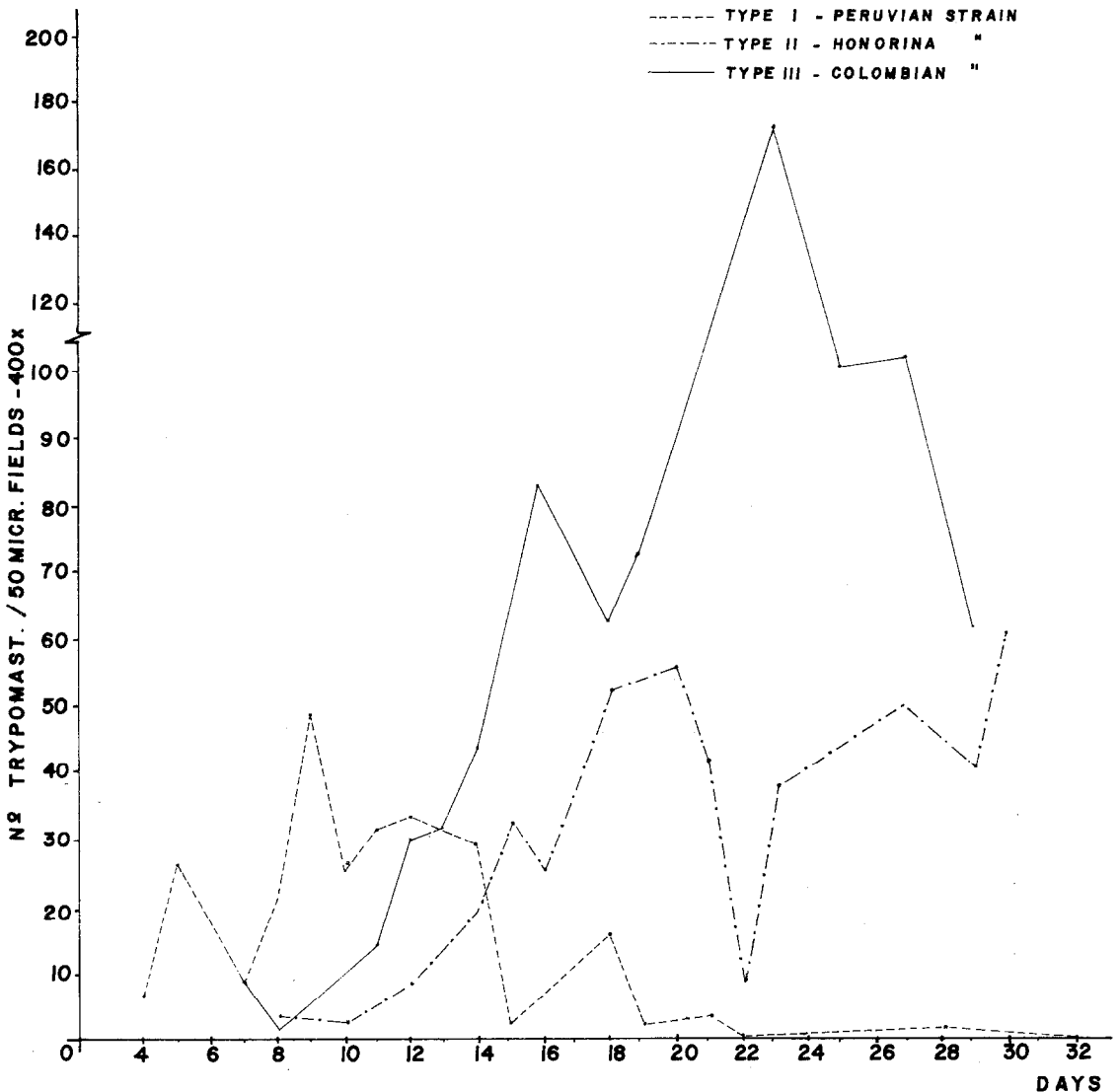


Fig. 5. Curves of parasitaemia in pregnant mice killed in the chronic phase of infection with different strains of *T. cruzi*. Inocula: Peruvian strain—157,480 trypomastigotes/0.2 ml (animals treated with a suppressive drug) Honorina strain—180,000; Colombian strain—206,460.

Type III strain, the labyrinthic vascular part of the placenta was most frequently parasitized, in contrast to the other strains. The duration of acute infection was different for the different strains and this factor may be of importance in determining placental infection; this possibility cannot be excluded at present. However, the chance of placental infection seems more probable during the highest peaks of parasitaemia. To test this hypothesis, animals infected with different strains were killed in the phase of the highest parasitaemia. Under such conditions, different *T. cruzi* strains infected the placental tissues differently. It is important to note that during the chronic phase of the infection, when parasitaemia was

at a low level, no parasitism of the placenta was observed with any of the strains studied.

The experimental data obtained in this study suggest that parasite strain may be one important factor in the congenital transmission of *T. cruzi* infection.

#### Acknowledgements

I wish to thank Dr. Rodney Hoff for making available to me the Honorina strain of *T. cruzi* and Dr. Mariela Vargas S. Cruz for her technical help.

#### References

Amoroso, E. C. (1956). Placentation. In: Marshall's

- Physiology of Reproduction*. Parkers, A. S. (Editor). Vol. II. London: Longmans, Green & Co., pp. 127-311.
- Andrade, S. G. (1974). Caracterização de cepas do *Trypanosoma cruzi* isoladas do Recôncavo Baiano. *Revista de Patologia Tropical*, 3, 65-121.
- Andrade, S. G. (1976). Tentative of grouping different *Trypanosoma cruzi* strains in some types. *Revista do Instituto de Medicina tropical de São Paulo*, 18, 140.
- Andrade, S. G., Figueira, R. M. & Carvalho, M. L. (1972). Tratamento da doença de Chagas experimental. (Estudos com a droga CL 71, 366). *Revista do Instituto de Medicina tropical de São Paulo*, 14, 135-145.
- Apt, W. & Diaz, M. (1965). Hallazgo de *Trypanosoma cruzi* en estroma de las vellosidades coriales de ratones. *Boletim Chileno de Parasitologia*, 20, 52-53.
- Barcelos, J. M. (1960). *Contribuição à patogenia da doença de Chagas congênita*. Thesis. Rio de Janeiro, Brazil.
- Bittencourt, A. L. (1967). Transmissão congênita da doença de Chagas. *Gazeta Médica da Bahia*, 67, 39-64.
- Bittencourt, A. L. & Barbosa, H. S. (1972a). A importância do estudo do feto macerado para o diagnóstico da forma congênita da doença de Chagas. *Revista do Instituto de Medicina tropical de São Paulo*, 14, 260-263.
- Bittencourt, A. L. & Barbosa, H. S. (1972b). Incidência de transmissão congênita de doença de Chagas em abortos. *Revista do Instituto de Medicina tropical de São Paulo*, 14, 257-259.
- Campos, E. M. (1929). Transmissão intrauterina do *Trypanosoma cruzi* na infecção experimental do cão. *Anais da Faculdade de Medicina da Universidade de São Paulo*, 3, 35-39.
- Dao, L. (1949). Otros casos de enfermedad en el Estado Guarico (Venezuela): formas agudas y cronicas; observaciones sobre la enfermedad de Chagas congenita. *Revista Policlinica*, 17, 17-32.
- Federici, E. E., Abelman, W. B. & Neva, F. A. (1964). Chronic progressive myocarditis and myositis in C3H mice infected with *Trypanosoma cruzi*. *American Journal of Tropical Medicine and Hygiene*, 13, 272-280.
- Hoff, R., Mott, K., Milanesi, M. L., Bittencourt, A. L. & Barbosa, H. S. (1978). Congenital Chagas's disease in an urban population: investigation of infected twins. *Transactions of the Royal Society of Tropical Medicine and Hygiene*, 27, 247-250.
- Howard, J. E., Rio, C., Ebensperger, I. & Olivos, P. (1957). Enfermedad de Chagas congenita. *Boletim Chileno de Parasitologia*, 12, 42-45.
- Lisboa, A. C. (1960). Sobre a forma congênita da doença de Chagas. Estudo anatomo-patológico de 6 casos. *Revista do Instituto de Medicina tropical de São Paulo*, 2, 319-334.
- Lopes, E. R., Chapadeiro, E., Oliveira, F. C., Alonso, M. T., Pereira, F. E., Almeida, H. O. & Hial, W. (1967). Doença de Chagas e gravidez. V. Estudo de 50 placentas de gestantes chagásicas crônicas. *Revista do Instituto de Medicina tropical de São Paulo*, 9, 393-396.
- Mulnard, J. G. (1967). Les propriétés phagocytaires du trophoblaste au cours des premières phases de l'ovo-implantation chez la souris. *Archives de Biologie*, (Liège), 78, 575-594.
- Nattan-Larrier, H. (1921). Hérité des infections expérimentales à *Schizotrypanum cruzi*. *Bulletin de la Société de Pathologie Exotique*, 14, 232-238.
- Nussenzweig, V. & Goble, F. (1966). Further studies on the antigenic constitution of strains of *Trypanosoma (Schizotrypanum) cruzi*. *Experimental Parasitology*, 18, 224-230.
- Silva, L. H. P. & Nussenzweig, V. (1953). Sobre uma cepa do *T. cruzi* altamente virulenta para o camundongo. *Folia Clinica et Biologica*, 20, 191-208.

---

Accepted for publication 26th May, 1981.